

# Anesthesiologist's nightmare in the angio suite during Carotid Artery Stenting

---

Mladić-Batinica, Inga; Žaja, A; Hostić, Vedran; Kalousek, Vladimir; Čulo, Branimir

Source / Izvornik: **European Journal of Anaesthesiology, 2020, 37, 193 - 193**

**Journal article, Published version**

**Rad u časopisu, Objavljena verzija rada (izdavačev PDF)**

Permanent link / Trajna poveznica: <https://um.nsk.hr/um:nbn:hr:220:442026>

Rights / Prava: [In copyright](#)/[Zaštićeno autorskim pravom.](#)

Download date / Datum preuzimanja: **2024-11-23**



Repository / Repozitorij:

[Repository of the Sestre milosrdnice University Hospital Center - KBCSM Repository](#)

CT angiography were enrolled in the study. NIRS sensors were applied to the scalp directly over the ischemic area and over the contralateral temporal region. The rSO<sub>2</sub> values from the ischemic and non-ischemic hemisphere before and after EVT were compared. Data are summarized as median [IQR] and were analyzed with the Wilcoxon signed-rank test.

**Results and Discussion:** Data from 7 of 17 patients were excluded from further analysis because of either previously unknown bilateral ICA occlusion, an M2 or more distal occlusion, or recanalization by intravenous thrombolysis alone. Patient demographics, procedural characteristics and results are displayed in Table 1. The rSO<sub>2</sub> of the affected vs. non-affected hemisphere was 67% [65-73] vs. 67% [65-69] before, and 69% [67-74] vs. 67% [64-72] after EVT (Figure). This is the first study which measures oxygenation with NIRS directly over the ischemic area of interest. The possible reasons why we found no change in rSO<sub>2</sub> before and after EVT include: (a) contamination of the signal from extracranial tissue, (b) intracranial collaterals maintaining oxygenation, (c) impaired O<sub>2</sub> consumption in the ischemic brain.

**Conclusion:** Despite application of the NIRS sensor over the ischemic region, no change in rSO<sub>2</sub> was detected during successful reperfusion in patients with acute stroke due to a M1 and/or unilateral ICA occlusion.

Patient demographic, procedural characteristics and results			
Age (median, [IQR])	79 [65-81]		
Male - no./total no.	7/10		
Occlusion site (ICA/M1) - no.	ICA = 4, M1 = 10		
General anesthesia/conscious sedation/ local anesthesia - no.	4/0/6		
Intra-venous thrombolysis - no./total no.	4/10		
mTICI score - (2B/2C/3) - no.	3/3/4		
Time last seen well to recanalization (min. (median, IQR))	410 [372-520]		
PTA carotid artery - no./total no.	4/10		
	Pre-EVT (median, [IQR])	Post-EVT (median, [IQR])	p-value
rSO <sub>2</sub> affected hemisphere (%)	67 [65-72]	69 [67-73]	0.103
rSO <sub>2</sub> non-affected hemisphere (%)	67 [65-68]	67 [63-70]	0.916
MAP (mmHg)	106 [90-119]	101 [90-118]	0.374
SpO <sub>2</sub> (%)	98 [96-100]	99 [95-100]	0.779
EtCO <sub>2</sub> (kPa)	3.9 [3.7-4.2]	4.0 [3.8-4.2]	0.180
Minute ventilation (L)	6.8 [5.7-8.0]	6.7 [5.2-8.0]	0.180
Heart rate (bpm)	78 [65-93]	78 [57-92]	0.102
Propofol TCI C <sub>e</sub> (ug/ml)	3.8 [2.8-4.0]	3.6 [3.1-3.9]	0.655
Remifentanyl TCI C <sub>e</sub> (ng/ml)	4.0 [3.5-4.0]	4.0 [3.1-4.0]	0.180
Noradrenaline (ug/kg/min)	0.03 [0.02-0.06]	0.03 [0.02-0.04]	0.317

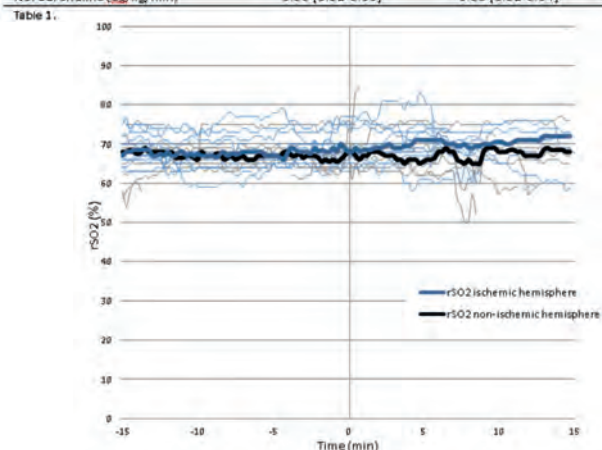


Figure. Line charts of the rSO<sub>2</sub>. The blue and black lines (bold = median) are the rSO<sub>2</sub> measurements of the ischemic hemisphere vs. the non-ischemic hemisphere respectively. Moment of definitive recanalization was set at 0 minutes for all patients.

4953

Anesthesiologist's nightmare in the angio suite during Carotid Artery Stenting

Mladic-Batinica I.<sup>1</sup>, Žaja A.<sup>1</sup>, Hostić V.<sup>1</sup>, Kalousek V.<sup>1</sup>, Čulo B.<sup>1</sup>  
<sup>1</sup>UHC Sestre Milosrdnice - Zagreb (Croatia)

**Background:** Endovascular neurointerventions is one of the most expanding clinical field during the past few decades. The complexity of conditions treated this way is increasing, creating challenges for neuroanesthesiologists. Carotid artery stenting (CAS) is regarded as a relatively safe, less invasive treatment of internal carotid artery (ICA) stenosis<sup>1</sup>. Still CAS in calcified arteries carries a higher perioperative risk: cerebral thromboembolic events are the most common complications, while rupture is rare, but generally fatal.

**Case Report:** We present a case of CAS in 76 yrs old femal with transient ischemic attack. Cerebral angiography revealed a concentric calcification with 90% lumen reduction of ICA. CAS started under local anesthesia. After patient had repeated neurologic deficit due to bad tolerance of balloon occlusion test, it was converted to general endotracheal anesthesia. During the intervention of right ICA iatrogenic rupture occurred. After stent implantation patient remained intubated, analgosedated

and on minimal vasoactive support. Urgent CT angiography revealed a normal flow through the right ICA without any great blood vessels occlusion; on cerebral CT no ischemic or hemorrhagic events. Patient was extubated without neurological deficit.

**Discussion:** Outcome after neurointerventional procedure is dependent on rapid diagnosis and early treatment of intraprocedural complications - the time factor! Severe artery stenosis can be indicative for decreased plaque stretch capability, with increased risk of dissection, rupture and residual stenosis. Some study shows that plaque's ability to undergo stretch is independent of the level of stenosis and strongly depends on the calcification's content. Anesthesiologist as a team member has a role in facilitating neuroradiological procedures, so an understanding of specific neuroradiological procedures, with potential complications, is crucial.

Reference:

1. Vitek J.J, et al: Carotid artery stenting: tehcnical considerations. AJNR Am J Neuroradiol 2000; 21:pp. 1736- 1743.

**Learning points:** In future we need parameters that should be more indicative for patient's interventional risk with the aim of safer classic endarterectomy. In the shadow of the procedure, an anesthesiologist's role is much more than fine drugs titration, accurate BP and respiratory function monitoring - a good plan in dealing with possible complications and close cooperation with neuroradiologist is essential for favourable outcome.

5543

Vascular air embolism in Neurosurgery – A case Report

Carp M.<sup>1</sup>, Rodrigues C.<sup>2</sup>, Antunes H.<sup>1</sup>

<sup>1</sup>Centro Hospitalar Lisboa Norte - Hospital Santa Maria - Lisbon (Portugal), <sup>2</sup>Centro Hospitalar Lisboa Norte - Hospital Santa Maria - Lisboa (Portugal)

**Background:** Vascular air embolism (VAE) is a feared complication of some invasive procedures, with relevance in neurosurgery. The true incidence of VAE is not known since many cases of VAE are subclinical. This is most often associated with sitting position craniotomies where the brain is in a higher position than the heart. Vascular air embolism may have cardiovascular, pulmonary, and neurologic sequelae that might be lethal. The detection of an ongoing episode is mainly a clinical diagnosis, taking into consideration the circumstances under which clinical alterations occur.

**Case report:** We report a case of a 71 yo male, ASA 3, proposed to suboccipital craniotomy. Twenty minutes after the beginning of the surgery we found an abrupt decrease of etCO<sub>2</sub> and SpO<sub>2</sub> (80%). We immediately informed the surgeon, lowered the headboard and institute high-flow 100% oxygen. Fluid therapy has been optimized, preserving hemodynamic stability. A arterial blood gas sample was collected and revealed hypoxemia (paO<sub>2</sub> 54,3mmHg) and hypercapnia (paCO<sub>2</sub> 52,4mmHg). There was a fast recover returning to the baseline clinical and laboratorial status. There was no hemodynamic repercussions or further complications until the end of the procedure. At this time a precordial Doppler was made and show small and insignificant air bubbles in the right atrium. We chose to wake up the patient that was uneventfully extubated and transferred to the intensive care unit.

**Discussion:** Early diagnosis and treatment before catastrophic cardiovascular collapse are of utmost importance. The principal goals of management include prevention of further air entry; a reduction in the volume of air entrapped and hemodynamic support. In this case the clinical suspicion was early recognized and the immediate actions were taken. Transesophageal echocardiography (TEE) is currently the most sensitive monitoring device for detection of air presence and The precordial Doppler (PE) is the most sensitive of the non-invasive monitors. We had no TEE available so PE was our possibility. Decision to transfer to intensive care unit was made for greater surveillance.

**Learning points:** The optimal management of VAE is prevention. Vascular air embolism is a potentially life-threatening event and clinicians must be aware of this silent but dangerous entity for an early suspicion.

References:

1. Marek A. Mirski, et al.; Diagnosis and Treatment of Vascular Air Embolism; Anesthesiology 1 2007, Vol.106, 164-177.