

Benign Multicystic Peritoneal Mesothelioma Mimicking Gynecologic Pathology

Alvir, Ilija; Bevanda, Boris; Danolić, Damir; Mamić, Ivica; Kostić, Lucija; Starčević-Božović, Angelina; Puljiz, Mario

Source / Izvornik: **Acta clinica Croatica, 2021, 60, 323 - 325**

Journal article, Published version

Rad u časopisu, Objavljena verzija rada (izdavačev PDF)

<https://doi.org/10.20471/acc.2021.60.02.22>

Permanent link / Trajna poveznica: <https://urn.nsk.hr/urn:nbn:hr:220:004344>

Rights / Prava: [Attribution-NonCommercial-NoDerivatives 4.0 International/Imenovanje-Nekomercijalno-Bez prerada 4.0 međunarodna](#)

Download date / Datum preuzimanja: **2024-12-22**



Repository / Repozitorij:

[Repository of the Sestre milosrdnice University Hospital Center - KBCSM Repository](#)



BENIGN MULTICYSTIC PERITONEAL MESOTHELIOMA MIMICKING GYNECOLOGIC PATHOLOGY

Ilija Alvir¹, Boris Bevanda¹, Damir Danolić¹, Ivica Mamić¹, Lucija Kostić¹,
Angelina Starčević-Božović² and Mario Puljiz¹

¹Department of Gynecologic Oncology, Sestre milosrdnice University Hospital Centre,
University Hospital for Tumors, Zagreb, Croatia;

²Department of Clinical Pathology, Sestre milosrdnice University Hospital Centre,
University Hospital for Tumors, Zagreb, Croatia

SUMMARY – Benign multicystic peritoneal mesothelioma is a rare pathology that arises from the abdominal peritoneum. It has an affinity to develop on the surfaces of pelvic viscera. It predominantly occurs in women of reproductive age. The most used form of treatment is complete surgical removal. We report a case of a 21-year-old female patient who presented with unclear diffuse abdominal pain. Transvaginal ultrasound and magnetic resonance imaging of the abdomen and pelvis revealed multiple functional cysts in the projection of the right and left ovary and free fluid in the pouch of Douglas. Laparoscopy was performed and multicystic tumor with thin, smooth walls, filled with clear serous content was found in lesser pelvis spreading to the left paracolic region and under the spleen. The multicystic mass was removed. Histologic examination revealed cystic formations filled with mucous content and formed from connective tissue outside and single row epithelium-mesothelium inside. Definitive diagnosis was benign multicystic mesothelioma of the abdominal peritoneum. The patient was well at one year follow-up.

Key words: *Benign multicystic peritoneal mesothelioma; Laparoscopy; Magnetic resonance imaging; Ultrasound*

Introduction

Benign cystic mesothelioma is a rare disease that develops in the abdominal or pelvic cavity, but also in the pleura, pericardium, tunica vaginalis and spermatic cord¹. Tumors mostly occur in the pleura. The second most frequent site is the peritoneum². Benign multicystic peritoneal mesothelioma (BMPM) is a rare pathology involving peritoneal serosa³. The incidence rates in industrialized countries range between 0.5 and three cases *per million* in men and between 0.2 and two cases *per million* in women². It is an uncommon

lesion arising from the peritoneal mesothelium. It is mostly diffuse and has an affinity to develop on the surfaces of pelvic viscera⁴. The etiology of BMPM is unknown and it predominantly occurs in women of reproductive age^{5,6}. Some consider it to be a reactive process secondary to previous surgical trauma or inflammation causing peritoneal inclusion cysts⁶. It is characterized by the formation of intra-abdominal multilocular cystic masses. Clinical presentation is nonspecific and most often it presents with unclear abdominal pain and presence of palpable masses in the abdomen. In other cases, it is accidentally discovered during routine diagnostic tests, general medical examinations or surgical procedures in the abdomen⁵. Differential diagnosis includes cystic lymphangioma, mucinous cystadenoma, cystic teratoma and pseudomyxoma peritonei. There are no evidence-based treatment strategies for benign cystic mesothelioma, al-

Correspondence to: *Boris Bevanda, MD*, Department of Gynecologic Oncology, Sestre milosrdnice University Hospital Centre, University Hospital for Tumors, Ilica 197, HR-10000 Zagreb, Croatia

E-mail: borisbevanda244@gmail.com

Received January 3, 2017, accepted October 6, 2017

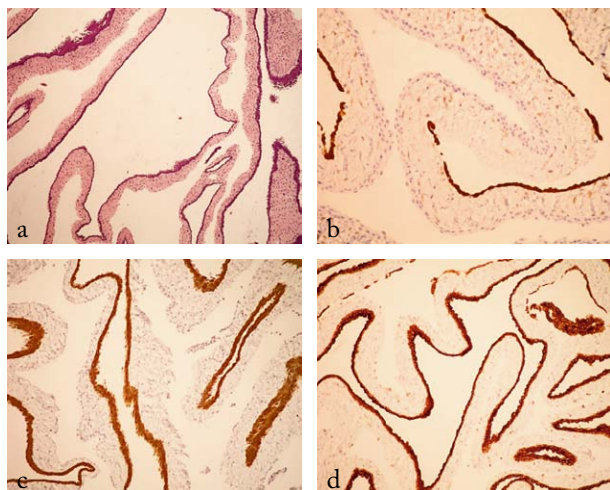


Fig. 1. Immunohistochemical staining positive for calretinin (a, b), cytokeratin 5/6 (c) and CA 125 (d).

though the most used form of treatment is complete surgical removal. Even though it is considered as a benign tumor, it has a high local recurrence rate^{5,7}.

Case Report

A 21-year-old female patient, with no serious illnesses prior to this, was admitted to our department with unclear diffuse abdominal pain. Transvaginal ultrasound (US) with color doppler and magnetic resonance imaging (MRI) of the abdomen and pelvis demonstrated multiple functional cysts in the projection of the right and left ovary, and free fluid inside the vesicouterine and rectouterine excavation. The right ovary measured 3.5x2.7 cm and left ovary 3.3x2.6 cm. Laparoscopy was performed and multicystic tumor with thin, smooth walls, filled with clear serous content was found in lesser pelvis spreading into the left paracolic region and under the spleen. The multicystic mass was removed.

Cytologic analysis of the cystic fluid content showed clusters of fibroblasts, histiocytes and eosinophils with no malignant cells found. Complete resection was performed. Histopathologic analysis showed cystic formations filled with mucous content and formed from connective tissue outside and single row epithelium-mesothelium inside. Immunohistochemical stains were positive for calretinin, CK5/6 and CA125 (Fig. 1 a-d). Definitive diagnosis was BMPM.

The patient presented for regular check-ups and was well, with no signs of recurrence at one-year follow-up.

Discussion

Benign multicystic peritoneal mesothelioma was first described in 1979 by Menemeyer and Smith^{4,8}. These tumors present as large multicystic masses with thin-walled septations and preference to the pelvic peritoneum, just like in our case. Typical symptoms include abdominal pain, distention and tenderness often associated with nausea and vomiting, and in some cases even ascites^{7,9}. Women are affected in 80% of cases, usually young to middle-aged women (mean age 37). Regarding the size, at the time of diagnosis, cysts have already grown^{4,7}. MRI is the method of choice for peritoneal mesotheliomas¹⁰. It has an advantage over computerized tomography or US because these two cannot distinguish benign cystic mesotheliomas from other cystic lesions. MRI is a method that can confirm the peritoneal origin, distinguish cystic content, or detect other lesions⁸. On the other hand, some suggest that laparoscopy is the best diagnostic tool because it enables better visualization of the lesion, local biopsy and establishing a definitive diagnosis. According to these researchers, imaging techniques, including MRI, cannot differentiate BMPM from other cystic lesions⁷. Differential diagnosis includes lymphangioma, pseudomyxoma peritonei, endometriosis, ovarian cystadenoma or cystadenocarcinoma, cystic teratomas, other omental-mesenteric cysts, etc. The most important differentiation is between BMPM and cystic lymphangioma, cystic adenomatoid tumor and malignant mesothelioma^{4,9,11}. Total surgical excision is the best form of treatment but the local recurrence rate is quite high, ranging from 33% to 50%^{4,11}. Chemotherapy and radiotherapy are ineffective in the case of BMPM. When it occurs in the pelvic region, especially in young women, surgeons must always have in mind how to preserve fertility during the operation¹¹. It has an excellent prognosis because only one death case has ever been reported in the literature^{4,11}.

Conclusion

This case draws attention to the importance of considering BMPM in differential diagnosis of multilocular cystic masses in the pelvis. Especially gynecologists, as well as pathologists should be aware of this possibility.

References

1. Shin HD, Kim SB. Benign cystic mesothelioma misdiagnosed as peritoneal carcinomatosis. *Case Rep Gastroenterol.* 2016 Jan-Apr;10(1):115-20. doi: 10.1159/000444445.
2. Boffetta P. Epidemiology of peritoneal mesothelioma: a review. *Ann Oncol.* 2007 Jun;18(6):985-90.
3. Occhionorelli S, Tartarini D, Pascale G, Maccatrozzo S, Stano R, Vasquez G. Benign multicystic mesothelioma of peritoneum complicating acute appendicitis in a man: a case report. *J Med Case Rep.* 2016 Feb 27;10:44. doi: 10.1186/s13256-016-0826-6.
4. Pitta X, Andreadis E, Ekonomou A, Papachristodoulou A, Tziouvaras C, Papapoulou L, *et al.* Benign multicystic peritoneal mesothelioma: a case report. *J Med Case Rep.* 2010 Nov 29;4:385. doi: 10.1186/1752-1947-4-385.
5. Garcia-Mayor Fernandez RL, Fernandez-Gonzalez M, Lopez-Rodriguez A, Martinez-Almeida Fernandez R. Recurrent benign multicystic peritoneal mesothelioma: approach to this rare condition. *Cir Cir.* 2016. Epub 2016 Jan 5. doi: 10.1016/j.circir.2015.08.013.
6. Tamhankar VA. Multicystic benign mesothelioma complicating pregnancy. *Case Rep Obstet Gynecol.* 2015;2015:687183. doi: 10.1155/2015/687183.
7. Elboughaddouti H, Bouassria A, Mouaqit O, Benjelloun el B, Ousadden A, Mazaz K, *et al.* Benign cystic mesothelioma of the peritoneum: a case report and literature review. *World J Emerg Surg.* 2013 Oct 13;8(1):43. doi: 10.1186/1749-7922-8-43.
8. Somasundaram S, Khajanchi M, Vaja T, Jajoo B, Dey AK. Benign multicystic peritoneal mesothelioma: a rare tumour of the abdomen. *Case Rep Surg.* 2015;2015:613148. doi: 10.1155/2015/613148.
9. Momeni M, Pereira E, Grigoryan G, Zakashansky K. Multicystic benign cystic mesothelioma presenting as a pelvic mass. *Case Rep Obstet Gynecol.* 2014;2014:852583. doi: 10.1155/2014/852583.
10. Gupta A, Rao HK, Pande R, Gupta S. A rare case of benign multicystic peritoneal mesothelioma: a clinical dilemma. *Indian J Surg.* 2013 Jun;75(Suppl 1):27-9. doi: 10.1007/s12262-011-0314-6.
11. Dzieńiecka M, Kaluzynski A. Benign multicystic peritoneal mesothelioma (BMPM) – case report and review of the literature. *Pol J Pathol.* 2011;62(2):122-4.

Sažetak

DOBROĆUDNI MULTICISTIČNI PERITONEJSKI MEZOTELIOM
S OPONAŠANJEM GINEKOLOŠKE PATOLOGIJE

I. Alvir, B. Bevanda, D. Danolić, I. Mamić, L. Kostić, A. Starčević-Božović i M. Puljiž

Dobročudni multicistični peritonejski mezoteliom je rijetka bolest koja nastaje iz abdominalnog peritoneja. Obično se razvija na zdjelici peritoneju, najčešće u žena generativne dobi. Najuobičajeniji način liječenja je potpuno kirurško uklanjanje. Prikazujemo slučaj 21-godišnje djevojke koja nam se javila s nejasnom difuznom boli. Transvaginalni ultrazvuk i magnetna rezonanca trbuha i zdjelice otkrili su višestruke funkcionalne ciste u projekciji desnog i lijevog jajnika i u Douglasovu prostoru. Učinjena je laparoskopija i nađen je multicistični tumor s tankim glatkim zidovima ispunjenim bistrom seroznom tekućinom u maloj zdjelici, koji se širio u lijevu parakoličnu regiju i ispod slezene. Multicistična masa je uklonjena. Patohistološka analiza je otkrila cistične formacije ispunjene sluzi i građene od vezivnog tkiva izvana i jednoređnim epitelmezotelom iznutra. Konačna dijagnoza je bila dobroćudni multicistični mezoteliom abdominalnog peritoneja. Bolesnica se redovito kontrolira bez znakova bolesti.

Ključne riječi: *Dobročudni multicistični peritonejski mezoteliom; Laparoskopija; Magnetna rezonanca; Ultrazvuk*