

# Primary malignant lymphoma of the uterine corpus: a case report

---

Alvir, Ilija; Bevanda, Boris; Danolić, Damir; Mamić, Ivica; Kostić, Lucija; Mandac Rogulj, Inga; Tomica, Darko; Radić-Krišto, Delfa; Milas, Ivan; Puljiz, Mario

Source / Izvornik: **Libri Oncologici : Croatian Journal of Oncology, 2017, 45, 94 - 97**

**Journal article, Published version**

**Rad u časopisu, Objavljena verzija rada (izdavačev PDF)**

Permanent link / Trajna poveznica: <https://um.nsk.hr/um:nbn:hr:220:787017>

Rights / Prava: [Attribution-NonCommercial-NoDerivatives 4.0 International/Imenovanje-Nekomercijalno-Bez prerada 4.0 međunarodna](#)

Download date / Datum preuzimanja: **2025-02-02**



Repository / Repozitorij:

[Repository of the Sestre milosrdnice University Hospital Center - KBCSM Repository](#)

## PRIMARY MALIGNANT LYMPHOMA OF THE UTERINE CORPUS: A CASE REPORT

ILIJA ALVIR<sup>1</sup>, BORIS BEVANDA<sup>1</sup>, DAMIR DANOLIĆ<sup>1</sup>, IVICA MAMIĆ<sup>1</sup>,  
LUCIJA KOSTIĆ<sup>1</sup>, INGA MANDAC ROGULJ<sup>2</sup>, DARKO TOMICA<sup>1</sup>, DELFA RADIĆ-KRIŠTO<sup>2</sup>,  
IVAN MILAS<sup>4</sup> and MARIO PULJIZ<sup>1</sup>

<sup>1</sup>Department of Gynecologic Oncology, University Hospital for Tumors,  
Sestre milosrdnice University Hospital Center, Zagreb, Croatia

<sup>2</sup>Department of Internal Medicine, Division of Hematology,  
Merkur University Hospital, Zagreb, Croatia

<sup>3</sup>Clinical Department of Gynecology, University Hospital for Tumors,  
Sestre milosrdnice University Hospital Center, Zagreb, Croatia

<sup>4</sup>Clinical Department of Surgery, University Hospital for Tumors,  
Sestre milosrdnice University Hospital Center, Zagreb, Croatia

---

### Summary

Primary malignant lymphoma of the genital tract is a rare disease. Its frequency has been reported to be less than 1% among extranodal lymphoma in women. The main symptoms are abnormal vaginal bleeding, unclear abdominal/pelvic pain, dyspareunia and/or urinary obstruction.

We present a 77-year old woman with a primary malignant lymphoma of the uterine corpus. Non-Hodgkin diffuse large B cell lymphoma was diagnosed in a curettage specimen. Positron emission tomography/ computed tomography (PET-CT) findings showed a lesion confined to the uterus without evidence of disease in the head, neck, chest or abdomen. There were no enlarged lymph nodes. The patient was treated by chemotherapy.

KEY WORDS: *non-Hodgkin lymphoma, uterine corpus, chemotherapy, ultrasound*

### PRIMARNI MALIGNI LIMFOM TIJELA MATERNICE: PRIKAZ SLUČAJA

#### Sažetak

Primarni maligni limfom genitalnog trakta je rijetka bolest. Učestalost je manja od 1% među limfomima izvan limfnih čvorova. Glavni simptomi su abnormalno vaginalno krvarenje, nejasna abdominalna/zdjeljučna bol, dispareunija i/ili urinarna opstrukcija.

Mi predstavljamo slučaj 77-godišnje pacijentice sa primarnim malignim limfomom tijela maternice. Non-Hodgkin difuzni velikostanični B limfom je dijagnosticiran u uzorku frakcionirane kiretaže. Imunohistokemijsko bojanje je potvrdilo dijagnozu. PET/CT je potvrdio bolest unutar maternice bez znakova bolesti u glavi, vratu, prsima ili trbuhu. Nije bilo uvećanih limfnih čvorova. Pacijentica je liječena kemoterapijom.

KLJUČNE RIJEČI: *non-Hodgkin-ov limfom, tijelo maternice, kemoterapija, ultrazvuk*

---

**INTRODUCTION**

Lymphomas are the most common haematological cancers and they are divided into two groups, non-Hodgkin (70-80%) and Hodgkin (20-30%) lymphomas (1).

Primary malignant lymphoma (PML) of the genital tract is a rare disease representing extranodal lymphomas with less than 1% (2,3).

The most common site where Non-Hodgkin's lymphomas (NHL) occur in genital tract is the ovary. Infrequently, NHL may also involve the uterus (4).

The most common diagnosis is diffuse large B-cell lymphoma. The main symptoms are abnormal vaginal bleeding, unclear abdominal/pelvic pain, dyspareunia and/or urinary obstruction (1,5). Most patients lack classical symptoms associated with B-cell lymphomas such as fever, fatigue, night sweats and weight loss (3). NHLs involving the uterus may be either low-stage neoplasms that probably arise in the uterus (primary) or systemic neoplasms with secondary involvement (4).

**CASE REPORT**

We present a 77-year old woman with a PML of the uterine corpus. She has been menopausal for 22 years. In her medical history, she had no

serious illnesses except undergoing surgery for ovarian cyst 40 years ago. She did not have any symptoms. During the control check up, she underwent pelvic ultrasound (US) that revealed a 3.2 x 3.4 cm inhomogeneous lesion located within the uterine cavity (resistance index /RI/ 0.38). Non-Hodgkin diffuse large B cell lymphoma was diagnosed in a curettage specimen (Figure 1-3.). Ultrasound also revealed a cystic lesion in the right ovary. Microscopically, each cell showed a large

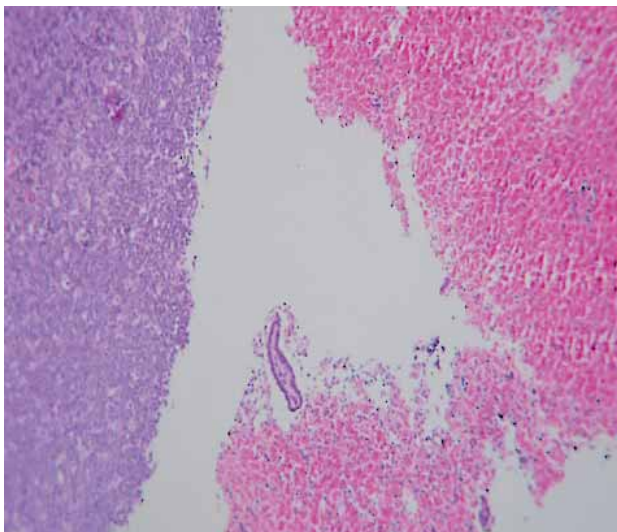


Figure 1. Histologic specimen showing diffuse large B cell lymphoma and endometrial tissue (hemalaun eosin staining, magnification 10x).

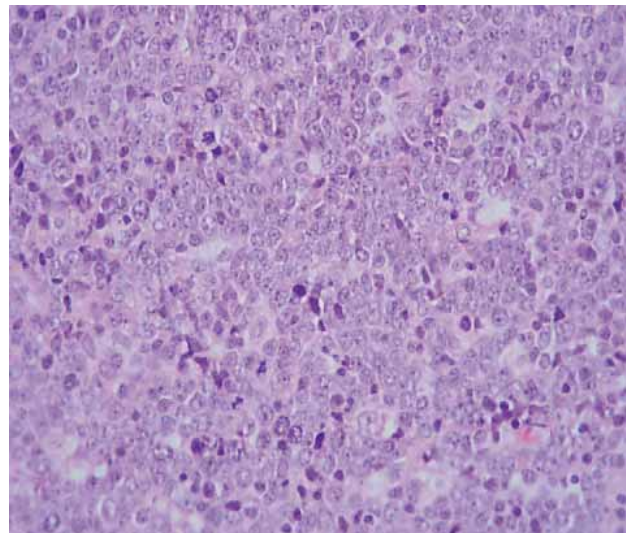


Figure 2. Histologic specimen showing diffuse large B cell lymphoma (hemalaun eosin staining, magnification 40x).

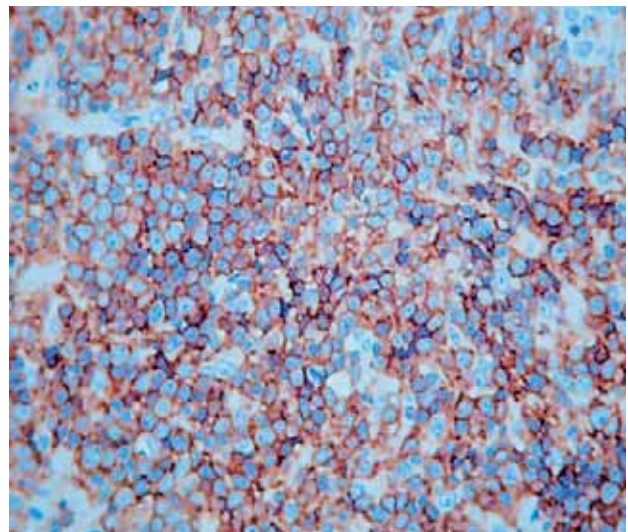


Figure 3. Immunohistochemical analysis revealed strongly positive staining with leukocyte common antigen (LCA) (magnification 40x).

or medium size bullous nucleus, the distinct nucleolus, frequent cell division, and a small amount of cytoplasm. Immunohistochemical staining confirmed the diagnosis. Positron emission tomography/computed tomography (PET/CT) findings showed a lesion confined to the uterus without evidence of disease in the head, neck, chest or abdomen. There were no enlarged lymph nodes. The patient was treated by chemotherapy. Treatment was started with series of rituximab, cyclophosphamide, doxorubicin, vincristine and prednisone (R-CHOP) chemotherapy under supervision of the hematology department. After 8 courses of chemotherapy, a control CT was performed which showed complete remission. Our patient had a relapse and multiple recurrences of lymphoma with progression and death three years after the initial diagnosis.

## DISCUSSION

Malignant lymphomas of the uterus can occur in patients of different ages, the median is the fourth decade (6). The incidence of extranodal lymphomas including MLs of the genital tract has increased in the past decades both in the United States and western Europe (7). Lymphomas presenting with initial manifestations of female genital tract disease are extremely rare (3). Patients usually present with vaginal bleeding and abdominal or pelvic discomfort, but also the tumors are discovered as a result of a routine check-up (2,3), as presented in our case. Because patients have often nonspecific symptoms, it usually takes longer before the correct diagnosis is made. The most common symptom of the primary uterine lymphomas is vaginal bleeding (2,5). Immunohistochemical examination is necessary to determine the type and subtype of lymphoma (2). Diffuse large B-cell lymphoma is the most frequent histological subtype and is responsible for 25% cases of NHL (7).

Computed tomography is the preferred imaging method because it can give information about the lesion size and extent of the disease. With the information given by CT we can plan treatment regimen and follow response to treatment (2). However, MRI has a greater ability to differentiate uterine and cervical lymphomas from other entities (5). Uterine lymphoma can

mimic cervical or endometrial carcinoma or myoma. They are presented on imaging studies from diffuse enlargements of the uterus to localized masses who are most commonly not sharply delineated (6).

Due to low incidence of primary uterine malignant lymphoma, large patient series describing the optimal treatment method are not available; therefore, the treatment of patients with a primary uterine lymphoma needs to be individualized (1,5). MLs affecting the female genital tract can be under diagnosed because they are unexpected in these sites and can be misdiagnosed as some other types of tumors (7). Patients with extranodal forms of malignant lymphomas are usually presented to and treated by specialists who deal with that particular body system (1). The prognosis for extranodal lymphomas, in general, is worse than for nodal primarily due to delayed or inaccurate diagnosis and inadequate treatment (7). R-CHOP protocol, the same we used with our patient, proved to improve 5-year survival rates significantly in patients over 60 years old and with the diagnosis of diffuse large B-cell lymphoma (5). This protocol has also been used in initial and recurrence treatment of aggressive NHLs and has improved overall survival for this disease (1).

## CONCLUSION

Primary uterine lymphoma of the genital tract is extremely rare. Although the gynaecologists will rarely deal with extranodal lymphomas they should include them in differential diagnosis of uterine pathology. Histology is essential to reach a correct diagnosis and appropriate treatment for this malignancy.

## REFERENCES

1. Anagnostopoulos A, Mouzakiti N, Ruthven S, Herod J, Kotsyfakis M. Primary cervical and uterine corpus lymphoma; a case report and literature review. *Int J Clin Exp Med.* 2013;6(4):298-306.
2. Chen R, Yu Z, Zhang H, Ding J, Chen B. Primary malignant lymphoma of the uterus and broad ligament: a case report and review of literature. *Onco Targets Ther.* 2015;8:265-8.
3. Vijayakumar S, Serur E, Bybordi B, Lakhi N. Primary gynecological non-Hodgkin's lymphoma: A differential diagnosis of a pelvic mass. *Gynecol Oncol Rep.* 2016 Nov; 18:29–31.

4. Vang R, Medeiros LJ, Ha CS, Deavers M. Non-Hodgkin's lymphomas involving the uterus: a clinicopathologic analysis of 26 cases. *Mod Pathol.* 2000;13(1):19-28.
5. Samama M, van Poelgeest M. Primary malignant lymphoma of the uterus: a case report and review of the literature. *Case Rep Oncol.* 2011 Sep;4(3):560-3.
6. Cheong IJ, Kim SH, Park CM. Primary Uterine Lymphoma: A Case Report. *Korean J Radiol.* 2000;1(4): 223–225.
7. Silva V, Correia P, Oliveira N, Sá L. Primary Vaginal Non-Hodgkin's Lymphoma: Report of a Rare Clinical Entity. *Clin Pract.* 2015 Nov 5;5(4):821.

*Corresponding author: Boris Bevanda, Department of Gynecologic Oncology, University Hospital for Tumors, Sestre milosrdnice University Hospital Center, Ilica 197, 10 000 Zagreb, Croatia. e-mail: borisbevanda244@gmail.com*