

Surgical and Seizure Treatment Outcomes in Adult Dysembryoplastic Neuroepithelial Tumors: a Case Series

Sajko, Tomislav; Rotim, Krešimir; Jurilj, Mia; Rotim, Ante; Splavski, Bruno; Jurčić Čulina, Ivana

Source / Izvornik: **Acta clinica Croatica, 2021, 60., 627 - 630**

Journal article, Published version

Rad u časopisu, Objavljena verzija rada (izdavačev PDF)

<https://doi.org/10.20471/acc.2021.60.04.09>

Permanent link / Trajna poveznica: <https://um.nsk.hr/um:nbn:hr:220:165758>

Rights / Prava: [Attribution-NonCommercial-NoDerivatives 4.0 International/Imenovanje-Nekomercijalno-Bez prerada 4.0 međunarodna](#)

Download date / Datum preuzimanja: **2024-11-23**



Repository / Repozitorij:

[Repository of the Sestre milosrdnice University Hospital Center - KBCSM Repository](#)



SURGICAL AND SEIZURE TREATMENT OUTCOMES IN ADULT DYSEMBRYOPLASTIC NEUROEPITHELIAL TUMORS: A CASE SERIES

Tomislav Sajko^{1,2,3}, Krešimir Rotim^{1,2,3}, Mia Jurilj^{1,3}, Ante Rotim^{1,3},
Bruno Splavski^{1,2,3,4} and Ivana Jurčić Čulina⁵

¹Department of Neurosurgery, Sestre milosrdnice University Hospital Center, Zagreb, Croatia;

²Josip Juraj Strossmayer University of Osijek, Faculty of Medicine, Osijek, Croatia;

³Department of Anatomy, University of Applied Health Sciences, Zagreb, Croatia;

⁴Josip Juraj Strossmayer University of Osijek, School of Dental Medicine and Health, Osijek, Croatia;

⁵University of Applied Health Sciences, Zagreb, Croatia

SUMMARY – Dysembryoplastic neuroepithelial tumors (DNETs) are benign neoplasms classified in the category of glioneuronal tumors. The estimated incidence of DNETs is 0.03 *per* 100,000 person *per* year with the age peak in a range between 10 and 14 years, and decreasing dramatically with increasing age. They are seldom diagnosed in persons above 20 years of age, being a cause of tumor-related intractable epilepsy that begins in childhood or adolescence. They have been proven to be the second most common type of epileptogenic tumors in pediatric population. These rare tumors cause chronic drug-resistant partial complex seizures with or without secondary generalization. Herein, we provide institutional case series of six adult patients with temporal lobe DNET presenting with complex partial seizures. Lesionectomy was performed with tumor resection *in toto* in three patients. In another three, partial resection was performed, whereas tumor remnant was left intact to avoid possible basal ganglia damage. All patients were seizure free postoperatively. Lesionectomy alone in temporal lobe epilepsy was associated with less favorable outcome than anterior temporal lobectomy. Total tumor removal is considered a major prognostic factor in most studies.

Key words: *Dysembryoplastic neuroepithelial tumor; Seizure; Surgery; Outcome*

Introduction

Dysembryoplastic neuroepithelial tumors (DNETs) are benign tumors first described by Daumas-Duport *et al.*¹. The World Health Organization (WHO) includes DNETs in the category of neuronal and mixed neuronal-glial tumors, corresponding to WHO grade 1². Four DNET histologic subtypes have been described³⁻⁶. They represent 1.2% of all neuroepithelial

tumors resected in patients under the age of 20 years⁷. In epilepsy surgery series, the prevalence of DNETs ranges from 0.8% to 19%⁸⁻¹⁰. DNETs are found in about 20% of histologic diagnoses in adult epilepsy surgery centers¹¹. The most common seizure type with DNETs is complex partial seizures with epileptogenic zone in the temporal lobe^{3,9,12}. Surgery is associated with very good prognosis and low recurrence risk⁸. Lesionectomy alone in temporal lobe epilepsy is associated with less favorable outcome than anterior temporal lobectomy.

Herein, we describe institutional series of six adult patients with such tumors presenting with complex partial seizures, and discuss postoperative surgical and seizure outcome.

Correspondence to: *Tomislav Sajko, MD, PhD*, Department of Neurosurgery, Sestre milosrdnice University Hospital Center, Vinsogradska c. 29, HR-10000 Zagreb, Croatia
E-mail: neurosajko@gmail.com

Received April 30, 2021, accepted September 21, 2021

Table 1. Patient characteristics

Case	Sex	Age (yrs)	Location of DNET	Seizure type	No. of AEDs	Seizure	Surgery
1	M	20	Left temporal	CP	1/0	SF	Lesionectomy
2	M	27	Left temporal	CP	1/1	SF	Lesionectomy
3	F	30	Left temporal	CP	2/1	SF	Lesionectomy
4	F	19	Right temporal	CP	1/0	SF	Lesionectomy
5	M	43	Left temporal	CP	2/2	SF	Lesionectomy
6	M	40	Right temporal	CP	2/2	SF	Lesionectomy

DNET = dysembryoplastic neuroepithelial tumor; AEDs = antiepileptic drugs; CP = complex partial; SF = seizure free

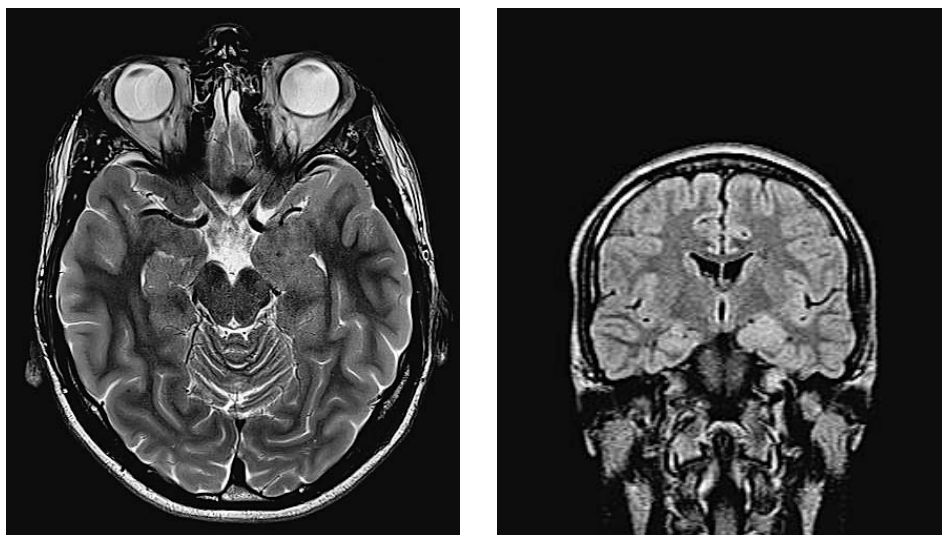


Fig. 1. Preoperative magnetic resonance imaging (MRI) of the brain (T2 axial weighted image): pathologic lesion in the region of the left-sided uncus and amygdala. Note the increased volume of the uncus and amygdala and absence of perilesional edema (A). Note the blurring and hyperintense signal of the left amygdala on coronal FLAIR axial MRI reformations (B).

Case Series

Six adult patients with DNETs admitted to Department of Neurosurgery, Sestre milosrdnice University Hospital Center during the 2012-2018 period were included. Patient characteristics are summarized in Table 1. All patients were right-handed and their mean age was 29.8 (range, 19 to 43) years. All patients underwent presurgical epileptogenic, neuroradiological and neurophysiological examination. All patients had complex partial seizures with a mean duration of 13.2 years. Four patients were on one antiepileptic drug (AED) and two patients on two AEDs prior to surgery. Preoperative neurophysiological examination

revealed normal results in four younger patients, but reduced verbal memory in two older patients.

Four patients had DNET in the left temporal lobe and two in the right temporal lobe. In all patients, DNET involved the uncus and amygdala without hippocampus involvement (Fig. 1A, B).

Surgery was performed and tumor resection *in toto* was achieved in three patients (Fig. 2). In another three patients, subtotal resection was performed in order to avoid basal ganglia damage. Postoperative period was uneventful, without complications.

Histopathologic examination showed complex DNET type in all six cases. Follow-up was 24 months.

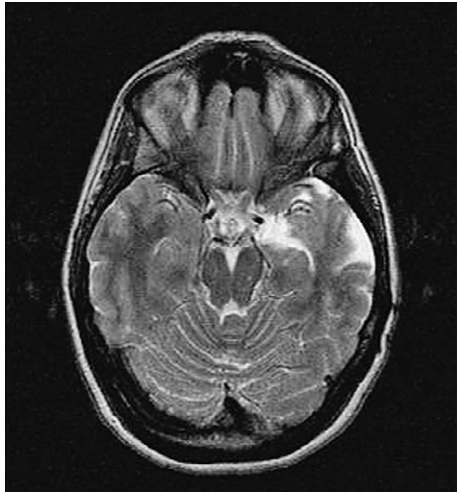


Fig. 2. Postoperative magnetic resonance imaging of the brain (T2 axial weighted image): resection area involving the left uncus and amygdala.

Postoperatively, all six patients were seizure-free, and AEDs were withdrawn in two youngest patients.

Discussion

Epilepsy onset in late childhood, complex partial seizures concordant with tumor location, and male predominance are characteristic of DNET^{13,14}. The typical magnetic resonance imaging (MRI) pattern consists of a pseudocystic or multicystic appearance, strongly hypointense on T1-weighted and hyperintense on T2-weighted images¹⁵. Tumor subtypes may be recognizable on MRI allowing simple and complex histologic forms to be differentiated from nonspecific forms¹⁴. In our case series, all six patients were type 1 according to MRI classification.

Surgical series report favorable outcomes in 70% to 90% of cases^{1,3,8,10-17}. Surgical methods consist of lesionectomy or corticectomy, including amygdalo-hippocampectomy and anterior temporal lobectomy. In our six-case series, we performed lesionectomy, including removal of the uncus and temporal ventricular part of amygdala that were involved by the tumor. We noticed that all lesions were sharply delineated from the hippocampus and could be dissected leaving the hippocampus intact. We found that important for patient postoperative neurophysiological functioning, although we did not perform postoperative neurophysiological examination.

Whether surgical outcome is related to the size of resection or type of the procedure remains controversial. Complete tumor removal is considered a major prognostic factor in most studies^{10,12,14,15,17}.

Incomplete resection is identified as the main cause of surgical failure¹². In our three patients, we did not resect the part of the lesion in the extra-ventricular portion of amygdala towards the basal ganglia in order not to damage basal ganglia. Nevertheless, all three patients were seizure-free postoperatively.

Surgical failure has also been attributed to the presence of dysplastic cortex adjacent to the tumor. Removing these areas has been considered necessary for a favorable outcome^{8,12}, but this has been contradicted by others^{10,16}. Lesionectomy alone in temporal lobe epilepsy has been associated with a less favorable outcome than anterior temporal lobectomy¹⁷. This may be explained by the network organization of the epileptogenic zone and hippocampal involvement in tumors with temporal location^{5,14}. Although we performed lesionectomy in all six patients, seizure outcome was favorable in all cases.

The second major prognostic factor has been related to young age at surgery and short epilepsy duration^{10,14,16,17}. In our series, median epilepsy duration was 13.2 years due to the fact that we had two adults aged 43 and 40 years with long epilepsy duration. In contrast, another four patients were younger and were seizure-free even after AED withdrawal. This is in accordance with the finding reported by Fay-McClymont *et al.* that successful AED discontinuation was also related to early surgery in young subjects¹⁸.

No tumor recurrence was noticed during the follow-up in our series, despite those three patients with tumor remnants. In their large series, Campos *et al.* found that recurrence was rare and occurred at the site of residual tumor¹⁵. These findings advocate performing complete tumor resection whenever possible.

In conclusion, DNETs are found in about 20% of the histologic diagnoses in adult epilepsy surgery centers. Complete tumor removal is considered a major prognostic factor. In our case series, all patients underwent lesionectomy leaving the hippocampus and parahippocampus intact with favorable seizure outcome achieved in all cases.

References

1. Daumas-Duport C, Scheithauer BW, Chodkiewicz JP, Laws Jr ER, Vedrenne C. Dysembryoplastic neuroepithelial tumor: a

- surgically curable tumor of young patients with intractable partial seizures. Report of thirty-nine cases. *Neurosurgery*. 1988;23:545-56. <https://doi.org/10.1227/00006123-198811000-00002>
2. Louis DN, Ohgaki H, Wiestler OD, Cavanee WB, Burger PC, Jouvet A, *et al.* The 2007 WHO classification of tumours of the central nervous system. *Acta Neuropathol*. 2007;114:97-109. <https://dx.doi.org/10.1007%2Fs00401-007-0243-4>
 3. Daumas-Duport C, Varlet P, Bacha S, Beuvon F, Cervera-Pierot P, Chodkiewicz JP. Dysembryoplastic neuroepithelial tumors: nonspecific histological forms – a study of 40 cases. *J Neurooncol*. 1999;41:267-80. <https://doi.org/10.1023/a:1006193018140>
 4. Daumas-Duport C. Dysembryoplastic neuroepithelial tumors. *Brain Pathol*. 1993;3:283-95. <https://doi.org/10.1111/j.1750-3639.1993.tb00755.x>
 5. Thom M, Toma A, An S, Martinian L, Hadjivassiliou G, Rattal B, *et al.* One hundred and one dysembryoplastic neuroepithelial tumors: an adult epilepsy series with immunohistochemical, molecular genetic, and clinical correlations and a review of the literature. *J Neuropathol Exp Neurol*. 2011;70:859-78. <https://doi.org/10.1097/nen.0b013e3182302475>
 6. Bodi I, Selway R, Bannister P, Doci L, Mullati N, Elwes, *et al.* Diffuse form of dysembryoplastic neuroepithelial tumour: the histological and immunohistochemical features of a distinct entity showing transition to dysembryoplastic neuroepithelial tumour and ganglioglioma. *Neuropathol Appl Neurobiol*. 2012;38:411-25. <https://doi.org/10.1111/j.1365-2990.2011.01225.x>
 7. O'Brien DF, Farrell M, Delanty N, Traunecker H, Perrin R, Smyth MD, *et al.* The children's cancer and leukaemia group guidelines for the diagnosis and management of dysembryoplastic neuroepithelial tumours. *Br J Neurosurg*. 2007;21:539-49. <https://doi.org/10.1080/02688690701594817>
 8. Chang EF, Christie C, Sullivan JE, Garcia PA, Tihan T, Gupta N, *et al.* Seizure control outcomes after resection of dysembryoplastic neuroepithelial tumor in 50 patients. *J Neurosurg Pediatr*. 2010;5:123-30. <https://doi.org/10.3171/2009.8.peds09368>
 9. Chan CH, Bittar RG, Davis GA, Kalnins RM, Fabinyi GC. Long-term seizure outcome following surgery for dysembryoplastic neuroepithelial tumor. *J Neurosurg*. 2006;104:62-9. <https://doi.org/10.3171/jns.2006.104.1.62>
 10. Nolan MA, Sakuta R, Chuang N, Otsubo H, Rutka JT, Snead OC III, *et al.* Dysembryoplastic neuroepithelial tumors in childhood: long-term outcome and prognostic features. *Neurology*. 2004;62:2270-6. <https://doi.org/10.1212/01.wnl.0000130495.69512.6f>
 11. Devaux B, Chassoux F, Guenot M, Haegelen C, Bartolomei F, Rougier A, *et al.* Epilepsy surgery in France: evaluation of activity. *Neurochirurgie*. 2008;54:453-65. <https://doi.org/10.1016/j.neuchi.2008.02.041>
 12. Bilginer B, Yalnizoglu D, Soylemezoglu F, Turanli G, Cila A, Topcu M, *et al.* Surgery for epilepsy in children with dysembryoplastic neuroepithelial tumor: clinical spectrum, seizure outcome, neuroradiology, and pathology. *Childs Nerv Syst*. 2009;25:485-91. <https://doi.org/10.1007/s00381-008-0762-x>
 13. Sharma MC, Jain D, Gupta A, Sarkar C, Suri V, Garg A, *et al.* Dysembryoplastic neuroepithelial tumor: a clinicopathological study of 32 cases. *Neurosurg Rev*. 2009;32:161-9. <https://doi.org/10.1007/s10143-008-0181-1>
 14. Chassoux F, Rodrigo S, Mellerio C, Landre E, Miquel C, Turak B, *et al.* Dysembryoplastic neuroepithelial tumors: an MRI-based scheme for epilepsy surgery. *Neurology*. 2012;79:1699-707. <https://doi.org/10.1212/WNL.0b013e31826e9aa9>
 15. Campos AR, Clusmann H, von Lehe M, Niehusmann P, Becker AJ, Schramm J, *et al.* Simple and complex dysembryoplastic neuroepithelial tumors (DNT) variants: clinical profile, MRI, and histopathology. *Neuroradiology*. 2009;51:433-43. <https://doi.org/10.1007/s00234-009-0511-1>
 16. Hennessy MJ, Elwes RD, Honavar M, Rabe-Hesketh S, Binnie CD, Polkey CE. Predictors of outcome and pathological considerations in the surgical treatment of intractable epilepsy associated with temporal lobe lesions. *J Neurol Neurosurg Psychiatry*. 2001;70:450-8. <https://doi.org/10.1136/jnnp.70.4.450>
 17. Luyken C, Blumcke I, Fimmers R, Urbach H, Elger CE, Wiestler OD, *et al.* The spectrum of long-term epilepsy-associated tumors: long-term seizure and tumor outcome and neurosurgical aspects. *Epilepsia*. 2003;44:822-30. <https://doi.org/10.1046/j.1528-1157.2003.56102.x>
 18. Fay-McClymont TB, Hrabok M, Sherman MSE, Hader WJ, Conolly MJ, Akdag S, *et al.* Systematic review and case series of neuropsychological functioning after epilepsy surgery in children with dysembryoplastic neuroepithelial tumors (DNET). *Epilepsy Behav*. 2012;23(4):481-6. <https://doi.org/10.1016/j.yebeh.2011.12.011>
 19. Luzzi S, Elia A, Del Maestro M, Elbabaa SK, Carnevale S, Guerrini F, *et al.* Dysembryoplastic neuroepithelial tumors: what you need to know. *World Neurosurg*. 2019;127:255-65. <https://doi.org/10.1016/j.wneu.2019.04.056>

Sažetak

ISHOD KIRURŠKOG LIJEČENJA I EPILEPTIČNIH NAPADAJA
KOD DISEMBRIOPLASTIČNIH NEUROEPITELIJSKIH TUMORA U ODRASLIH:
PRIKAZ SERIJE SLUČAJEVA

T. Sajko, K. Rotim, M. Jurilj, A. Rotim, B. Splavski i I. Jurčić Čulina

Disembrioplastični neuroepitelijski tumori (DNET) dobroćudne su novotvorine koje se svrstavaju u skupinu glioneuralnih tumora. Njihova je godišnja učestalost 0,03 na 100.000 stanovnika s vrškom pojavnosti u dobi između 10 i 14 godina života. Učestalost se smanjuje s porastom dobi, a tumori se rijetko javljaju nakon 20. godine života. Dokazani su kao uzrok epilepsije koja započinje u djetinjstvu i adolescenciji te kao drugi najčešći tip tumora koji uzrokuje epileptične napadaje u dječjoj dobi. Ovi rijetki tumori uzrokuju kronične i na terapiju otporne parcijalne složene epileptične napadaje s generalizacijom ili bez nje. U ovom radu prikazujemo institucijsku seriju šest odraslih bolesnika s DNET-om u području temporalnog režnja koji su se prezentirali složenim parcijalnim epileptičnim napadajima. Tri su bolesnika kirurški liječena lezionektomijom s totalnom resekcijom tumora. U preostala tri bolesnika učinjena je parcijalna resekcija, a dio tumora je ostavljen kako bi se izbjeglo oštećenje bazalnih ganglija. Svi su bolesnici nakon zahvata bili bez epileptičnih napadaja. U slučaju temporalne epilepsije, a u usporedbi s prednjom temporalnom lobektomijom, selektivno uklanjanje tumorske lezije bilo je povezano s lošijim ishodom liječenja. Uklanjanje tumora u cijelosti smatra se važnim prognostičkim pokazateljem ishoda liječenja u većini provedenih istraživanja.

Ključne riječi: *Disembrioplastični neuroepitelijski tumori; Epileptični napadaji; Kirurško liječenje; Ishod liječenja*