

Adie's pupil and ANNA-1 associated paraneoplastic neurologic syndromes predict complete response in limited-stage SCLC : a case report

Barisic, B.; Sreter, K. B

Source / Izvornik: **Prague Medical Report, 2015, 116, 51 - 52**

Journal article, Published version

Rad u časopisu, Objavljena verzija rada (izdavačev PDF)

Permanent link / Trajna poveznica: <https://urn.nsk.hr/urn:nbn:hr:220:799373>

Rights / Prava: [In copyright](#)/[Zaštićeno autorskim pravom.](#)

Download date / Datum preuzimanja: **2024-12-02**



Repository / Repozitorij:

[Repository of the Sestre milosrdnice University Hospital Center - KBCSM Repository](#)

Prague Medical REPORT

(Sborník lékařský)


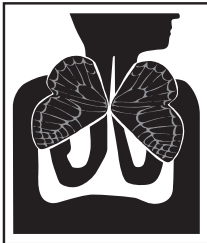
Multidisciplinary Biomedical Journal
of the First Faculty of Medicine,
Charles University in Prague

Vol. 116 (2015) Supplement

15th Central European Lung Cancer Conference including Best of WCLC 2015

November 28–30, 2015
Prague, Czech Republic

Abstract Book



Case Report: A 22-year old female, never-smoker, veterinary student was hospitalized in January 2011 due to angioedema after clindamycin was administered to treat a festering angina. From August till December 2011 she developed 3 festering anginas. There was no serious prior illness or cancer family history. In May 2012 she developed urticaria of unknown cause. By the end of the month breathing problems, headaches, dry cough, appetite and weight loss developed. Diagnostic tests revealed EGFR and k-RAS negative poorly differentiated adenocarcinoma of the lung T2N3M1b (bone metastases). Fluorescent in situ hybridization showed ALK translocation (p21, p23). Chemotherapy (pemetrexed/ cisplatin) was administered to the patient. After one cycle, no clinical benefit was seen so in July 2012 an oral treatment of 250 mg crizotinib twice daily was started. At the start of crizotinib therapy the patient's weight was 47 kg and performance status WHO 4. After two weeks of crizotinib, performance status improved to WHO 1 and the patient gained weight (4 kg). The only reported side effect was nausea grade 1. After two months of crizotinib PET-CT revealed a significant improvement but MR of the head showed asymptomatic progression of the disease, with multiple CNS metastases. Whole brain radiotherapy was administered (25Gy in 10 fractions). In February 2013 imaging revealed disease progression. Crizotinib was temporary suspended but then restored to slow down disease progression. Due to poor performance status she was unable to receive other treatments. She died in August 2013 at the age of 23. The patient developed several other allergies short before and during the treatment. Allergy to amoxicillin, clindamycin, ciprofloxacin, paracetamol, naproxicillin, metamizole, ketoprofen, azytromycin, citrus and tomato were discovered. Based on this, an immunologist was consulted and tests performed. Flow cytometry revealed no abnormalities in the concentration of lymphocytes B (CD9), T helper cells (CD4), cytotoxic T cells (CD8) and natural killer cells (CD56). What caused the total immunological collapse seen in this patient that resulted in multiple allergies and lung cancer remains unknown.

Adie's pupil and ANNA-1 associated paraneoplastic neurologic syndromes predict complete response in limited-stage SCLC: a case report

B. Barisic¹, K. B. Sreter²

¹*Clinic for Respiratory Diseases "Jordanovac", University Hospital Centre Zagreb, Zagreb;*

²*Department of Clinical Immunology, Pulmonology and Rheumatology, University Hospital Centre "Sestre Milosrdnice", Zagreb, Croatia*

Background: Paraneoplastic sensorimotor neuropathy with cerebellar ataxia (PSN CA) is an extremely rare, rapidly progressive, autoimmune disease associated

with the development of antibodies against neuronal-specific Hu proteins that are abnormally expressed in small cell lung cancer (SCLC).

Methods: A comprehensive chart and literature review was performed.

Results: We present the unique case of a 55-year-old obese woman, previous heavy smoker, who, during treatment with standard cisplatin-etoposide chemotherapy (total of six courses) for limited-stage SCLC (T1aN2M0, clinical stage IIIA), developed unilateral Adie pupil of the right eye and worsening symptoms consistent with PSN CA that led to significant neurological disability with severe axonal electrophysiological pattern on nerve conduction studies. Serology confirmed the presence of low-titre anti-neuronal nuclear antibodies (ANNA-1), previously named anti-Hu antibodies. Following plasmapheresis (five cycles), intravenous then oral corticosteroids, cyclophosphamide, and antiepileptic medication for myoclonus, the neurological symptoms remarkably abated. She is now sitting independently, feeding herself, mobile with the assistance of others, but with subsisting speech difficulties. The tumour has completely regressed with no recurrence on subsequent radiological examinations.

Conclusions: Although neuronal damage is reported in the literature to be irreversible, this case highlights the importance of early recognition and rapid treatment of paraneoplastic neurologic syndromes (PNS) as key to achieving significant recovery and marked improvement of neurologic deficit in some patients. In addition, this report extends the literature by confirming earlier studies showing that the presence of serum ANNA-1 in SCLC, an aggressive and challenging type of pulmonary carcinoma to treat, portends a more favourable prognosis and response to chemotherapy. ANNA-1 may be a useful biomarker for early SCLC diagnosis given that symptoms of PNS often precede tumour detection. Furthermore, all patients with SCLC, even in the absence of a neurological disorder, should be tested for serum ANNA-1. A multimodality approach to treating PNS composed of a combination of plasmapheresis, immunosuppressive therapy, and physical rehabilitation, is necessary to ensure beneficial clinical and oncologic outcomes.

Secondary malignant neoplasm in the lung and the low-grade liver cancer

N. Levická¹, G. Košturiaková¹, P. Vereš², V. Gál³

¹Specialized Hospital of St. Zoerardus Zobor, Nitra; ²Medicyt a.s., Bratislava;

³Alpha medical patológia, s.r.o., Bratislava, Slovakia