

Pneumopericardium and colo-pericardial fistula

Sreter, K B; Degoricija, V; Trbušić, M

Source / Izvornik: **QJM: An International Journal of Medicine, 2017, 110, 237 - 238**

Journal article, Published version

Rad u časopisu, Objavljena verzija rada (izdavačev PDF)

<https://doi.org/10.1093/qjmed/hcx015>

Permanent link / Trajna poveznica: <https://um.nsk.hr/um:nbn:hr:220:313999>

Rights / Prava: [In copyright](#)/[Zaštićeno autorskim pravom.](#)

Download date / Datum preuzimanja: **2024-12-27**



Repository / Repozitorij:

[Repository of the Sestre milosrdnice University Hospital Center - KBCSM Repository](#)

CASE REPORT

Pneumopericardium and colo-pericardial fistula

K.B. Sreter¹, V. Degoricija^{2,3} and M. Trbušić^{2,4}

From the ¹Department of Clinical Immunology, Pulmonology and Rheumatology, University Hospital Centre "Sestre Milosrdnice", Zagreb, Croatia, ²University of Zagreb School of Medicine, Zagreb, Croatia, ³Department of Internal Medicine, University Hospital Centre "Sestre Milosrdnice", Zagreb, Croatia and ⁴Department of Cardiology, University Hospital Centre "Sestre Milosrdnice", Zagreb, Croatia

Address correspondence to K.B. Sreter, M.D. email: ksreter@yahoo.com

Learning point for clinicians

This case aims to remind clinicians that uncommon differential diagnoses, such as a colo-pericardial fistula, should be considered in elderly patients displaying clinical signs consistent with an imminent cardiac tamponade, as well as a history of microcytic anemia of unknown etiology, particularly in the emergency setting of an acute pneumopericardium.

Case history

An 81-year-old Caucasian female, non-smoker, presented to the hospital emergency department (ED) due to shortness of breath at rest lasting several days. She denied cough, chest pain, syncope and fever. The patient had a relatively unremarkable medical history, apart from the past 11 months of severe microcytic anemia (E 3.23, Hgb 57, MCV 67, L 10.5, Trb 477, Fe 1.2, UIBC 55) requiring blood transfusions and daily oral iron supplements. Despite signs of bleeding from the gastrointestinal tract (laboratory results and blood in stool confirmed 3×), she was not keen on further diagnostic work-up. Her appetite was normal and body weight stable. On examination, she was tachycardic (pulse: 120 beats per minute), hypotensive (blood pressure: 105/60 mmHg), tachypnoic (respiratory rate: 23 breaths per minute), hypoxic (oxygen saturation on room air: 87%), afebrile (axillary temperature: 36.5°C), with distended neck veins, quiet cardiac sounds, decreased breath sounds bilaterally with basilar crackles, palpable muscular resistance in the upper abdomen and periumbilical region, faint peristalsis, and pitting edema of both lower legs. The electrocardiogram showed atrial fibrillation with low voltage of all leads. Chest X-ray (Figure 1a) showed a radiolucent oval area of air surrounding the heart (halo sign). Computed tomography (CT) scan of the thorax and upper abdomen confirmed an impressive pneumopericardium

(Figure 1b, scout view, black arrows) with large pleural effusion in the left hemithorax. The clinical picture and transthoracic heart ultrasound suggested a threatening cardiac tamponade. The patient was admitted for invasive treatment by emergency pericardiocentesis with subxiphoid approach under echocardiographic guidance. A significant amount of fecal-smelling air was aspirated. Pericardiocentesis resulted in temporary hemodynamic stabilization. However, the patient soon entered respiratory arrest and was immediately intubated and mechanically ventilated. Left-sided thoracentesis was performed with evacuation of a large amount of pleural fluid (1600 ml). The CT scan was reviewed closely with the staff radiologist. An invasive tumour was suspected in the transverse colon with resultant colo-pericardial fistula (Figure 1b, white arrow). The staff surgeon was consulted immediately. Upon re-stabilization of the patient with inotropes (noradrenaline and dobutamine intravenously), surgery was conducted on day 3 of hospitalization. During the operation, assessment of tumour invasion confirmed perforation of the splenic flexure by an infiltrating tumour of the transverse colon with invasion into the stomach, liver, spleen, tail of the pancreas and diaphragm. Given the invasiveness and inoperability of the primary cancer, a left hemicolectomy with formation of a stoma (colostomy) was performed. After the palliative surgical procedure, the patient improved sufficiently to be extubated. However, sepsis and multi-organ failure soon set in and the patient died 8 days after first presenting to the emergency room. The histopathological examination report of the excised surgical specimens, received posthumously, confirmed the diagnosis of adenocarcinoma of the colon (stage IIIB, pT3N1bMx, grade 2, low grade) with metastases to abdominal lymph nodes.

Discussion and conclusion

Colo-pericardial fistulas are extremely rare. They are typically described in association with colonic interposition after esophageal

Submitted: 16 December 2016; Revised (in revised form): 24 December 2016

© The Author 2017. Published by Oxford University Press on behalf of the Association of Physicians. All rights reserved.

For Permissions, please email: journals.permissions@oup.com

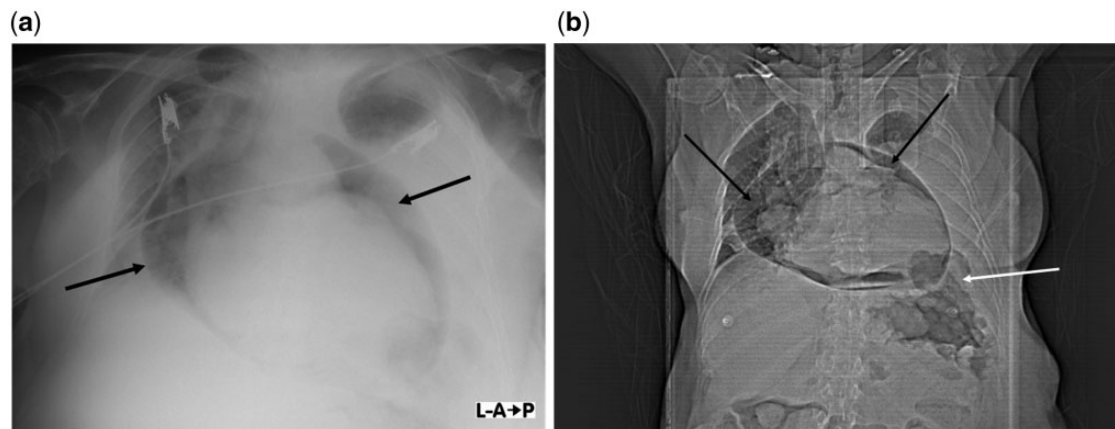


Figure 1. (a) Plain chest X-ray [anterior–posterior (AP) view, supine position] revealing air around the heart (black arrows). (b) Computed tomography scout radiograph of the thorax and upper abdomen (AP view, supine position) depicting a large pneumopericardium (black arrows) and suspected colo-pericardial fistula (white arrow).

replacement.^{1–3} Diaphragmatic tumour erosion and subsequent colo-pericardial fistulization is exceedingly unique and only one known record exists in the literature to date.⁴ This report represents the first case of a dramatic initial presentation of invasive colon cancer in the form of cardiac symptoms caused by an acute pneumopericardium resulting from a colo-pericardial fistula. Although the patient described here succumbed to post-operative complications, it is recommended that colo-pericardial fistulas should be diagnosed early and surgically managed as they are fatal in 50% of cases.⁴

Conflict of interest: None declared.

References

1. Wetstein L, Ergin MA, Griep RB. Colo-pericardial fistula: complication of colonic interposition. *Tex Heart Inst J* 1982; 9:373–6.
2. Parmar JM, Probert C, Clarke DB, Temple JG. Colo-pericardial and colo-caval fistula. Late complication of colon interposition. *Eur J Cardiothorac Surg* 1989; 3:371–2.
3. Stack ME, Saglia N, Vigneswaran WT. Successful primary repair of a colopericardial fistula: a late complication of esophageal replacement. *Ann Thorac Surg* 2015; 100:1459–61.
4. Cotton T, Haithcock B, Joseph M. Poop in the pericardium: a review and case report of colopericardial fistulas. *Chest* 2012; 142(4_MeetingAbstracts): 41A.