

Cistični oblik cemento-osificirajućeg fibroma etmoidnog sinusa

Shejbal, Dražen; Vonsović, Gabrijele; Baudoin, Tomislav; Vagić, Davor

Source / Izvornik: **Acta stomatologica Croatica : International journal of oral sciences and dental medicine, 2015, 49, 158 - 161**

Journal article, Published version

Rad u časopisu, Objavljena verzija rada (izdavačev PDF)

<https://doi.org/10.15644/asc49/2/10>

Permanent link / Trajna poveznica: <https://urn.nsk.hr/urn:nbn:hr:220:867792>

Rights / Prava: [In copyright](#)/[Zaštićeno autorskim pravom.](#)

Download date / Datum preuzimanja: **2024-11-23**



Repository / Repozitorij:

[Repository of the Sestre milosrdnice University Hospital Center - KBCSM Repository](#)

Dražen Shejbal¹, Gabrijela Vonsović², Tomislav Baudoin³, Davor Vagić⁴

Cistični oblik cemento-osificirajućeg fibroma etmoidnog sinusa

Cystic Shape Cemento-Ossifying Fibroma of Ethmoid Sinus

¹ Opća bolnica Varaždin
OB Varaždin² Dom zdravlja Županija
Županija Health Centre³ Medicinski fakultet Sveučilišta u Zagrebu – KBC Sestre milosrdnice
School of Medicine University of Zagreb, 'Sestre milosrdnice' University Hospital, Zagreb⁴ Stomatološki fakultet Sveučilišta u Zagrebu – KBC Sestre milosrdnice
School of Dental Medicine, University of Zagreb, 'Sestre milosrdnice' University Hospital, Zagreb

Sažetak

Cementofibromi skupina su rijetkih dobroćudnih tumora koji nastaju iz peridontalne membrane. Njihov izgled i klinička slika variraju. Zajednička im je veća ili manja produkcija cementnoga tkiva. U većini slučajeva tumori su mali jer im cementomi brzo dozrijevaju i postaju neaktivni, pa novotvorina prestaje rasti. Najčešće se razvijaju u mandibuli, a zatim slijedi maksila. Ostale lokacije, poput paranazalnih šupljina te mekih tkiva kostiju i glave, iznimno su rijetke. Opisan je slučaj devetogodišnje djevojčice koja je imala cementni fibrozirajući tumor sa psamomskim uklopinama, a nastao je u etmoidnom sinusu. Zbog frontalnih glavobolja i smetnji s vidom desno učinjen je NMR koji je pokazao mukocelu prednjega i stražnjega etmoida s destrukcijom orbitalne stijenke i probojem u orbitu. U desnom maksilarnom sinusu uočena je retencija i zadebljana sluznica. Rinoskopski vidjela se kuglasta tvorba u srednjem nosnom hodniku koja je imponirala kao konha buloza. Endoskopski je ustanovljeno da je tumor prominirao ispred srednje nosne školjke u desni kavum nosa, razmekšao krov etmoida, prodirao prema bazi lubanje te adherirao i potiskivao orbitu. Uklonjen je FESS tehnikom, a PHD je naknadno pokazao da nije bila riječ o mukokeli, nego o cementofibromu.

Zaprimljen: 15. veljače 2015.

Prihvaćen: 11. svibnja 2015.

Adresa za dopisivanje

Davor Vagić
Sveučilište u Zagrebu
Stomatološki fakultet
KBC Sestre milosrdnice
10 000 Zagreb
davor.vagic@kbcsm.hr

Ključne riječi

fibrom; cementom; etmoidni sinus; membrana sluznice; nosna školjka

Uvod

Cement je tvrdo, mineralizirano tkivo koje pokriva korijene vitalnih zuba. To je posebno vezivno tkivo, slično koštanoj, a najvažnija razlika je cementna avaskularna struktura. Cementomi nastaju iz multipotentnih stanica peridontalne membrane, a te stanice zbog multipotentnosti mogu se pretvoriti u vezivno tkivo, cement ili kost. Patološkim razvojem mogu, dakle, iz peridontalne membrane nastati tumori sastavljeni u različitim omjerima od veziva, cementa i lamelarne kosti (1).

Benigne fibrozno osificirajuće lezije problem su u dijagnostici i klasifikaciji. Prema klasifikaciji WHO-a iz 1992. godine raščlanjene su na tumorske lezije, cementofibrome i osificirajuće fibrome, te fibrozne displazije koje nisu tumori u užem smislu. U mnogobrojnim klasifikacijama pokušavalo se te novotvorine svrstati prema njihovoj kliničkoj slici, agresivnosti i prognozi. Tako su uvedeni termini *juvenile active ossifying fibroma*, *agresive*, *active*, *psammomatoid*, *juvenile active*, no i dalje su kontroverzni pa su predmet rasprava (2). Tumori lokalizirani izvan čeljusti poseban su klinički i dijagnostički problem.

Introduction

Cementum is the bonelike, mineralised tissue covering the roots of vital teeth. It is a specialised connective tissue, similar to the osseous tissue, and the most important difference is cemental avascular structure. Cementoma develop from multipotent cells of the periodontal membrane, and by their multipotency those cells may produce connective tissue, cementum or bone. Pathological development of the periodontal membrane may thus result in the formation of tumours, composed of connective tissue, cementum and lamellar bone in different ratios (1).

Benign fibrous ossifying lesions are a problem in diagnostics and classification. The WHO classification from 1992 divides them into tumour lesions; cementifying fibroma and ossifying fibroma, and fibrous dysplasias, which are not tumours in the narrow sense. Numerous classifications aimed to classify tumours according to their clinical picture, aggressiveness and prognosis. The terms thus introduced, such as "juvenile active ossifying fibroma", "aggressive", "active", "psammomatoid", "juvenile active", are still rather controversial (2). Special clinical and diagnostic challenges are tumours located outside the jaws.

Prikaz slučaja

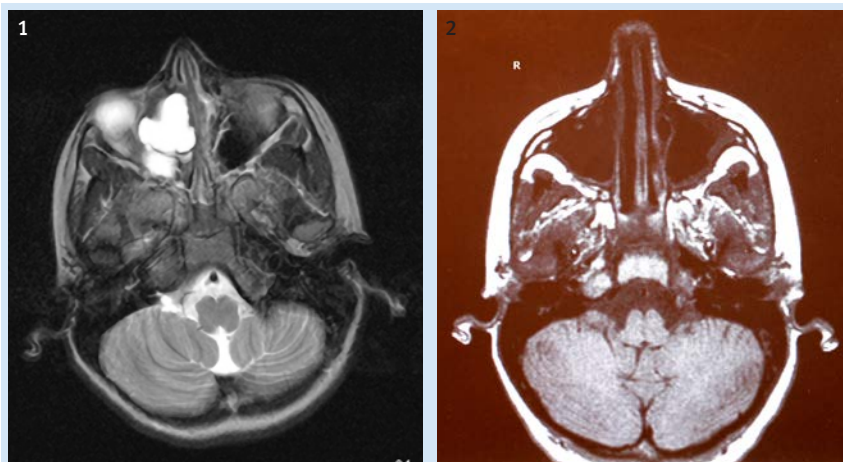
Opisan je slučaj devetogodišnje djevojčice koja je bila primljena u bolnicu zbog dvomjesečnih tegoba: frontalne glavobolje, zamagljenog vida i boli u desnom oku. Obiteljska anamneza bila je bez osobitosti. Pacijentica je bila alergična na *dermatophagoides* i pelud. Svi laboratorijski nalazi i rendgenogram pluća bili su uredni. U statusu ustanovljenom pri prijemu vidjela se kuglasta tvorba u srednjem nosnom hodniku koja je imponirala kao konha buloza. Nije bilo patološke sekrecije, a ostali otorinolaringološki nalazi bili su normalni.

Magnetska rezonancija pokazala je mukokelu prednjega i stražnjega etmoida koja je destruirala stijenku orbite i ušla u nju, te retenciju i zadebljanu sluznicu maksilarnog sinusa desno (slika 1.). Zbog toga je funkcionalnim edoskopskim zahvatom obavljena interna etmoidektomija desno i ekstirpacija mukokele. Endoskopija nosa otkrila je u srednjem nosnom hodniku mukokelu koja je prominirala dosta ispred prednjega dijela srednje nosne školjke. Tvorba je probušena i iz nje je aspiriran bistri sadržaj. Stijenka mukokele odluštila se od krova etmoida, srednje nosne školjke i periorbite uz koju je adherirala i koju je mukocela potiskivala. Kost baze lubanje bila je u području stražnjeg etmoida razmekšana. Prošireno je prirodno ušće maksilarnog sinusa u kojemu je pronađena zadebljana sluznica i nešto retencijskog sekreta. Endoskopski zahvat ponovljen je nekoliko puta bez većih mutilacijskih posljedica, a nije utjecao ni na vid ni na nosnu prohodnost (slika 2.).

Case Report

We report a case of a nine-year-old girl, referred to our hospital because of frontal headaches, impaired vision and pain in the right eye. Her family's medical history was unremarkable; the patient is sensitive to dermatophagoides and pollen. All laboratory test results and lung x-rays were negative. The status at admission to hospital revealed a ball-shaped mass in the medium nasal meatus, which was defined as a *concha bullosa*. There was no pathological secretion; other ENT exams were normal.

MR imaging showed a mucocele of the front and rear ethmoid, destroying the orbital wall and breaking into the orbit, retention and thickened mucous membrane of the right maxillary sinus (Figure 1). The patient underwent an internal ethmoidectomy on the right side and extirpation of the mucocele by functional endoscopic surgery. Nasal endoscopy showed a mucocele in the medium nasal meatus, which was protruding fairly in front of the front pole of the medium nasal *conchae*. The formation was punctured and clear liquid was aspirated from the same. The mucocele wall peeled off from the ethmoid roof, the medium nasal shell and the periorbit to which it adhered and which was pushed by the mucocele. The endoscopic examination revealed softened bone of the base of the skull in the region of the posterior ethmoid. The natural orifice of the maxillary sinus dilated, in which thickened mucous membrane and some retention secretion were found. Endoscopies were repeated several times, without major mutilation consequences and without consequences for vision and nasal passages (Figure 2).



Slika 1. MR prikaz prije kirurškog zahvata – vidi se mukocela stražnjeg etmoida i frontalnog sinusa s destrukcijom zida orbite i probojem u orbitu

Figure 1 MR imaging before surgery; mucocele of the front and rear ethmoid, destructing the orbital wall and breaking into the orbit

Slika 2. MR prikaz pet godina nakon zahvata – bez naznaka o povratku bolesti

Figure 2 MR imaging five years after surgery; without recurrence of disease

Rasprava

Može se reći da nema jedinstvenih patomorfoloških kriterija za razlikovanje cementoosificirajućih displazija i cementoosificirajućih fibroma. Fibrome histološki najčešće obilježava jednak omjer kalcificiranog i fibroznog tkiva, no taj se omjer može mijenjati, ovisno o subtipu. Kalcificirane strukture mrežasto su povezane ili imaju izdvojenu lamelarnu strukturu u kojoj, uz pokoji osteoklast, dominiraju osteoblasti. Okrugla ili loburilana cementna tjelešca mogu biti u većem ili manjem broju uklopljena u tumor, a njihova pre-

Discussion

It is possible to state that there are no uniform pathomorphological criteria for differentiation between cemento-ossifying dysplasias and cemento-ossifying fibroma. Histologically, fibromas are most often characterised by equal parts of calcified tissue and fibrous tissue; however, the ratio between these two tissues can vary, depending on the fibroma subtype. Calcified structures show a grid-like or an isolated lamellar structure with predominant osteoblasts and a few osteoclasts. Round or lobulated bone density mass may be

vaga daje sliku *cementofibroma*. Prisutnost mineraliziranih tjelešaca – *psammoma* spominje se u recentnijoj literaturi. To su ovalna mineralizirana tjelešca neokvirena osteoblastima. Njihovo vezivno tkivo građeno je od slojeva mrežastih fibroblastičnih ili zvjezdolikih stanica s mjestima nepravilnog izgleda. Takva, mikroskopska građa izravno je odgovorna i za glavna makropatološka i klinička obilježja tumora, pogotovo u usporedbi sa srodnim displazijama, a to su specifična radiolucenost, enkapsulacija te spor i neinfiltirativan rast (3, 4).

Cementofibromi najčešće se pojavljuju periapikalno u maksili i mandibuli, što je logično s obzirom na podrijetlo iz peridontalne membrane. Tijekom rasta prolaze tri klinička stadija – prvi stadij razara kost, no tumor je bez uklopina kosti i cementa, u drugome nastaju uklopine cementa i kosti i tada novotvorina postaje opacificirajuće luminescentna, a kada dosegne treći stadij prestaje rasti. Obilježava je dobro ograničena, radiografski hiperlucenostna lezija kosti. Prosječni promjer tumora nakon završenog rasta je 3,8 cm (5).

Cementomi locirani izvan maksile i mandibule umnogome se razlikuju jer ostaju u nezrelom, aktivnom stadiju, što rezultira destruktivnim rastom i čestim recidivima. Prvi slučaj opisao je Krausen sa suradnicima 1977. godine (6). Nastanak tumora izvan čeljusti objašnjava se ektopičnim stanicama peridontalne membrane podrijetlom iz primitivnoga mezenhimalnog grebena koje tamo mogu dospjeti iz embriološki zaostalog tkiva te nakon kirurškoga zahvata ili infekcije (7, 8, 9). Predominacija psammatoznih tjelešaca pronađena je u oko 11 posto svih cementofibroma, no njihova učestalost raste s udaljenošću lokacije od čeljusti. Tako bi psamoidna tjelešca mogla upozoravati na agresivnije ponašanje tumora netipičnih lokalizacija: etmoidnih i frontalnih sinusa, kostiju i mekih tkiva glave (9).

Do sredine 90-tih smatrao se cementoosificirajući fibrom izvan čeljusti raritetom, no recentno se počelo objavljivati po nekoliko slučajeva godišnje. Ovdje opisani slučaj iznimno je rijedak zbog cistične forme lezije. Fujimoto i suradnici prvi su objavili takav slučaj. Cističnu formu lezije nakon biokemijske analize aspirata pokušali su rastumačiti kao rupturu krvne žile i kao posljedičnu kompresijsku nekrozu samog tumora (10). Iako agresivni, skloni recidiviranju te prodiranju u okolne vitalne strukture lica, izvančeljustni cementofibromi imaju dobru prognozu, bez mutiliranja. Resekcija je terapija izbora. Moguća je maligna ateracija, no iznimno je rijetka (1, 4, 7, 10).

more or less incorporated into the tumour, and their prevalence shows an image of a “cementifying fibroma”. The presence of mineralised ossicles, “psammoma”, is mentioned in recent literature. These are mineralised oval ossicles, not rimmed with osteoblasts. Connective tissue is composed of layers of spindle fibroblastic or stellate cells with focal areas of storiform patterns. Such microscopic composition is also directly responsible for major macropathological and clinical features of tumours, particularly in contrast to related dysplasias, and these are radiolucency, encapsulation, and slow and non-infiltrative growth (3, 4).

Most often, cementifying fibromas occur periapically in the maxilla and mandible; which is logical in view of its origin from the periodontal ligament. There are three clinical stages in their growth. The first stage destroys the bone, the tumour is without infiltrations of bone and cementum; in the second stage there are infiltrations of bone and cementum, and the tumour becomes opacifying luminiscent. When it reaches the third stage, the tumour stops to grow. It is marked by a well-demarcated, radiographically hyperlucenost lesion and bone lesions. An average tumour diameter after the end of its growth is 3.8 cm (5).

Cementoma with sites outside the maxilla and mandible are quite different because they remain in an immature, active stage, which results in destructive growth and frequent relapses. The first case was described by Krausen et al. in 1977 (6). Tumour development outside the jaws is explained with ectopic cells of the periodontal membrane originating from the primitive mesenchymal ridge, which can appear there from embryologically underdeveloped tissue, after a surgery or after infection (7, 8, 9). Predominance of psammomatoid cells is found in approximately 11 % of all cementifying osteofibroma. However, the frequency of cells increases with the distance between the site and the jaws. Thus psammoid cells would presuppose more aggressive behaviour of tumours with untypical sites: ethmoid and frontal sinuses, bones and soft tissues of the head (9).

Until the mid-1990s, the occurrence of cemento-ossifying fibromas outside the jaws was considered a rarity. However, in recent times, several cases are reported each year. The case reported above is extremely rare due to a cystic shape of the lesion itself. Fujimoto et al. reported first on such a case. Upon biochemical analysis of the aspirate they attempted to explain the cystic shape of the lesion with a rupture of the blood vessel and consequential compression necrosis of the tumour itself (10). Although aggressive, prone to relapses and penetration into surrounding vital structures of the face, cementifying fibromas outside the area of the jaws have a good prognosis, without mutilating consequences. Resection is the therapy of choice. Malignant alteration is possible, however, rarely (1, 4, 7, 10).

Abstract

Cemento-ossifying fibromas are a group of rarely occurring benign tumours, developing from the periodontal membrane and varying considerably in appearance and in the progress of the disease. Their common feature is higher or lower production of cemental tissue. In most cases the tumours are small because their cementoma mature quickly and become inactive, which causes the tumour to stop growing. They develop most frequently in the mandible and also in the maxilla. Other sites, such as paranasal cavities, soft tissues and bones of the head, are extremely rare. The case of a cemento-fibrosing tumour with psammoma infiltrations, developing from the ethmoid sinus in a nine-year-old girl is reported. Due to frontal headaches and sight defects as well as impaired vision on the right side, NMR was done, which showed a mucocele of the front and rear ethmoid with destruction of the orbital wall and a breakthrough into the orbit. The right maxillary sinus showed a visible retention and a thickened mucous membrane. A rhinoscopy revealed a ball-shaped spherical mass in the medial nasal meatus, which was defined as *concha bullosa*. An endoscopic examination showed that the tumour protruded in front of the medium nasal concha into the right nasal cavity, softened the ethmoid roof, penetrated toward the base of the skull, adhered and pushed the orbit. It was removed by FESS technique, and PHD revealed subsequently that it was not a mucocele but a cemento-ossifying fibroma.

Received: February 15, 2015

Accepted: May 11, 2015

Address for correspondence

Davor Vagić
University of Zagreb
School of Dental Medicine
'Sestre milosrdnice' University Hospital,
Zagreb
davor.vagic@kbcsm.hr

Key words

Fibroma; Cementoma; Ethmoid Sinus;
Mucous Membrane; Turbinates

References

1. Shanmugham MS. Cementifying fibroma of the ethmoidal sinus. *J Laryngol Otol* 1984;98:639-642.
2. Brannon RB, Fowler CB. Benign fibro osseous lesions: a review of current concepts. *Adv Anat pathol*. 2001;8(3):126-43
3. Su L, Weathers DR, Waldron CA. Distinguishing features of focal cemento-osseous dysplasia and cemento-ossifying fibromas. I. A pathologic spectrum of 316 cases *Med Oral Pathol Oral radiol endod* 1997;84:301-9.
4. Waldrom CA. Fibro-osseous lesions of the jaws. *J Oral Maxillofac Surg* 1993;51:828-35.
5. Krausen AS, Pullen PA, Zoografakis G. Cementoma II. Aggressive cemento-ossifying fibroma of the ethmoid region. *Archives of otolaryngology* 1977;103:371-373.
6. Su L, Weathers DR, Waldron CA. Distinguishing features of focal cemento-osseous dysplasia and cemento-ossifying fibromas. Clinical and radiologic spectrum of 316 cases. *Med Oral Pathol Oral radiol endod* 1997;84:540-9
7. Eversole LR, Leider AS, Nelson K. Ossifying fibroma: a clinico-pathological study of sixty four cases. *Oral surg. oral med oral pathol* 1985;60:510
8. Cakir B, Karadayi N. Ossifying fibroma in the nasopharynx. A case report. *Clin Imag* 1991;15:290-292
9. Jung LS, Choi KH, Park YA, Song CH, Kwon MS. Cemento-ossifying fibroma presenting as a mass of the parapharyngeal and masticator space. *Am J neuroradiol* 1999;20:1744-1746
10. Fujimoto Y, Katoh M, Miyata M, Kawai T, Saito K, Morita M. Cystic cemento ossifying fibroma of the ethmoidal cells (a case report). *J Laryngol Otol* 1987;101(9):946-52