

Successful factor XIII treatment of refractory chylothorax in tuberous sclerosis complex-associated lymphangiomyomatosis, multifocal multinodular pneumocyte hyperplasia and mediastinal lymphadenopathy

Sreter, K.B.; Barisic, B.; Light, R.W.

Source / Izvornik: *Lymphology*, 2017, 50, 183 - 187

Journal article, Published version

Rad u časopisu, Objavljena verzija rada (izdavačev PDF)

Permanent link / Trajna poveznica: <https://urn.nsk.hr/urn:nbn:hr:220:979538>

Rights / Prava: [In copyright](#) / [Zaštićeno autorskim pravom.](#)

Download date / Datum preuzimanja: **2024-12-09**



Repository / Repozitorij:

[Repository of the Sestre milosrdnice University Hospital Center - KBCSM Repository](#)

**SUCCESSFUL FACTOR XIII TREATMENT OF
REFRACTORY CHYLOTHORAX IN TUBEROUS SCLEROSIS
COMPLEX-ASSOCIATED LYMPHANGIOLEIOMYOMATOSIS,
MULTIFOCAL MULTINODULAR PNEUMOCYTE HYPERPLASIA
AND MEDIASTINAL LYMPHADENOPATHY**

K.B. Sreter, B. Barisic, R.W. Light

Department of Clinical Immunology, Pulmonology and Rheumatology (KBS), University Hospital Centre "Sestre Milosrdnice," Zagreb, Croatia; Clinic for Respiratory Diseases "Jordanovac" (BB), University Hospital Centre Zagreb, Zagreb, Croatia; Division of Allergy, Pulmonary and Critical Care Medicine (RWL), Vanderbilt University Medical Center, Nashville, Tennessee USA

ABSTRACT

Tuberous sclerosis complex (TSC) or Bourneville disease is a rare autosomal dominant neurocutaneous disorder that affects various organs. Pulmonary involvement in TSC may consist of lymphangioleiomyomatosis (LAM) and multifocal micronodular pneumocyte hyperplasia (MMPH), occurring together or alone. In patients with TSC-LAM, chylous pleural effusion (CPE) is a rare, though well-recognized, complication with an unpredictable clinical course. In refractory or persistent CPE, optimal management remains a clinical challenge. We report the unique case of a 29-year-old Caucasian female, never-smoker, with definite TSC since infancy, characterized by seizures, facial angiofibromas ("adenoma sebaceum"), bilateral renal angiomyolipomas, hepatic angiomyolipomas, subcortical/cortical tubers, and subependymal nodules. At 27 years old, due to bleeding from the renal angiomyolipomas, she underwent nephrectomy, first of the right, and then a year and 9 months later, of the left kidney. She was hemodialysis dependent for the next five years until cadaveric kidney transplantation. The medical history was also remarkable for recurrent exudative lymphocytic PE despite

repeated therapeutic thoracenteses, with first presentation at 23.5 years of age. Chylothorax was initially diagnosed at 24 years and 8 months old (PE triglycerides 4.53 mmol/L), and reconfirmed at age 29 (PE triglycerides 12.46-15.30 mmol/L). Computerized tomography scan of the thorax showed a large encapsulated PE in the left lung field, multiple thin-walled cysts (≤ 5 mm in diameter) in the lung parenchyma bilaterally, and mediastinal lymphadenopathy – all prominent features of LAM – as well as nodular pulmonary lesions (≤ 3 mm in diameter) consistent with MMPH. Given the persistent nature of the CPE, a five-day course of recombinant human factor XIII (FXIII) was administered intravenously. The chylothorax completely resolved within three months. There has been no recurrence of CPE on follow-up chest X-rays (i.e., total follow-up period of 53 months). This report suggests that the transglutaminase FXIII, a blood coagulation factor, may have an important clinical benefit in treating recurrent or thoracentesis-refractory CPE in TSC-LAM. To our knowledge, this is the first known case in the literature describing the successful treatment of CPE with FXIII in TSC-LAM. Because CPE is rare and there is currently no gold standard for its management, regardless

of etiology, further research is warranted to investigate the potential clinical use of FXIII as an effective and safe treatment strategy in selected patients.

Keywords: Chylous pleural effusion, lymphangi leiomyomatosis, mediastinal lymphadenopathy, multifocal micronodular pneumocyte hyperplasia, recombinant human factor XIII, tuberous sclerosis complex

CASE REPORT

A 29-year-old Caucasian female, never-smoker, was first diagnosed with tuberous sclerosis complex (TSC) at 1.5 years of age. She initially presented with seizures and facial angiofibromas. Diagnostic imaging later depicted subcortical/cortical tubers, subependymal nodules, hepatic angiomyolipomas (AMLs), and bilateral renal AMLs. At 23.5 years old, she developed left-sided pleural effusion (PE) that spontaneously regressed. A year later, the patient presented to the emergency department with progressive dyspnea and right-sided chest pain. The PE had returned, this time bilaterally and predominantly right-sided, along with ascites. Therapeutic thoracentesis was performed and exudative chylous PE (CPE) was confirmed (PE triglycerides 4.53 mmol/L). The right-sided CPE began to resolve following repeated thoracentesis and conservative treatment, while the left-sided CPE persisted throughout the hospitalization. Nephrectomy was performed on the right kidney at 27 years of age, and on the left kidney a year and 9 months later, due to acute spontaneous bleeding of the bilateral renal AMLs. The patient was left hemodialysis dependent until kidney transplantation five years later.

At 29 years of age, the patient was admitted to the hospital for additional work-up of progressively worsening left-sided PE and radiologically verified mediastinal lymphadenopathy. The computerized tomography (CT) scan of the thorax revealed diffuse cysts (≤ 5 mm in diameter) and

nodular lesions (≤ 3 mm in diameter) consistent with lymphangi leiomyomatosis (LAM) and multifocal micronodular pneumocyte hyperplasia (MMPH), respectively, as well as mediastinal lymphadenopathy with necrosis, in addition to a large PE in the left hemithorax. During hospitalization, left-sided pleural aspiration yielded a milky-white CPE (protein 58 g/L, cholesterol 2.7 mmol/L, triglycerides 12.46 mmol/L). Bronchoscopy with transbronchial needle aspiration of the enlarged subcarinal lymph nodes yielded necrosis and detritus. Tuberculosis as a potential cause was excluded (i.e., negative tuberculosis skin test, sputum, pleural fluid, bronchoscopic samples, and quantiferon test).

Three months later, follow-up radiological imaging depicted larger left-sided PE and mediastinal lymph nodes. During readmission after another two months, thoracentesis was repeated, but without long-term success. Lymphocytic CPE with extremely elevated triglyceride levels (12.75 - 15.3 mmol/L or 493.0 - 591.6 mg/dL) was established. Repeat bronchoscopy and transbronchial needle biopsy of mediastinal lymph nodes revealed granulomatous reaction with necrosis. Despite tuberculosis not being detected, the patient was started on ex-juvantibus anti-tuberculosis therapy, lasting a year (four-drug antibiotic therapy for the first six weeks, then two antibiotics thereafter). This measure was necessary as the patient was undergoing pre-kidney transplantation evaluation and preparation.

Given the persistent CPE (Figs. 1 a-b), during this hospitalization, an intravenous injection of human recombinant factor XIII concentrate (Fibrogammin® 250 (CSL Behring GmbH, Marburg, Germany)) at 1250 international units (IU) per day (up to 35 IU per kg body weight maximal daily dose; the patient's weight was 38 kg and height 158 cm) was administered for a total of five days, as recommended by the manufacturer. The pre-treatment value of plasma FXIII was 1.66 (normal value 0.70-1.40). A steady, but remarkable, reduction in CPE was noted on

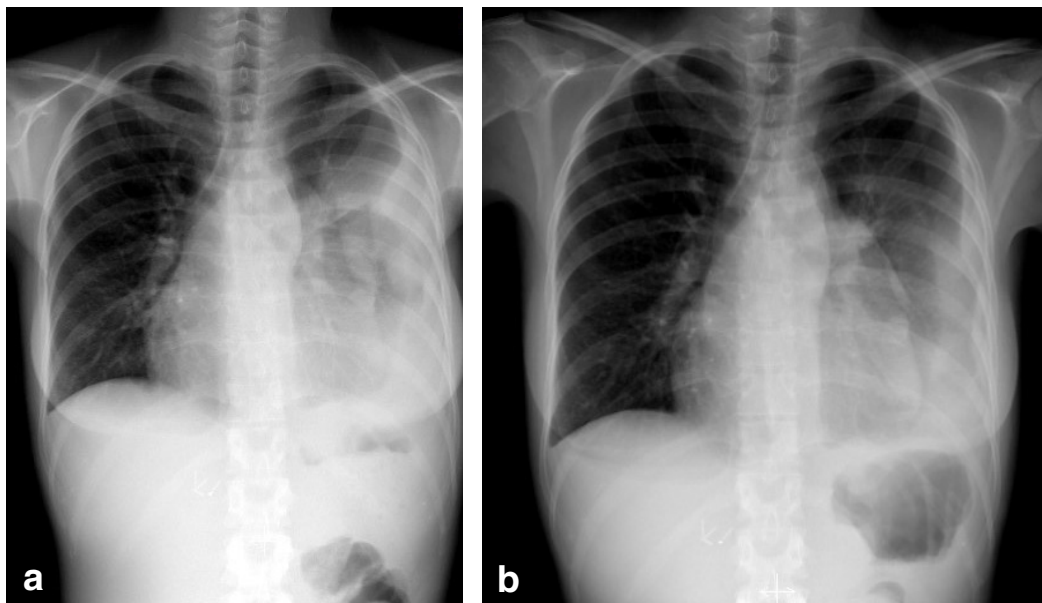


Fig. 1. Chest x-ray showing large left-sided PE at a) one month and b) one week before FXIII treatment.

subsequent serial chest X-rays within a few weeks, with complete resolution within three months (*Fig. 2a*). No recurrence of chylothorax was observed on follow-up chest X-rays three years later (*Fig. 2b*). Due to her epilepsy and TSC-related brain lesions, everolimus, a mammalian target of rapamycin inhibitor and immunosuppressive therapy, was initiated in preparation for cadaveric kidney transplantation the following year (i.e., four years after FXIII administration). Chylothorax has not recurred over a total follow-up period of 53 months.

DISCUSSION

The rare multisystem genetic disorder, TSC, was first described in 1862 by von Recklinghausen (1). It is a variable disease, occurring in about 1 in 6000 live births, and is clinically diagnosed based on the presence of major and/or minor features (2). Lutembacher first reported the observation of cystic and nodular changes in the lungs of a TSC patient in 1918 (3). Pulmonary involvement in TSC is predominantly found

in premenopausal females and was once thought to occur in less than 3% of patients (4). Over the past several years, however, data have emerged demonstrating the presence of thin-walled lung cysts in a greater proportion of TSC patients (i.e., in one study, 42% of females and 13% of males) (5).

LAM, an uncommon cystic lung disease, and MMPH, with nodular lung lesions, can be diagnosed in patients with definite or probable TSC based on pulmonary characteristics seen on high-resolution CT scan of the thorax (2). Recent studies on women with TSC found pulmonary involvement in 77% of patients (49% LAM with or without MMPH, and 28% MMPH alone) (6), and an increased prevalence of LAM in an age-dependent manner, reaching 81% in subjects 40 years of age and older (7). Moreover, in TSC patients, including both males and females, the prevalence of multiple pulmonary nodules representing MMPH was 57% (8).

Lymphatic involvement in LAM, according to a review by Taveira-DaSilva and Moss (2015), may occur in the posterior, mediastinal, retroperitoneal and pelvic lymph

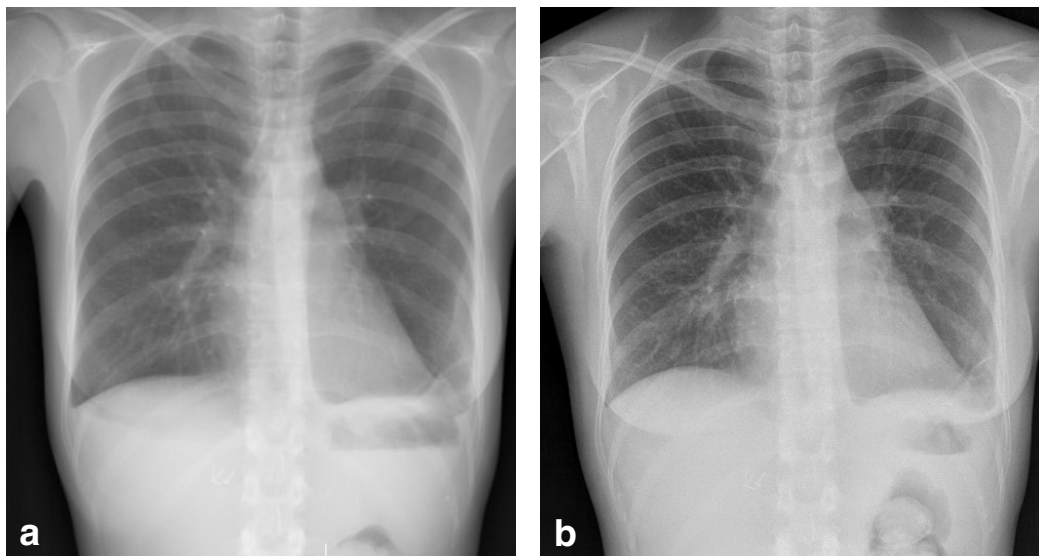


Fig. 2. Complete resolution of left-sided CPE is depicted on chest x-ray at a) three months and b) three years after FXIII administration.

nodes (9). The presentation may include lymphangioliomyomas, lymphadenopathy, PEs (i.e., chylothorax), and ascites, among others (9). Mediastinal and retroperitoneal lymphadenopathy in women of child-bearing age, as seen on CT scan and associated with a CPE, is likely to be LAM (10). According to Gupta et al, lymphadenopathy (abdominal and/or thoracic) is more common in LAM only patients (30%) than in those with TSC-LAM (9%) (11).

Chylothorax is a relatively rare condition in LAM (approximately 30% of patients) and seldom occurs in association with TSC-LAM (11). Management of CPE remains a clinical challenge and should be individualized. There are a number of conservative, surgical and interventional radiological therapeutic options available (12). Human factor XIII (FXIII) is a multifunctional plasma transglutaminase with many documented clinical benefits in addition to its role as the final enzyme in the coagulation cascade (13). Administration of FXIII in the conservative treatment of chylothorax has been shown to be particularly beneficial in the post-operative setting, such as after lung transplantation for

LAM (14), open-heart surgery in children (15), or prolonged air leak after pulmonary lobectomy (16).

The use of FXIII as a less invasive treatment option for CPE in TSC, however, is a relatively novel concept that has until now remained unexplored. We herein presented the unique case of a young woman with definite TSC, previously binephrectomized due to acute hemorrhage from bilateral renal angiomyolipomas, who developed refractory CPE in the context of LAM, MMPH, and mediastinal lymphadenopathy. Complete resolution of the CPE was observed following intravenous administration of recombinant human FXIII, with no further recurrence. To our knowledge, this is the first reported case of CPE associated with TSC that seems to have been successfully managed with intravenously administered FXIII. The exact mechanism of FXIII in diminishing the CPE, nevertheless, remains unclear. Given that FXIII is a key factor in wound healing and tissue repair, in addition to clot stabilization, its administration may enhance repair of damaged lymphatic tissues in TSC-LAM patients with chylothorax.

CONCLUSIONS

In summary, this report highlights the potential therapeutic role of FXIII in efficiently resolving CPE. In addition, it extends the literature by contributing a first case of CPE associated with TSC that was successfully treated with intravenously administered FXIII. Recombinant factor XIII may prove to be clinically beneficial in successfully managing CPE associated not only with TSC-LAM, but other etiologies as well. Future randomized prospective studies with FXIII are recommended to confirm efficacy and safety in chylothorax treatment. Further research is also warranted to elucidate the mechanism of action of FXIII in repairing lymphatic vessel damage/obstruction, leading to complete resolution of CPE.

CONFLICT OF INTEREST AND DISCLOSURE

All authors declare that no competing financial interests exist.

REFERENCES

1. von Recklinghausen, F: Die Lymphelfasse und ihre Beziehung zum Bindegewebe. Berlin: A. Hirschwald (1862).
2. Northrup, H, DA Krueger: International Tuberous Sclerosis Complex Consensus Group: Tuberous sclerosis complex diagnostic criteria update: Recommendations of the 2012 International Tuberous Sclerosis Complex Consensus Conference. *Pediatr. Neurol.* 49 (2013), 243-254.
3. Lutembacher, R: Dysembryomes metatypiques des reins; carcinose submiliaire aigue du poumon avec emphyseme generalise et double pneumothorax. *Ann. Med.* 5 (1918), 435-450.
4. Castro, M, CW Shepherd, MR Gomez, et al: Pulmonary tuberous sclerosis. *Chest* 107 (1995), 189-195.
5. Adriaensen, ME, CM Schaefer-Prokop, DA Duyndam, et al: Radiological evidence of lymphangioleiomyomatosis in female and male patients with tuberous sclerosis complex. *Clin. Radiol.* 66 (2011), 625-628.
6. Di Marco, F, S Terraneo, G Imeri, et al: Women with TSC: Relationship between clinical, lung function and radiological features in a genotyped population investigated for lymphangioleiomyomatosis. *PLoS One* 11 (2016), e0155331. doi: 10.1371/journal.pone.0155331.
7. Cudzilo, CJ, RD Szczesniak, AS Brody, et al: Lymphangioleiomyomatosis screening in women with tuberous sclerosis. *Chest* 144 (2013), 578-585.
8. Muzykewicz, DA, ME Black, V Muse, et al: Multifocal micronodular pneumocyte hyperplasia: Computed tomographic appearance and follow-up in tuberous sclerosis complex. *J. Comput. Assist. Tomogr.* 36 (2012), 518-522.
9. Taveira-DaSilva, AM, J Moss: Clinical features, epidemiology, and therapy of lymphangioleiomyomatosis. *Clin. Epidemiol.* 7 (2015), 249-257. doi: 10.2147/CLEP.S50780.
10. Woodring, JH, RS Howard 2nd, MV Johnson: Massive low-attenuation mediastinal, retroperitoneal, and pelvic lymphadenopathy on CT from lymphangioleiomyomatosis. Case report. *Clin. Imaging* 18 (1994), 7-11.
11. Gupta, R, M Kitaichi, Y Inoue, et al: Lymphatic manifestations of lymphangioleiomyomatosis. *Lymphology* 47 (2014), 106-117.
12. Schild, HH, CP Strassburg, A Welz, et al: Treatment options in patients with chylothorax. *Dtsch. Arztebl. Int.* 110 (2013), 819-826.
13. Dickneite, G, H Herwald, W Korte, et al: Coagulation factor XIII: A multifunctional transglutaminase with clinical potential in a range of conditions. *Thromb. Haemost.* 113 (2015), 686-697.
14. Shigemura, N, T Kawamura, M Minami, et al: Successful factor XIII administration for persistent chylothorax after lung transplantation for lymphangioleiomyomatosis. *Ann. Thorac. Surg.* 88 (2009), 1003-1006.
15. Schroth, M, U Meißner, R Cesnjevar, et al: Recombinant factor XIII reduces severe pleural effusion in children after open-heart surgery. *Pediatr. Cardiol.* 27 (2006), 56-60.
16. Inoue, H, N Nishiyama, S Mizuguchi, et al: Clinical value of exogenous factor XIII for prolonged air leak following pulmonary lobectomy: A case control study. *BMC Surg.* 14 (2014), 109. doi: 10.1186/1471-2482-14-109

Katherina Bernadette Sreter, MD
Department of Clinical Immunology,
Pulmonology and Rheumatology
University Hospital Centre
“Sestre Milosrdnice”
Vinogradska 29, 10000, Zagreb, Croatia
Phone number: +385 1 378 7111
E-mail: ksreter@yahoo.com