

Rapid Decrease in High Titer of Factor VIII Inhibitors upon Immunosuppressive Treatment in Severe Postpartum Acquired Hemophilia A

Pejša, Vlatko; Grgurević, Ivica; Kušec, Rajko; Gaćina, Petar

Source / Izvornik: **Croatian Medical Journal, 2004, 45, 213 - 216**

Journal article, Published version

Rad u časopisu, Objavljena verzija rada (izdavačev PDF)

Permanent link / Trajna poveznica: <https://urn.nsk.hr/urn:nbn:hr:220:082211>

Rights / Prava: [Attribution-NonCommercial-NoDerivatives 4.0 International/Imenovanje-Nekomercijalno-Bez prerada 4.0 međunarodna](#)

Download date / Datum preuzimanja: **2025-01-27**



Repository / Repozitorij:

[Repository of the Sestre milosrdnice University Hospital Center - KBCSM Repository](#)

Rapid Decrease in High Titer of Factor VIII Inhibitors upon Immunosuppressive Treatment in Severe Postpartum Acquired Hemophilia A

Vlatko Pejša, Ivica Grgurević, Rajko Kušec¹, Petar Gačina²

Division of Hematology, Department of Internal Medicine, Dubrava University Hospital; ¹Division of Hematology and Laboratory for Molecular Diagnostics, Department of Internal Medicine, and Institute of Clinical Chemistry, Merkur University Hospital; and ²Division of Hematology, Department of Internal Medicine, Sisters of Mercy University Hospital, Zagreb, Croatia

A 25-year-old woman was diagnosed with acquired hemophilia caused by factor VIII (FVIII) inhibitors two months after normal delivery of her first child. She presented with severe spontaneous bleeding in the right forearm and distal part of the right leg. After venipuncture for diagnostic purposes, severe hematoma developed, affecting the whole left arm and shoulder. The diagnosis of acquired hemophilia was confirmed by the presence of FVIII inhibitors (Bethesda units = 76), low activity of factor VIII (5%), and prolonged activated partial thromboplastin time (APTT = 89 s). The treatment with fresh frozen plasma, cryoprecipitate, red blood cells concentrate, methylprednisolone (3 mg/kg/day for 8 days, then 1 mg/kg/day), and cyclophosphamide (150 mg/day for 5 days, then 100 mg/day) was followed by the regression of hematomas and normalization of APTT and FVIII activity. The titer of FVIII inhibitors rapidly decreased and total disappearance of antibodies was achieved after 15 days. To the best of our knowledge, this is the shortest time to the disappearance of inhibitors to FVIII in postpartum acquired hemophilia ever reported. Transient reappearance of inhibitors occurred 10 months later and also promptly reacted to the same therapy. In the follow-up period of 4 years, the patient had two more pregnancies with no clinical and laboratory signs of illness recurrence. This case indicates important role of immunosuppressive therapy, which can rapidly induce a remission of this rare condition and be life-saving if introduced early in the course of illness and in doses higher than usually recommended.

Key words: autoantibodies; hemophilia A; factor VIII; postpartum hemorrhage

Acquired hemophilia is very rare and dangerous derangement of blood clotting system caused by autoantibodies to factor VIII (FVIII). Antibodies are polyclonal, usually of IgG class 4, rarely class 1 (1-5). They mostly appear among older population either as an isolated disorder (idiopathic acquired hemophilia) or accompanying some other condition, such as collagenosis, lymphoproliferative disorder, solid tumor, pemphigus, pregnancy, or following intake of certain drugs (penicillin, fenitoin, and methyl dopa) (1,6-8). The overall incidence of acquired hemophilia has been estimated to 1 case per 1-4 million population (1-3), of which only 7-11% account for postpartum acquired hemophilia (8,9).

The association between pregnancy and development of inhibitors to FVIII was recognized about 60 years ago (10), and about 100 cases altogether have been reported to date (11). Antibodies may occur in any pregnancy but are observed more often in primagravidas, with diagnosis being confirmed in the period of several days to 3 months after delivery, rarely up to 12 months after delivery or during pregnancy (6,12). In the latter case, the complications of

pregnancy and labor can be expected. Antibodies to FVIII usually do not affect the fetus, and there has been only one reported case of severe intracranial bleeding due to transplacentally transferred antibodies (13). Inhibitors to FVIII disappear spontaneously in 5-30% of patients during a period of few weeks to few months and, in almost all cases during 30 months (2,3,6,7,14). They usually do not reappear in subsequent pregnancies (12,15,16). Nevertheless, there have been cases of prolonged presence of antibodies (12), lasting in one case for 24 years after diagnosis (17). The severity and distribution of bleeding vary but in majority of cases it is moderate-to-severe and sometimes even limb- or life-threatening (1,2,7). According to a few studies including a relatively small number of patients, lethality ranges from 0% to 11% (6,14).

The diagnosis is made by confirming the presence of autoantibodies to FVIII, whose titer can be quantified in Bethesda units (BU), decreased concentration and activity of FVIII, and prolonged activated partial thromboplastin time (APTT).

The goals of treatment are to stop the bleeding and eliminate inhibitory antibodies (1,18). Measures of bleeding control include immobilization, application of cold compresses, avoidance of any surgical intervention or invasive diagnostic procedure, discontinuation of drugs with known inhibitory effect to coagulation system (acetylsalicylic acid and other non-steroid anti-inflammatory drugs), transfusions of red blood cells, plasma, cryoprecipitate, concentrates of human or porcine FVIII, infusions of activated or non-activated prothrombin complex concentrate, concentrate of factor IX and complex of activated factor IX, recombinant factor VII a (rFVIIa) (1,9,18,19). Various treatments can be used to eliminate autoantibodies: corticosteroids, immunosuppressive drugs, plasmapheresis, and immunoglobulines (14,17-21). A novel treatment option is rituximab (monoclonal anti CD20 antibody), reported to be efficacious in the reduction of acquired FVIII inhibitors, although in acquired hemophilia of etiology other than pregnancy (22).

Considering high percentage of spontaneous remission reported and different results of efficiency of immunosuppressive therapy, there are still disagreements about the strategy of therapeutical approach to a bleeding patient in postpartum acquired hemophilia, especially regarding the role and timing of corticosteroids and immunosuppressive agents (12,17).

Our case indicates important role of immunosuppressive therapy in the treatment of postpartum acquired hemophilia. Proper timing and dosage are of utmost importance to achieve a rapid response to this therapy.

Case Report

A 25-year-old previously healthy woman presented with a painful swelling of the right forearm and right wrist that appeared two months after a normal delivery of her first child. The patient was referred to a surgeon who suspected vascular thromboembolic event. However, it was excluded by a Doppler analysis, which instead revealed hematomas in the examined regions. Diagnostic venipuncture of the left cubital vein was performed, causing severe bleeding in the skin, subcutaneous tissue, and muscles of the left arm. Bleeding rapidly progressed, affecting both shoulders and pectoral regions. Radial artery pulsations were hardly palpable. Movements in the shoulders, elbows, and hands were painful and limited. At the same time, spontaneous painful swelling of the right leg appeared. Laboratory analysis showed prolongation of APTT to 89 s, with normal other routine coagulation parameters. After consultation with a hematologist, on the fourth day of disease, the patient was transferred to our Department, where the working diagnosis of postpartum acquired hemophilia was established. A venous line for blood sampling and therapeutic approach was carefully inserted in the dorsal vein of the left feet, which was the only possible approach to peripheral venous circulation. The treatment with methylprednisolone (3 mg/kg/day for the first 8 days followed by a standard dose of 1 mg/kg/day), cyclophosphamide (introduced 3 days af-

ter methylprednisolone in a dose of 150 mg/day for the following 5 days and then reduced to 100 mg/day), fresh frozen plasma (about 600 mL/day for 5 days) and cryoprecipitate (1,300 units daily for 2 days) was started. The diagnosis of postpartum acquired hemophilia was confirmed by the presence of high-titer antibodies to FVIII (76 BU) and very low FVIII activity (5%). Immobilization of the affected limbs was performed, as well as local treatment with cold compresses. Normochromic and normocytic anemia, with hemoglobin of 73 g/L, was corrected by a single transfusion of 610 mL concentrated red blood cells. Lactation was stopped by administering bromocriptin because of painful swelling of both breasts. In spite of abrupt onset of the disease with severe bleedings, very fast cessation of bleeding was achieved after administration of described therapies. There was no need for rFVIIa. Soon, a rapid reduction of the circumference of affected limbs could be observed, whereas hemoglobin concentration steadily increased, with no further need for transfusions of concentrated erythrocytes. Factor VIII activity and APTT gradually returned to normal and antibodies to FVIII continued to decline until total disappearance 15 days after the beginning of treatment, or 19 days after the onset of disease (Fig. 1). The patient was discharged from the hospital after complete normalization of laboratory parameters. The treatment was tapered and finally discontinued during outpatient visits.

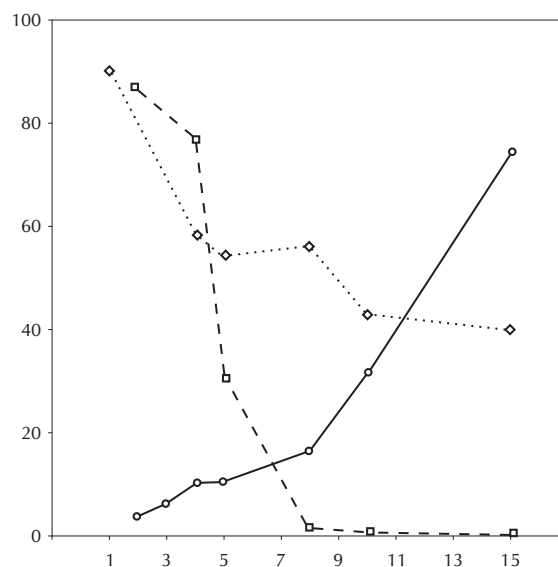


Figure 1. Dynamics of coagulation parameters in our patient. Circles – FVIII (factor VIII in %); squares – anti-FVIII (antibodies to factor VIII in Bethesda Units); rhombs – activated partial thromboplastin time (APTT in seconds).

Four months after discharge, the patient developed decreased activity of FVIII (10%) and slightly prolonged APTT (59.3 s) in the context of minimal clinical signs of bleeding diathesis (few small subcutaneous hematomas of the left arm and leg). Even though the antibodies to factor VIII were negative at that moment, the therapy with methylprednisolone and cyclophosphamide was reinstated. Again, the

regression of clinical signs of bleeding and normalization of laboratory exams was rapid. After six more months, several small subcutaneous hematomas reappeared. Antibodies to FVIII were positive (0.5 BU) and the same treatment was introduced until normalization of clinical picture and laboratory parameters including disappearance of antibodies to FVIII. In the following outpatient checkups, there were no detectable FVIII inhibitors. The patient has had two more normal pregnancies and delivered two healthy children. No clinical or laboratory signs of illness in postpartum period were observed. The last checkup was in April 2003 and there were no clinical signs of bleeding, APTT and FVIII were normal, and antibodies to FVIII negative.

Discussion

This case stresses the importance of prompt recognition of postpartum acquired hemophilia and introduction of corticosteroids and cyclophosphamide in the very beginning of the disease in doses higher than usually recommended. Such approach in our patients produced a good and unexpectedly fast effect of therapy.

Considering very low incidence of postpartum acquired hemophilia, our knowledge on this condition is very limited and based mostly on reports of single cases, as well as retrospective analyses of smaller patient series. The largest study of this condition was that performed by Hauser et al (14), who retrospectively analyzed data of 51 patients reported in the literature during the period of almost 60 years. Besides being very rare, postpartum acquired hemophilia is a disease that can, if not recognized on time and properly treated, lead to a fatal outcome. In several major studies, the lethality ranged from 0% to 11%, and this appeared to be the consequence of different therapeutic regimens (6,12,14).

There are still different opinions regarding the modalities of therapeutic approach in postpartum acquired hemophilia, with major disagreements on the role and validity of immunosuppressive agents (12,17). These controversies originate from the results of some studies in which spontaneous disappearance of antibodies to FVIII was observed in almost 100% of cases during the period of 30 months (6,14). Nevertheless, there is no time to wait for the spontaneous disappearance of inhibitors in a severely bleeding patient, as these antibodies make the pathogenetic basis of this condition.

Hauser et al (14) did not find the use of corticosteroids or immunosuppressive agents to correlate with the overall rate of complete remission. However, it was associated with somewhat shorter time to remission – approximately 8 months – and the lethality was 6% (14). Michiels et al (6,17) concluded that corticosteroids and immunosuppressives had no influence on the course of postpartum acquired hemophilia and therefore no place in the treatment of postpartum acquired hemophilia; they recommended their use in cases of acquired hemophilia of etiologies other than pregnancy. On the other hand, Solymoss (12) recorded no fatal outcome in her study, and ma-

jority of her patients were treated with corticosteroids and/or immunosuppressives. Based on that observation, she concluded that these two groups of drugs had important role and were indicated in the treatment of postpartum acquired hemophilia.

According to the previous reports, it usually takes at least 3 weeks to several months after introduction of immunosuppressive therapy to achieve the disappearance of inhibitory antibodies. Further on, the reported doses of corticosteroids (prednisolone) commonly used were 1 mg/kg/day and cyclophosphamide 100 mg/day. In our case, we started the treatment with methylprednisolone 3 mg/kg/day for the first 8 days and then continued with the recommended dose of 1 mg/kg/day and cyclophosphamide of 150 mg/day for 5 days reducing it thereafter to 100 mg/day. This treatment was followed by a rapid decline of the titer of antibodies to FVIII, which became negative 2 weeks later. To the best of our knowledge, this is the shortest period to the disappearance of antibodies to FVIII ever reported. This may be attributed to early introduction of immunosuppressive treatment or administration of doses higher than usually recommended, or both. Corticosteroids and immunosuppressives proved to be efficient in the treatment of postpartum acquired hemophilia, eliminating the need for the introduction of planned and much more expensive therapy with rFVIIa.

Recently, a case of fatal bleeding caused by high titer of antibodies to FVIII in idiopathic acquired hemophilia resistant to all modalities of treatment currently in use, including rituximab, has been reported by Fischer et al (23). They emphasized the importance of urgent restoration of clotting system early in the course of disease, ie, eradication of high titer of antibodies to FVIII in a bleeding patient, regardless of their possible spontaneous disappearance.

In conclusion, autoimmune etiology must be considered in a case of postpartum hemorrhage. Furthermore, if the diagnosis of acquired hemophilia caused by the high titer of inhibitors to FVIII is confirmed, it should be immediately followed by the treatment targeted to eradication of inhibitory antibodies. If the therapy is postponed, the disease can advance to the point where even the most rigorous treatment may not be successful. The therapy should be introduced without delay, because successful eradication of antibodies can only be achieved in the early phase of illness. Also, corticosteroids and cyclophosphamide, which are much cheaper than other possible modalities of treatment, used in our patient in doses higher than usually recommended, proved to be safe and efficacious treatment of postpartum acquired hemophilia, leading to unexpectedly fast eradication of antibodies and remission of the disease.

Acknowledgment

We thank Prof Dr K. Lechner from the Department of Internal Medicine, University of Vienna, for useful suggestions during the treatment of this patient.

References

- 1 Hay CR. Acquired haemophilia. *Baillieres Clin Haematol.* 1998;11:287-303.
- 2 Margolius A, Jackson DP, Ratnoff OD. Circulating anti-coagulants: a study of 40 cases and a review of the literature. *Medicine (Baltimore).* 1961;40:145-202.
- 3 Lottenberg R, Kentro TB, Kitchens CS. Acquired hemophilia. A natural history study of 16 patients with factor VIII inhibitors receiving little or no therapy. *Arch Intern Med.* 1987;147:1077-81.
- 4 Hoyer LW, Gawryl MS, de la Fuente B. Immunological characterization of factor VIII inhibitors. *Prog Clin Biol Res.* 1984;150:73-85.
- 5 Fulcher CA, de Graaf Mahoney S, Zimmerman TS. FVIII inhibitor IgG subclass and FVIII polypeptide specificity determined by immunoblotting. *Blood.* 1987;69:1475-80.
- 6 Michiels JJ, Bosch LJ, van der Plas PM, Abels J. Factor VIII inhibitor postpartum. *Scand J Haematol.* 1978;20:97-107.
- 7 Green D, Lechner K. A survey of 215 non-hemophilic patients with inhibitors to Factor VIII. *Thromb Haemost.* 1981;45:200-3.
- 8 Hay CR, Negrier C, Ludlam CA. The treatment of bleeding in acquired haemophilia with recombinant factor VIIa: a multicentre study. *Thromb Haemost.* 1997;78:1463-7.
- 9 Morrison AE, Ludlam CA, Kessler C. Use of porcine Factor VIII in the treatment of patients with acquired hemophilia. *Blood.* 1993;81:1513-20.
- 10 Fantl P, Nance MH. An acquired haemorrhagic disease in a female due to an inhibitor of blood coagulation. *Med J Aust.* 1946;2:125-9.
- 11 Shobeiri SA, West EC, Kahn MJ, Nolan TE. Postpartum acquired hemophilia (factor VIII inhibitors): a case report and review of the literature. *Obstet Gynecol Surv.* 2000;55:729-37.
- 12 Solymoss S. Postpartum acquired factor VIII inhibitors: results of a survey. *Am J Hematol.* 1998;59:1-4.
- 13 Ries M, Wolfel D, Maier-Brandt B. Severe intracranial hemorrhage in a newborn infant with transplacental transfer of an acquired factor VIII:C inhibitor. *J Pediatr.* 1995;127:649-50.
- 14 Hauser I, Schneider B, Lechner K. Post-partum factor VIII inhibitors. A review of the literature with special reference to value of steroid and immunosuppressive treatment. *Thromb Haemost.* 1995;73:1-5.
- 15 Kashyap R, Choudhry VP, Mahapatra M, Chumber S, Saxena R, Kaul HL. Postpartum acquired hemophilia: clinical recognition and management. *Haemophilia.* 2001;7:327-30.
- 16 Coller BS, Hultin MB, Hoyer LW, Miller F, Dobbs JV, Dosik MH, et al. Normal pregnancy in a patient with a prior postpartum factor VIII inhibitor: with observations on pathogenesis and prognosis. *Blood.* 1981;58:619-24.
- 17 Michiels JJ, Hamulyak K, Nieuwenhuis HK, Novakova I, van Vliet HH. Acquired hemophilia A in women postpartum: management of bleeding episodes and natural history of the factor VIII inhibitor. *Eur J Haematol.* 1997;59:105-9.
- 18 Bloom AL. Management of factor VIII inhibitors: evolution and current status. *Haemostasis.* 1992;22:268-75.
- 19 Guerin V, Chossat I, Dutronc H, Dubreuil M, Valentin F. Recombinant FVIIa in the treatment of bleeding in acquired hemophilia. *Am J Hematol.* 2002;70:333.
- 20 Green D, Rademaker AW, Briet E. A prospective, randomized trial of prednisone and cyclophosphamide in the treatment of patients with factor VIII autoantibodies. *Thromb Haemost.* 1993;70:753-7.
- 21 Hauser I, Gisslinger H, Locker G, Elbl W, Kyrle PA, Pabinger I, et al. Postpartum Factor VIII inhibitors. Report of two cases with special reference to the efficacy of various treatments. *Wien Klin Wochenschr.* 1993;105:355-8.
- 22 Wiestner A, Cho HJ, Asch AS, Michelis MA, Zeller JA, Peerschke EI, et al. Rituximab in the treatment of acquired factor VIII inhibitors. *Blood.* 2002;100:3426-8.
- 23 Fischer KG, Deschler B, Lubbert M. Acquired high-titer factor VIII inhibitor: fatal bleeding despite multimodal treatment including rituximab preceded by multiple plasmaphereses. *Blood.* 2003;101:3753-4.

Received: June 5, 2003

Accepted: December 1, 2003

Correspondence to:

Vlatko Pejša
Division of Hematology
Department of Internal Medicine
Dubrava University Hospital
Avenija Gojka Šuška 6
10000 Zagreb, Croatia
vpejsa@kbd.hr