

Complete Resolution of Medically Refractory Temporal Lobe Epilepsy after Arachnoid Cyst Fenestration

Sajko, Tomislav; Hećimović, Hrvoje; Borić, Marta; Sesar, Nikolina; Rotim, Krešimir

Source / Izvornik: **Acta clinica Croatica, 2011, 50, 589 - 593**

Journal article, Published version

Rad u časopisu, Objavljena verzija rada (izdavačev PDF)

Permanent link / Trajna poveznica: <https://urn.nsk.hr/urn:nbn:hr:220:596376>

Rights / Prava: [Attribution-NonCommercial-NoDerivatives 4.0 International/Imenovanje-Nekomercijalno-Bez prerada 4.0 međunarodna](#)

Download date / Datum preuzimanja: **2025-01-15**



Repository / Repozitorij:

[Repository of the Sestre milosrdnice University Hospital Center - KBCSM Repository](#)

COMPLETE RESOLUTION OF MEDICALLY REFRACTORY TEMPORAL LOBE EPILEPSY AFTER ARACHNOID CYST FENESTRATION

Tomislav Sajko¹, Hrvoje Hećimović², Marta Borić¹, Nikolina Sesar¹ and Krešimir Rotim¹

¹University Department of Neurosurgery, ²University Department of Neurology, Sestre milosrdnice University Hospital Center, Zagreb, Croatia

SUMMARY – Intracranial arachnoid cysts are congenital lesions that are frequently detected incidentally. About 30% of patients have a symptomatic epileptic seizure as the presenting symptom, occasionally with other focal neurologic signs. A case is presented of a young male patient with medically refractory temporal lobe epilepsy. Following his neurological examination, epileptic zone was defined in the right temporal lobe that correlated with the MRI-detected sylvian arachnoid cyst. Microneurosurgical cyst fenestration with volume reduction was performed, which resulted in a decremental but eventually complete seizure freedom. In conclusion, the arachnoid microsurgical cyst reduction is a safe procedure and may result in complete remission of symptomatic epileptic seizures and favorable outcomes, as reported in other studies.

Key words: Epilepsy, temporal lobe; Arachnoid cysts – surgery

Introduction

Arachnoid cysts are frequently associated with various neurological disorders, including epilepsy. In a study by Passero *et al.*, 26% out of 27 patients presented with seizures^{1,2}. Sylvian and temporal arachnoid cysts represent more than half of intracranial arachnoid cysts³.

Dissociation between structural and functional pathology is particularly present in patients with arachnoid cysts, therefore comprehensive preoperative evaluation is necessary. The optimal method of treatment for symptomatic arachnoid cysts remains controversial and includes cyst shunting, open craniotomy and endoscopic fenestration.

We present a case of a patient with pharmacoresistant temporal lobe seizures, related to the presence

of the sylvian arachnoid cyst, where cyst fenestration resulted in complete resolution of seizures.

Case Report

A 20-year-old male patient presented with medically refractory temporal lobe epilepsy. Neuroradiological examination (multi slice computed tomography (MSCT) and 3T magnetic resonance (MR)) of the brain using epilepsy protocol revealed large right-sided temporal arachnoid cyst compressing the adjacent temporal lobe (Figs. 1A and 1B). In order to determine epileptic region, the patient was referred to an epileptologist. Thorough neurological and seizure history was assessed and 5-day video/EEG continuous monitoring performed. Interictal EEG and ictal onset of 15 stereotypical seizures was recorded. Clinical semiology of seizures also corresponded to the non-dominant (i.e. right) temporal lobe with ictal automatisms followed by ictal laugh.

In general anesthesia, the patient was positioned supine, with a shoulder roll to allow rotation of the

Correspondence to: Tomislav Sajko, MD, PhD, University Department of Neurosurgery, Sestre milosrdnice University Hospital Center, Vinogradska c. 29, HR-10000 Zagreb, Croatia
E-mail: neurosajko@gmail.com

Received September 30, 2010, accepted November 30, 2011

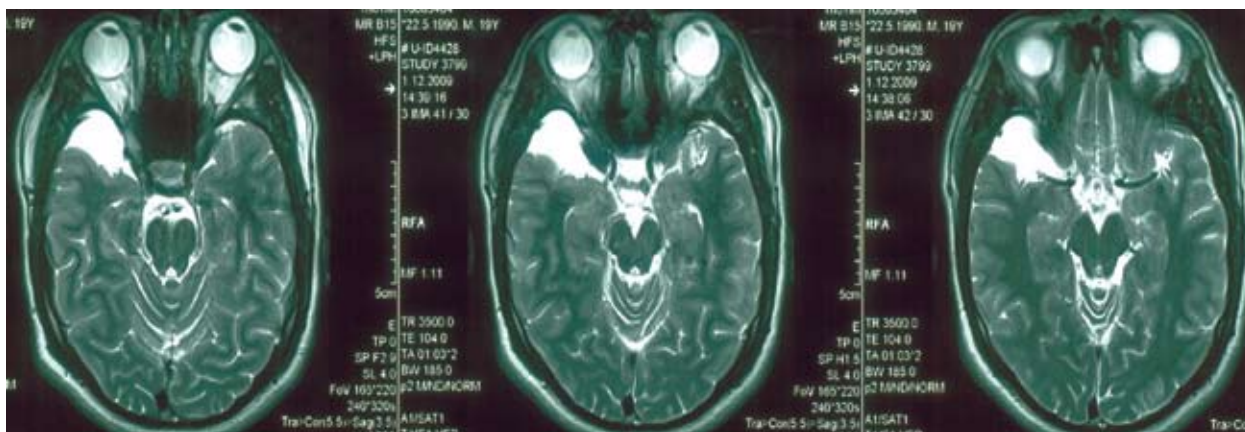


Fig. 1A. Preoperative native axial MR T2-weighted images showing a large right-sided temporal arachnoid cyst compressing the adjacent temporal lobe.

head by 90 degrees away from the side of the lesion. The head was positioned in a Mayfield pin headrest and a small area of hair above the zygoma was shaved. Phenobarbital (5 mg/kg) and cefazolin (1 g) were administered preoperatively. A 5-cm curvilinear incision was made behind the hairline from the root of the zygoma, extending superiorly. A small right frontotemporal (pteryonal) craniotomy measuring 4x4 cm was performed. Upon opening of the dura, the operating microscope was brought into the field.

An arachnoid cyst measuring 6x5 cm was visualized. Upon opening the dense arachnoid membrane of the cyst, the clear cerebrospinal fluid (CSF) was released under pressure. Displacement of the adjacent structures by the cyst provided a wide corridor

through which the deep anatomic structures were observed and accessed without brain retraction.

The arachnoid membrane was extremely dense and multilayered blocking normal CSF circulation toward the insulo-opercular and sphenoidal sylvian fissure compartment. Using microscissors, this dense arachnoid layer was opened and the carotido-optic cistern was visualized. The right optic nerve and carotid artery were identified. The dissection then proceeded to the deeper membranes. Arachnoid membrane adhering to the internal carotid artery and optic nerve was incised. The right posterior communicating artery and right oculomotor nerve were identified and sharply freed from arachnoid membrane. The membrane of Lilliequist was then opened making communication

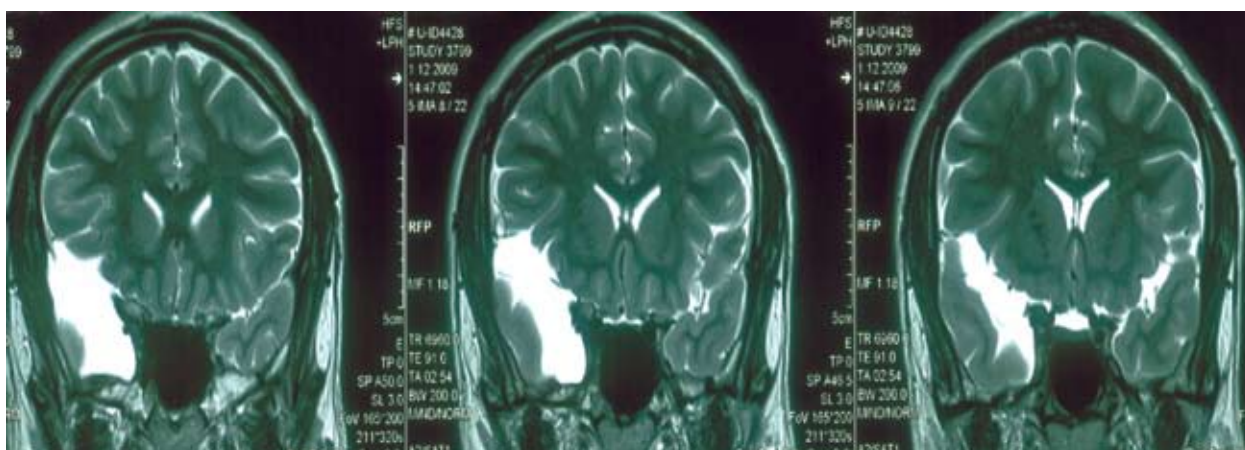


Fig. 1B. Coronal native MR T2-weighted images showing enlargement of the right-sided temporal arachnoid cyst towards the sylvian fissure.

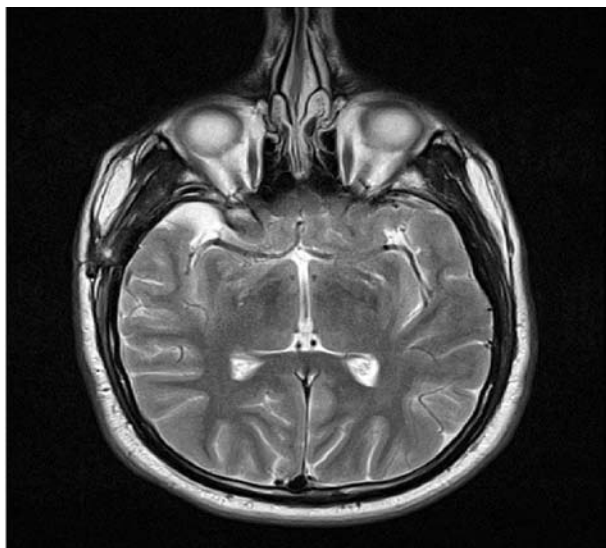


Fig. 2A. Postoperative native axial MR T2-weighted image showing almost complete shrinkage of the arachnoid cyst.

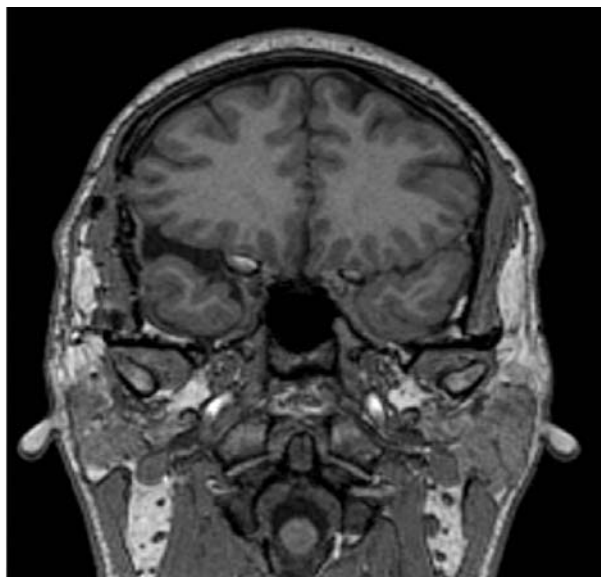


Fig. 2B. Postoperative native coronal MR T1-weighted image shows almost complete volume regain of the right temporal lobe gyri and sulci following arachnoid cyst fenestration.

with the deep basal cisterns. CSF pulsations, demonstrating free communication of the deep cisterns, confirmed successful completion of the procedure.

Postoperative recovery was uneventful. The patient experienced 2 complex partial (CP) seizures on the first postoperative day. On the second postoperative day there were 10 CP attacks, on the third postoperative day 7 CP attacks, and on the remaining days 2-3 CP attacks. The patient was released from the hospital on postoperative day 7 with antiepileptics lamotrigine and valproate. Three weeks after the surgery, his seizures completely stopped and the patient has been seizure free since then. A year and half after the surgery, he is still on a small dose of lamotrigine. His control MR of the brain showed almost complete reduction of the cyst size with no pressure on the surrounding brain tissue (Figs. 2A and 2B).

Discussion

Arachnoid cysts are intra-arachnoid cerebrospinal fluid collections accounting for 1% of all intracranial mass lesions and most frequently seen in the middle cranial fossa. According to Galassi *et al.*, sylvian fissure arachnoid cysts are classified into three

subgroups. Type I cysts are usually asymptomatic and do not require surgical intervention, whereas type II and III cysts may become symptomatic and require a drainage procedure⁴.

Sylvian arachnoid cysts are associated with relatively nonspecific clinical manifestations, such as epileptic seizures, hydrocephalus, and developmental delay⁵⁻¹⁰. In a series of 21 patients with sylvian arachnoid cysts and seizures, Yalcin *et al.* found only five to have seizure types (partial seizures) that could be clinically related to the presence of arachnoid cyst. Repeated EEG recordings further improved the location of the seizure focus demonstrating an association with the arachnoid cyst site in only one case¹¹. Therefore, to better define the epileptic region we performed continuous long-term video/EEG monitoring that recorded interictal activity with 15 stereotypical seizures revealing an epileptic region in the right fronto-temporal area that correlated with the location of the MR detected arachnoid cyst.

The goal of surgical treatment is to eliminate the mass effect on the adjacent structures and the obstructive effect on the normal CSF pathways¹².

The uncertainty of correlation between surgical treatment of sylvian arachnoid cysts and benefits

for epilepsy outcome in patients presenting with seizures has been extensively documented in the literature^{1,11,13,14}.

Koch *et al.* found a correlation between the reduction of cyst size as documented on postoperative neuroradiological examinations and seizure outcome. Sixty out of 76 patients had a reduction in size of their arachnoid cyst, 76.6% of them experiencing seizure improvement. That was the case in our patient, where a dramatic cyst size reduction led to seizure freedom.

The best surgical management of sylvian arachnoid cysts remains controversial. Craniotomy and marsupialization of the cyst walls with the subarachnoid spaces associated or not with removal of the cyst membranes has been traditionally compared with shunting procedures (single pressure, programmable valves)¹⁵⁻²⁴. Some authors also propose a combination of the two procedures²⁵. In more recent series, no significant difference in perioperative morbidity and mortality has been reported when direct and shunting procedures are compared^{8,12,24}. In their survey, Tamburrini *et al.* have demonstrated that direct surgical excision or opening of the cyst linings, once a sylvian fissure cyst has been recognized, is still the favorable approach in a significantly high percentage of patients, especially in the presence of symptoms and signs that might suggest intracranial hypertension.

Pure or assisted endoscopic cyst marsupialization has gained wide attention, but results on its usefulness reported in the literature are controversial^{26,27}.

Based on the best current evidence, we have opted for a microneurosurgical procedure and performed cyst fenestration. We did not decide to perform a shunt procedure due to the possible complications such as shunt infection or shunt dysfunction. In our case, the arachnoid cyst volume reduction resulted in complete cessation of epileptic seizures.

Patients with epilepsy in whom intracranial arachnoid cysts are found should be first examined using EEG and MR procedures. In the cases where the epileptogenic region completely correlates with the arachnoid cyst location, surgical treatment (microsurgical/endoscopic cyst fenestration or cyst shunting) should be offered.

References

1. ARROYO S, SANTAMARIA J. What is the relationship between arachnoid cysts and seizure foci. *Epilepsia* 1997;38:1098-102.
2. PASSERO S, FILOSOMI G, CIONI R, VENTURI C, VOLPINI B. Arachnoid cysts of the middle cranial fossa: a clinical, radiological and follow-up study. *Acta Neurol Scand* 1990;82:94-100.
3. Di ROCCO C. Arachnoid cysts. In: YOUMANS JR, editor. *Neurological surgery*. Philadelphia: Saunders, 1996;967-94.
4. GALASSI E, GAIST G, GIULANI G, POZZATI E. Arachnoid cysts of the middle fossa: experience with 77 cases treated surgically. *Acta Neurochir Suppl (Wien)* 1988;42:201-7.
5. GOSALAKKAL JA. Intracranial arachnoid cysts in children: a review of pathogenesis, clinical features and management. *Pediatr Neurol* 2002;26:93-8.
6. KOCH CA, MOORE JL, VOTH D. Arachnoid cysts: how do postsurgical cyst size and seizure outcome correlate. *Neurosurg Rev* 1998;21:14-22.
7. MAZURKIEWICZ-BELDZINSKA M, DILLING-OSTROWSKA E. Presentation of intracranial arachnoid cysts in children: correlation between localization and clinical symptoms. *Med Sci Monit* 2002;6:462-5.
8. LEVY ML, WANG M, ARYAN HE, YOO K, MELTZER H. Microsurgical keyhole approach for middle fossa arachnoid cyst fenestration. *Neurosurgery* 2005;56(5):E1166.
9. RAO G, ANDERSON RC, FELDSTEIN NA, BROCKMEYER DL. Expansion of arachnoid cysts in children: report of two cases and review of the literature. *J Neurosurg* 2005;102(3 Suppl):314-7.
10. WANG PJ, LIN HC, LIU HM, TSENG CL, SHEN YZ. Intracranial arachnoid cysts in children: related signs and associated anomalies. *Pediatr Neurol* 1998;19:100-4.
11. YALCIN DA, ONCEL C, KAYMAZ A, KUOLU N, FORTA H. Evidence against association between arachnoid cysts and epilepsy. *Epilepsy Res* 2002;49:255-60.
12. KANG JK, LEE KS, LEE IW, JEUN SS, SON CK, JUNG CK, PARK YS, LEE SW. Shunt-independent surgical treatment of middle cranial fossa arachnoid cysts in children. *Childs Nerv Syst* 2000;16:111-6.
13. KAWAMURA T, MORIOKA T, NISHIO S, FUKUI K, YAMASAKI R, MATSUO M. Temporal lobe epilepsy associated with hippocampal sclerosis and a contralateral middle fossa arachnoid cyst. *Seizure* 2002;11:60-2.
14. KOBAYASHI E, BONILHA L, LI LM, CENDES F. Temporal lobe hypogenesis associated with arachnoid cyst in patients with epilepsy. *Arq Neuropsiquiatr* 2003;61(2B):327-9.
15. TAMBURRINI G, del FABBRO M, Di ROCCO C. Sylvian fissure arachnoid cysts: a survey on their diagnostic workout and practical management. *Childs Nerv Syst* 2008;24:593-604.

16. ELHAMMADY MSA, BHATIA S, RAGHEB J. Endoscopic fenestration of middle fossa arachnoid cysts: a technical description and case series. *Pediatr Neurosurg* 2007;43:209-15.
17. MOTOYAMA Y, NABESHIMA S, YAMAZOE N, ISAKA F, HIGUCHI K, SATOW T. Surgical treatment for symptomatic arachnoid cysts. *No Shinkei Geka* 2001;29:217-26. (in Japanese)
18. FEWEL ME, LEVY ML, McCOMB JG. Surgical treatment of 95 children with 102 intracranial arachnoid cysts. *Pediatr Neurosurg* 1996;25:165-73.
19. ARAI H, SATO K, WACHI A, OKUDA O, TAKEDA N. Arachnoid cysts of the middle cranial fossa: experience with 77 patients who were treated with cystoperitoneal shunting. *Neurosurgery* 1996;39:1108-13.
20. HELLAND CA, WESTER K. Arachnoid cysts in adults: longterm follow-up of patients treated with internal shunts to the subdural compartment. *Surg Neurol* 2006;66:56-61.
21. KIM SK, CHO BK, CHUNG YN, KIM HS, WANG KC. Shunt dependency in shunted arachnoid cyst: a reason to avoid shunting. *Pediatr Neurosurg* 2002;37:178-85.
22. LENA G, ERDINCLER P, Van CALENBERGH F, GENITORI L, CHOUX M. Arachnoid cysts of the middle cranial fossa in children. A review of 75 cases, 47 of which have been operated in a comparative study between membranectomy with opening of cisterns and cystoperitoneal shunt. *Neurochirurgie* 1996;42:29-34.
23. OZGUR BM, ARYAN HE, LEVY ML. Microsurgical keyhole middle fossa arachnoid cyst fenestration. *J Clin Neurosci* 2005;12:804-6.
24. PULIDO-RIVAS P, VILLAREJO-ORTEGA FJ, CORDOBÈS-TAPIA F, PASCUAL MARTÍN-GAMERO A, PÉREZ-DÍAZ C. Surgical treatment of arachnoid cysts in children. *Rev Neurol* 2006;42:383-4.
25. MOTTOLESE C, SZATHMARI A, Di SOMMA L, SIMON E, RICCI-FRANCHI AC, CINGUENE C, *et al.* Treatment of arachnoid cysts with endoscopic fenestration and shunting with programmable valve. Our experience. *Childs Nerv Syst* 2007;23:1054-5.
26. PALADINO J, ROTIM K, HEINRICH Z. Neuroendoscopic fenestration of arachnoid cysts. *Minim Invasive Neurosurg* 1998;41:137-40.
27. HOPF N, PERNECZKY A. Endoscopic neurosurgery and endoscope-assisted microneurosurgery for the treatment of intracranial cysts. *Neurosurgery* 1998;43:1330-7.

Sažetak

POTPUNO IŠČEZAVANJE MEDIKAMENTNO TVRDOKORNE EPILEPSIJE TEMPORALNOG REŽNJA NAKON FENESTRACIJE ARAHNOIDNE CISTE

T. Sajko, H. Hećimović, M. Borić, N. Sesar i K. Rotim

Intrakranijske arahnoidne ciste su prirođena oštećenja koja se često otkrivaju slučajno. U oko 30% bolesnika manifestiraju se simptomatskim epileptičnim konvulzijama, ponekad i uz druge žarišne neurološke znakove. Prikazuje se slučaj mladog muškog bolesnika s medicinski refraktornom epilepsijom temporalnog režnja. Nakon neurološkog pregleda epileptična zona je definirana u desnom temporalnom režnju, što je koreliralo s arahnoidnom cistom Sylvianove fisure otkrivenom magnetskom rezonancijom. Izvedena je mikroneurokirurška fenestracija ciste sa smanjenjem volumena, što je rezultiralo ublažavanjem i na kraju potpunim izostankom konvulzija. Zaključuje se kako je mikrokirurško smanjenje ciste siguran zahvat koji može dovesti do potpune remisije simptomatskih epileptičnih napadaja i dobrog ishoda, kao što izvještavaju i autori drugih studija.

Ključne riječi: *Epilepsija, temporalni režanj; Arahnoidne ciste – kirurgija*

