

Malignant transformation of grade II ganglioglioma to glioblastoma: A case report

Čupić, Hrvoje; Sajko, Tomislav; Sesar, Nikolina; Ivica, Mihovil; Pažanin, Leo

Source / Izvornik: **Translational Neuroscience, 2012, 3, 213 - 216**

Journal article, Published version

Rad u časopisu, Objavljena verzija rada (izdavačev PDF)

<https://doi.org/10.2478/s13380-012-0017-x>

Permanent link / Trajna poveznica: <https://urn.nsk.hr/urn:nbn:hr:220:346485>

Rights / Prava: [Attribution-NonCommercial-NoDerivs 3.0 Unported](#) / [Imenovanje-Nekomercijalno-Bez prerada 3.0](#)

Download date / Datum preuzimanja: **2024-11-30**



Repository / Repozitorij:

[Repository of the Sestre milosrdnice University Hospital Center - KBCSM Repository](#)

MALIGNANT TRANSFORMATION OF GRADE II GANGLIOGLIOMA TO GLIOBLASTOMA: A CASE REPORT

Abstract

Gangliogliomas are well differentiated and slowly growing neuroepithelial tumors composed of neoplastic ganglion cells and neoplastic glial cells corresponding mostly to the World Health Organization grade I tumors. However, some of these tumors disclose histologically more malignant glial component and correspond to grade II or grade III tumors. We report a case of left temporal lobe tumor in a 42-year-old woman fulfilling the diagnostic criteria for atypical (grade II) ganglioglioma with high Ki-67 proliferation index and p53 immunoreactive tumor cells. In spite of gross total removal of the tumor, it recurred eight months after surgery. Histopathological examination of the recurrent tumor revealed that it had undergone malignant transformation into a glioblastoma. This case indicates that gangliogliomas with high Ki-67 proliferating index and p53 immunoreactivity should be carefully monitored for recurrence and malignant progression regardless of their morphological grading and seemingly total surgical removal.

Keywords

• Ganglioglioma • Malignant transformation • Glioblastoma

© Versita Sp. z o.o.

Hrvoje Čupić,
Tomislav Sajko,
Nikolina Sesar,
Mihovil Ivica,
Leo Pažanin*

University Hospital Sestre milosrdnice
Zagreb, CROATIA

Received 14 March 2012
accepted 10 May 2012

Case Report

A 42-year-old woman was admitted to the hospital due to headaches and speech disturbances. Magnetic resonance imaging (MRI) of the brain revealed a lesion measuring 2x2 cm, located in the left superior temporal gyrus and compressing the surrounding brain parenchyma (Figure 1a). The surgery was performed and gross total removal of the lesion was achieved. Histopathological analysis revealed a neoplasm composed of synaptophysin and chromogranin A positive dysmorphic, occasionally binuclear, ganglion cells and glial fibrillary acidic protein (GFAP) positive, a slightly hypercellular, astroglial cell component (Figure 2). Tumor cells showed no CD34 or IDH1 immunoreactivity. Lobular growth pattern and perivascular lymphocytic cuffing were also present. The majority of glial tumor cells showed p53 immunoreactivity while Ki-67 proliferative index was focally up to 15%. Up to two mitotic figures per 10 high-power fields (magnification 400x) were noted in the astroglial tumor component, as well. However, no unequivocal signs of anaplasia such as brisk mitotic activity and pseudopalisading necrosis

were observed. These findings were consistent with the diagnosis of atypical (grade II) ganglioglioma. The postoperative multi-slice computed tomography (MSCT) showed no signs of residual tumor (Figure 1b)

Five months after the initial surgery, the patient experienced a seizure and a worsening of the headaches. Control MRI of the brain revealed a recurrent tumor measuring 3x2 cm in the left superior temporal gyrus (Figure 1c). Patient was reoperated on and again gross total removal of the tumor was achieved. Histopathological examination of the recurrent tumor revealed a hypercellular, mitotically active glial tumor (22 mitoses/10 high-power fields, 400x) with pseudopalisading necrosis and microvascular proliferation indicating that the tumor had undergone malignant transformation into a glioblastoma multiforme (WHO grade IV) (Figure 3).

No morphological or immunohistochemical evidence of a neuronal population in the recurrent tumor has been found. Ki-67 proliferative index of the recurrent tumor was up to 60% while p53 immunoreactivity was observed in almost all tumor cells. Tumor cells showed no CD34 or IDH1 immunoreactivity. The postoperative MSCT scan

showed a normal finding with no signs of residual tumor (Figure 1d). However, second recurrence was noted two months later.

Discussion

According to the World Health Organization (WHO) 2007 classification of central nervous system tumors, gangliogliomas are well differentiated and slowly growing neuroepithelial tumors composed of neoplastic ganglion cells and neoplastic glial cells corresponding mostly to the WHO grade I [1]. This classification no longer includes the diagnosis of the atypical WHO grade II ganglioglioma that was earlier applied to tumors with increased cellularity, nuclear pleomorphism, microvascular proliferation and/or increased proliferative activity in the glial cell component but without definitive criteria for anaplasia, such as pseudopalisading necrosis or a brisk mitotic count [2,3]. However, Majores et al. analyzed tumor recurrence and malignant progression in gangliogliomas and claimed that a distinction between the grade II and grade III ganglioglioma provides valuable prognostic information and should be retained [2].

*E-mail: leo.pazanin@gmail.com

Gangliogliomas comprise 0.4%–6.25% of all primary brain tumors in adults and approximately 10% of all primary brain tumors in children [4]. The majority of gangliogliomas arise in the temporal lobe with a long history of intractable seizures being the most frequent clinical manifestation [5]. The WHO grade II and grade III tumors constitute 6–10.3% and 1–5% of all gangliogliomas, respectively [2,3,6]. Recurrence rates for patients with the WHO grade II and III tumors gangliogliomas are 27–33% and 50–60%, respectively [2,3].

We presented a case of a temporal lobe ganglioglioma with rapid progression to glioblastoma. According to diagnostic criteria of Luyken et al. [3] who applied the diagnosis of the grade II ganglioglioma to tumors with features of cellular atypia (i.e. increased cellularity or conspicuous nuclear pleomorphism in glial cell elements), prominent microvascular proliferation, Ki-67 proliferative index >5% and no tumor necrosis, we classified this tumor as the grade II ganglioglioma. Malignant transformation of gangliogliomas to glioblastomas seems to be not as uncommon as is thought [2,3,6,7]. In their series of 203 patients with gangliogliomas Majores et al. [2] observed malignant transformation to glioblastoma in 14% grade II, 20% grade III tumors and 45% of patients who underwent surgery for tumor recurrence.

Little is known about mechanisms of malignant progression of gangliogliomas [8]. Several reports have indicated that radiotherapy resulting in DNA damage may increase the risk of malignant transformation in gangliogliomas [7,9,10]. However, radiotherapy could not explain the malignant transformation in our case as our patient received only surgical treatment. The molecular studies that have been performed on gangliogliomas mainly involve specific genetic alterations commonly associated with more prevalent gliomas [8,11,12]. *TP53* gene mutations were demonstrated during the progression from the WHO grade I to the WHO grade II ganglioglioma which later on progressed to glioblastoma [8] and during the transformation of the WHO grade II ganglioglioma to glioblastoma [11]. The data on the p53 immunoreactivity are not consistent. Hirose et al. [13] found varying

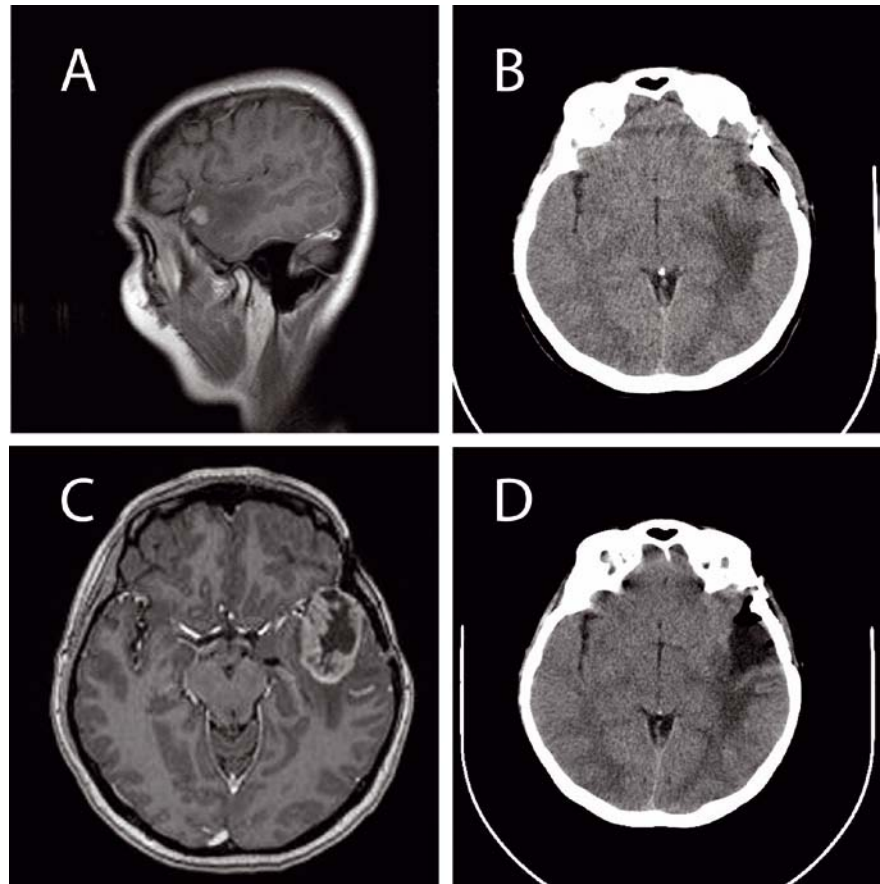


Figure 1. Preoperative magnetic resonance (MR) of the brain. Post-contrast coronal T1-weighted image showing a round tumorous lesion measuring 14x10 mm in the left superior temporal gyrus with surrounding brain edema involving the left superior and middle temporal gyrus. There is a homogenous post-contrast enhancement of a lesion (A). Multi-sliced computed tomography (MSCT) of the brain. Early postoperative native axial image showing the resected area left with no signs of residual tumor. There is an edema of the left temporal and insular area of the brain (B). MR of the brain. Post-contrast axial image showing a tumorous lesion of the left temporal region measuring 4x3 cm. Contrast enhancement of the lesion is inhomogenous with central hypointense necrotic part and peripheral hyperintense ring. There is a marked difference in the appearance of the lesion in comparison with preoperative MR of the brain (C). MSCT of the brain. Postoperative native axial image. The resected area left temporal is now larger, showing no signs of hemorrhage nor of residual tumor. There is a small quantity of air in the operative field and an edema of the left temporal and insular area (D).

numbers (1.2 to 42.4%) of p53 immunoreactive nuclei in 95% of their WHO grade I gangliogliomas while other authors reported no p53 immunoreactivity not only in grade I but in grade II or grade III gangliogliomas as well [3,5,11,12]. However, secondary glioblastomas are reported to be p53 immunoreactive [3,11,12]. The p53 labeling index in recurring gangliogliomas seems to be higher than in nonrecurring ones, as well [13]. The results of these studies indicate that molecular events such as p53 mutations and deletions, which

are involved in malignant progression of diffuse astrocytoma to glioblastoma, might have a role in the malignant transformation of ganglioglioma, as well.

Isocitrate dehydrogenase 1 (*IDH1*) mutations could be identified in the majority of the WHO grades II and III infiltrative gliomas and secondary grade IV glioblastomas. In one multi-institutional study 8.2% gangliogliomas were positive for R132H *IDH1* mutations [14]. The presence of mutant *IDH1* in gangliogliomas in this series correlated with a greater risk of

recurrence and malignant transformation and/or death [14]. However, tumor cells in our case showed no IDH1 immunoreactivity enabling us to exclude diffuse glioma with focal neuronal differentiation as diagnostic possibility.

No systematic examination has been undertaken to determine whether proliferation markers are predictive of more aggressive behavior in patients with gangliogliomas [13]. Hirose et al. [13] showed that Ki-67 proliferative indices in the WHO grade I gangliogliomas range from 0.6 to 10.5%. Wolf et al. [5] observed a correlation between Ki-67 proliferative indices and the WHO histologic grade.

Our original tumor fulfilled the diagnostic criteria for the grade II ganglioglioma but showed high Ki-67 proliferative activity and was p53 immunoreactive. High Ki-67 index and p53 immunoreactivity may indicate more aggressive behavior [13]. The possibility of sampling error must be considered as well. Glial tumors are heterogeneous and there is always a possibility that the malignant, in this case glioblastomatous, component could have been a part of the original lesion that escaped initial surgical resection.

This case indicates that gangliogliomas with high Ki-67 proliferative activity and p53 immunoreactivity should be carefully monitored for recurrence and malignant progression regardless of their morphological grading and seemingly total surgical removal.

Acknowledgement

This work was supported in part by the Ministry of Science, Education and Sports, Croatia, project number 108-1081870-1884 to Božo Krušlin, MD, PhD, Full Prof.

References

- [1] Kleihues P, Cavenee W.K., Pathology and genetics of tumours of the nervous system, IARC Press, Lyon, 2007
- [2] Majores M., von Leche M., Fassunke J., Schramm J., Becker J.A., Simon M., Tumor recurrence and malignant progression of gangliogliomas, *Cancer*, 2008, 113, 3355-3363
- [3] Luyken C., Blumcke I., Fimmers R., Urbach H., Wiestler O.D., Schramm J., Supratentorial gangliogliomas: histopathological grading and tumor recurrence in 184 patients with median follow-up of 8 years, *Cancer*, 2004, 101, 146-155
- [4] Castillo M., Gangliogliomas: ubiquitous or not?, *Am. J. Neuroradiol.*, 1998, 19, 807-809
- [5] Wolf H.K., Muller M.B., Spanle M., Zenther J., Scheramm J., Weistler O.D., Ganglioglioma: a detailed histopathological and immunohistochemical study, *Acta Neuropathol. (Berl.)*, 1994, 88, 166-173
- [6] Blumcke I., Weistler O.D., Gangliogliomas: an intriguing tumor entity associated with focal epilepsies, *J. Neuropathol. Exp. Neurol.*, 2002, 61, 575-584

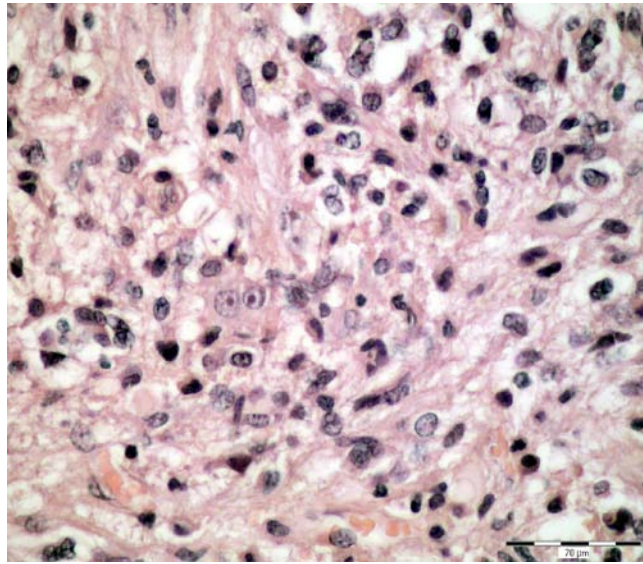


Figure 2. The WHO grade II ganglioglioma showing small binuclear neuronal cell (H-E, scale bar = 70 μ m).

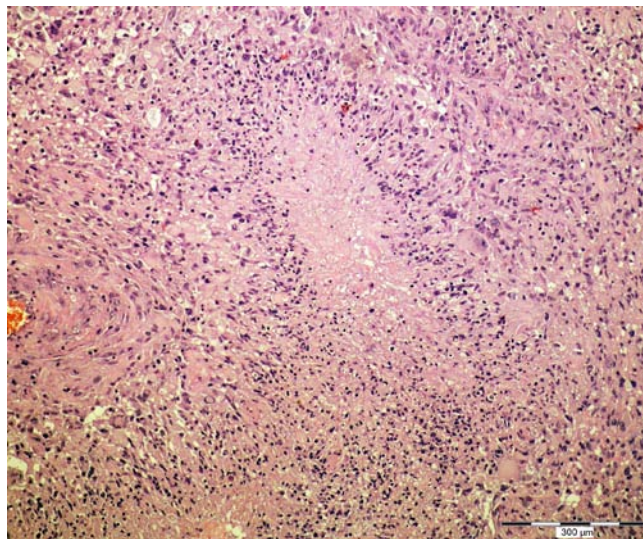


Figure 3. Hypercellular, polymorphic glial tumor showing pseudopalisades (H-E, scale bar = 300 μ m).

- [7] Rumana C.S., Valadka A.B., Radiation therapy and malignant degeneration of benign supratentorial gangliogliomas, *Neurosurgery*, 1998, 42, 1038-1043
- [8] Hayashi Y., Iwato M., Hasegawa M., Tachibana O., von Deimling A., Yamashita J., Malignant transformation of a gangliocytoma/ganglioglioma into a glioblastoma multiforme: a molecular genetic analysis. Case report., *J. Neurosurg.*, 2001, 95, 138-142
- [9] Jay A., Squire J., Becker L.E., Malignant transformation in a ganglioglioma with anaplastic neuronal and astrocytic components. Report of a case with flow cytometric and cytogenetic analysis., *Cancer*, 1994, 73, 2862-2868
- [10] Kalyan-Raman U.P., Olivero W.C., Ganglioglioma: a correlative clinicopathological and radiological study of ten surgically treated cases with follow-up, *Neurosurgery*, 1987, 20, 428-433
- [11] Kim N.R., Wang K.-C., Bang J.-S., Choe G., Park Y., Kim S.-K., et al., Glioblastoma transformation of ganglioglioma: case report with reference to molecular genetic and flow cytometric analysis, *Pathol. Int.*, 2003, 53, 874-882
- [12] Pandita A., Balasubramaniam A., Perrin R., Shannon P., Guha A., Malignant and benign ganglioglioma: a pathological and molecular study, *Neuro Oncol.*, 2007, 9, 124-134
- [13] Hirose T., Kannuki S., Nishida K., Matsumoto K., Sano T. and Hizawa K., Anaplastic ganglioglioma of the brain stem demonstrating active neurosecretory features of neoplastic neuronal cells, *Acta Neuropathol. (Berl.)*, 1992, 83, 365-370