

# Cancer of the ovary, fallopian tube and peritoneum: surgical management

---

**Danolić, Damir; Alvir, Ilija; Mamić, Ivica; Kostić, Lucija; Tomica, Darko;  
Puljiz, Marko; Puljiz, Mario**

*Source / Izvornik:* **Libri Oncologici : Croatian Journal of Oncology, 2015, 43, 41 - 49**

**Journal article, Published version**

**Rad u časopisu, Objavljena verzija rada (izdavačev PDF)**

*Permanent link / Trajna poveznica:* <https://um.nsk.hr/um:nbn:hr:220:194211>

*Rights / Prava:* [Attribution-NonCommercial-NoDerivatives 4.0 International/Imenovanje-Nekomercijalno-Bez prerada 4.0 međunarodna](#)

*Download date / Datum preuzimanja:* **2024-08-20**



*Repository / Repozitorij:*

[Repository of the Sestre milosrdnice University  
Hospital Center - KBCSM Repository](#)

## CANCER OF THE OVARY, FALLOPIAN TUBE AND PERITONEUM: SURGICAL MANAGEMENT

DAMIR DANOLIĆ<sup>1</sup>, ILIJA ALVIR<sup>1</sup>, IVICA MAMIĆ<sup>1</sup>, LUCIJA KOSTIĆ<sup>1</sup>,  
DARKO TOMICA<sup>2</sup>, MARKO PULJIZ<sup>3</sup> and MARIO PULJIZ<sup>1</sup>

<sup>1</sup>Department of Gynecologic Oncology, University Hospital for Tumors,  
University Hospital Centre Sestre milosrdnice, Zagreb, Croatia;

<sup>2</sup>Department of Gynecology and Obstetrics, General Hospital Scheibbs, Scheibbs, Austria;

<sup>3</sup>School of Medicine Split, University of Split, Croatia

---

### Summary

Surgery is the cornerstone of effective management of the ovarian, tubal and peritoneal cancer. In 2014 the International Federation of Gynecology and Obstetrics (FIGO) published a new classification collectively covering cancer of ovary, fallopian tube and peritoneum as well as malignant ovarian germ cell tumors and malignant sex-cord stromal tumors. Comprehensive surgical staging according to the 2014 FIGO classification system plays an important role in management of apparently early stage of ovarian, tubal and peritoneal cancer. Primary debulking (cytoreductive) surgery followed by paclitaxel and platinum based combination chemotherapy is the cornerstone of the advanced-stage disease treatment. In cases of suboptimal primary cytoreduction, interval debulking surgery performed after two to four cycles of chemotherapy based on the clinical judgment of the gynecologic oncologist is second attempt to achieve optimal cytoreduction. Secondary cytoreductive surgery can be considered in patients with platinum-sensitive locally recurrent ovarian cancer. The volume of residual tumor remaining after these surgical approaches is one of the most important independent prognostic factors for survival.

KEY WORDS: *cancer of the ovary, fallopian tube and peritoneum; surgical staging; debulking surgery; residual tumor*

### RAK JAJNIKA, JAJOVODA I POTRBUŠNICE: KIRURŠKO LIJEČENJE

### Sažetak

Kirurško liječenje je temelj uspješnog liječenja raka jajnika, jajovoda i potrbušnice. Međunarodno federacija ginekologa i opstetričara (FIGO) u 2014. godini objavila je novu klasifikaciju koja zajedno obuhvaća rak jajnika, jajovoda, potrbušnice, zloćudne tumore zametnih stanica i zloćudne tumore specijalizirane strome jajnika. Kirurško stupnjevanje bolesti prema FIGO 2014 klasifikaciji je ključno u liječenju raka jajnika, jajovoda i potrbušnice naizgled ranog stadija bolesti. Primarna citoredukcijska kirurgija i dodatno liječenje kemoterapijom je standardni pristup uznapredovaloj bolesti. Prilikom suboptimalne citoredukcije tijekom primarnog kirurškog zahvata "interval debulking surgery" nakon drugog do četvrtog ciklusa kemoterapije, ovisno o procjeni ginekološkog onkologa, drugi je pokušaj postizanja optimalne citoredukcije. Sekundarna citoredukcijska kirurgija dolazi u obzir kod pacijentica koje su osjetljive na kemoterapiju, a imaju lokalni povrat bolesti. Veličina rezidualnog tumorskog tkiva nakon kirurških zahvata je najznačajniji prognostički čimbenik na koji se može utjecati tijekom liječenja.

KLJUČNE RIJEČI: *rak jajnika, jajovoda i potrbušnice; kirurško stupnjevanje; kirurška citoredukcija; rezidualni tumor*

---

## INTRODUCTION

In 2014 the International Federation of Gynecology and Obstetrics (FIGO) published a new classification collectively covering cancer of ovary, fallopian tube and peritoneum as well as malignant ovarian germ cell and malignant sex-cord stromal tumors (Table 1).

Current evidence supports staging all these malignancies in a single system due their similar

Table 1.

THE INTERNATIONAL FEDERATION OF GYNECOLOGY AND OBSTETRICS (FIGO) STAGING CLASSIFICATION FOR CANCER OF THE OVARY, FALLOPIAN TUBE AND PERITONEUM

Stage	Definition
<b>I</b>	<b>Tumor confined to ovaries</b>
IA	Tumor limited to one ovary, capsule intact, no tumor on surface, negative washings
IB	Tumor involves both ovaries, capsule intact, no tumor on surface, negative washings
IC	<i>Tumor limited to one or both ovaries</i>
IC1	Surgical spill
IC2	Capsule rupture before surgery or tumor on ovarian surface
IC3	Malignant cells in the ascites or peritoneal washings
<b>II</b>	<b>Tumor involves one or both ovaries with pelvic extension (below the pelvic brim) or primary peritoneal cancer</b>
IIA	Extension and/or implant on uterus and/or Fallopian tubes
IIB	Extension to other pelvic intraperitoneal tissues
<b>III</b>	<b>Tumor involves one or both ovaries with cytologically or histologically confirmed spread to the peritoneum outside the pelvis and/or metastasis to the retroperitoneal lymph nodes</b>
IIIA	<i>Positive retroperitoneal lymph nodes and /or microscopic metastasis beyond the pelvis</i>
IIIA1	Positive retroperitoneal lymph nodes only
IIIA2	Microscopic, extrapelvic peritoneal involvement ± positive retroperitoneal lymph nodes
IIIB	Macroscopic, extrapelvic, peritoneal metastasis ≤ 2 cm ± positive retroperitoneal lymph nodes. Includes extension to capsule of liver/spleen
IIIC	Macroscopic, extrapelvic, peritoneal metastasis > 2 cm ± positive retroperitoneal lymph nodes. Includes extension to capsule of liver/spleen
<b>IV</b>	<b>Distant metastasis excluding peritoneal metastasis</b>
IVA	Pleural effusion with positive cytology
IVB	Hepatic and/or splenic parenchymal metastasis, metastasis to extraabdominal organs (including inguinal lymph nodes and lymph nodes outside of the abdominal cavity)

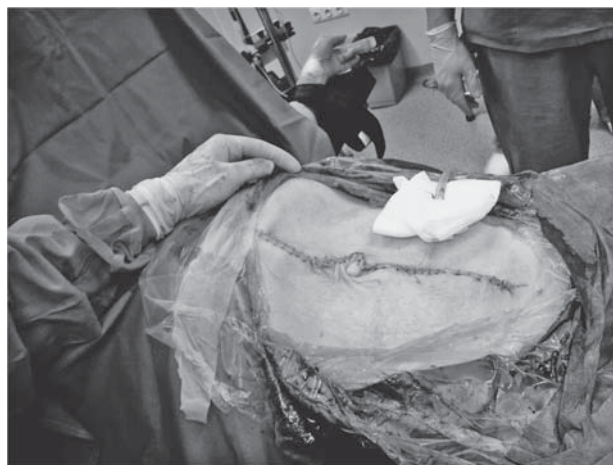

Figure 1. A vertical midline abdominal incision.

pathogenesis, clinical presentation and treatment, despite their differences in histology and clinical behaviour (1). FIGO 2014 staging system provides more accurate prognostic information.

Cancer of the ovary, fallopian tube and peritoneum often requires surgery for diagnosis. The gynecologic oncologist should perform the appropriate surgery (2). An open laparotomy is generally used in patients with a suspected cancer in whom surgical staging, a primary debulking surgery, an interval debulking surgery (IDS) or secondary cytoreduction is planned. A vertical midline abdominal incision should be used (Figure 1).

Diagnostic laparoscopy may be useful when evaluating the resectability of disease in patients with suspected advanced ovarian cancer.

## SURGICAL STAGING

Comprehensive surgical staging according to the 2014 FIGO classification system (Table 1) plays an important role in management of apparently early stage of ovarian, tubal and peritoneal cancer. The primary site should be noted whenever possible. Histologic type including grading should be designated at staging (1). Stage I peritoneal carcinoma is not possible (1).

On entering peritoneal cavity aspiration of ascites or peritoneal washing should be collected and sent for cytologic evaluation. Entire peritoneum surface should be visualized, suspicious areas should be excised and if suspicious areas are not present random biopsies should be taken from the

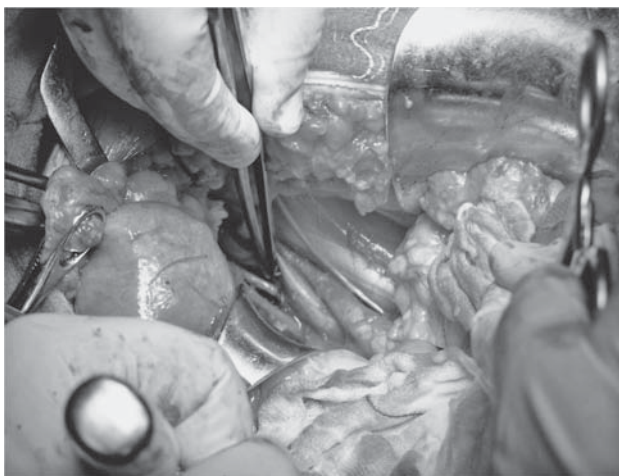

Figure 2. Pelvic lymph node dissection

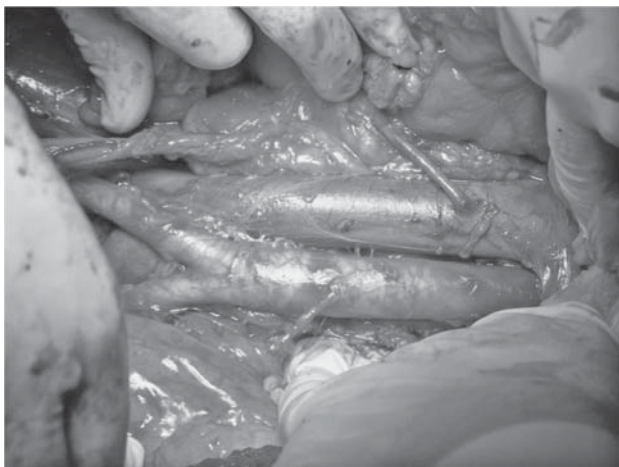


Figure 3. Para-aortic lymph node dissection

pelvis, paracolic gutters, mesentery and diaphragm. Diaphragm scraping for cytologic evaluation is an accepted alternative (3). Omentectomy, total hysterectomy with bilateral salpingo-oophorectomy with effort to avoid intraoperative rupture of an ovarian tumor capsule and pelvic and para-aortic lymphadenectomy is the standard staging procedure. Intraoperative pathologic evaluation is a valuable diagnostic procedure (3). Systematic lymphadenectomy is essential in the accurate staging of apparent early epithelial ovarian cancer (EOC) (4,5). Microscopic lymphatic spread to pelvic lymph nodes is present in 5-14 % and microscopic lymphatic spread to para-aortic lymph is present in 4-12 % of apparent FIGO stage I EOC (5,6,7). Histologic grade and histologic subtype

are the most significant risk factors for lymph node metastases (8,9). Pelvic lymph node dissection (Figure 2) is bilateral and includes removal of lymph nodes overlying and anterolateral to the common iliac vessels, overlying and medial to the external iliac vessels, overlying and medial to the hypogastric vessels and from the obturator fossa (3,10).

Para-aortic lymph node dissection (Figure 3) should be performed to the level of the renal veins (3).

At least 10 lymph nodes should be removed from different retroperitoneal sites (11). Approximately one third of patients with apparent early stage of disease are upstaged during comprehensive surgical staging (12).

The staging system for borderline ovarian tumors (BOTs) is the same as for ovarian, tubal and peritoneal carcinomas. Positive lymph nodes are present in 6.2% patients with BOTs (13). Lesieur et al. (13) performed retrospective study on 1552 patients treated for serous BOTs and concluded that lymph node involvement does not appear as a prognosis factor for advanced-stage of disease. In meta-analysis of 97 studies including 4129 patients with BOTs 98% women with lymph node involvement survived 6.5 years (14). Systematic lymphadenectomy in patients with borderline tumors may be omitted due its low prognostic utility (13,14). Appendectomy is performed for mucinous tumors.

In women with malignant sex-cord stromal tumors (SCST) lymph node metastases are rare (15,16). If there is no palpable nodal enlargement, systematic lymphadenectomy in those patients may also be omitted (15).

Malignant ovarian germ cell tumors (OGCTs) often affect children, adolescents, or young women and approximately one-third of (BOTs) occur in women younger than 40 years of age (17). For patients with apparent early stage of disease and/or good-risk tumors (early stage EOC, BOT, malignant SCST, malignant OGCT) who wish to preserve fertility, fertility-sparing surgery is an option (3).

Comprehensive surgical staging is the most important factor in determining prognosis and selection of appropriate candidates for adjuvant chemotherapy.

Minimally invasive surgical approaches are used by some surgeons for surgical staging of ap-



parent early-stage ovarian, tubal and peritoneal cancer.

### PRIMARY DEBULKING SURGERY

Majority of women with ovarian, tubal, or peritoneal cancer present with advanced-stage disease (FIGO stages III-IV) (18, 19). Primary debulking (cytoreductive) surgery followed by paclitaxel and platinum based combination chemotherapy is the cornerstone of the treatment (20). Surgeons should document the extent of the disease and attempt to achieve maximal tumor debulking. This surgical goal is achieved more often in experienced gynecologic oncology institutions (21, 22, 23). Gynecologic oncologist with abdominal surgeon and/or vascular surgeon and/or thoracic surgeon forms surgical team. The volume of residual tumor remaining after primary cytoreductive surgery is one of the most important independent prognostic factors for survival (19, 21, 24). According to Gynecologic Oncology Group (GOG) cytoreduction to no grossly visible disease defines complete cytoreduction. Cytoreduction with residual disease  $\leq 1$  cm defines optimal cytoreduction and cytoreduction with residual disease  $>1$  cm defines suboptimal cytoreduction (25). Systematic review of 11 retrospective studies showed a greater improvement in progression-free survival (PFS) and overall survival (OS) in women with complete cytoreduction compared with optimal cytoreduction (25). Survival estimates were also statistically significant when optimal cytoreduc-

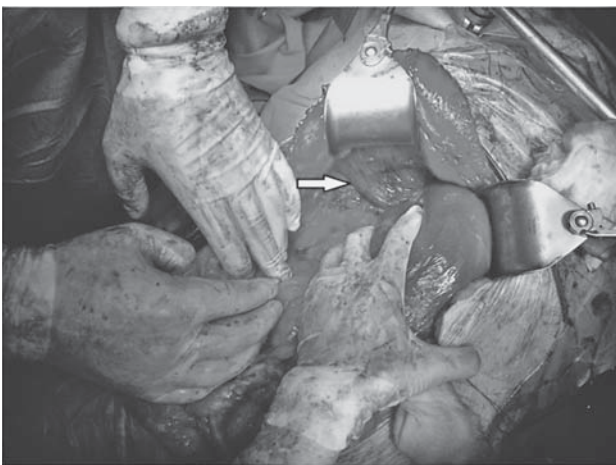


Figure 4. Peritoneal stripping of the diaphragm

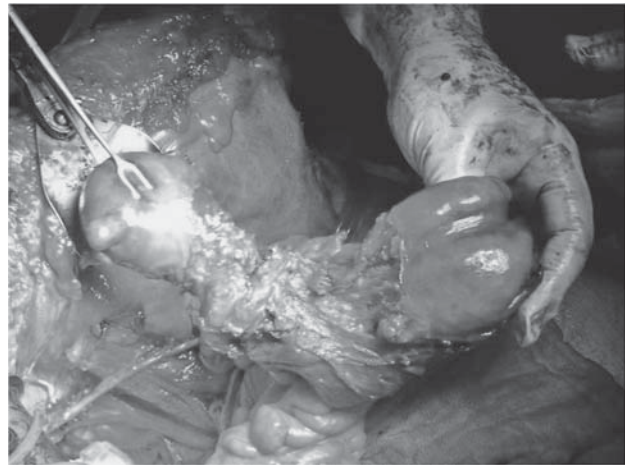

Figure 5. Bowel resection

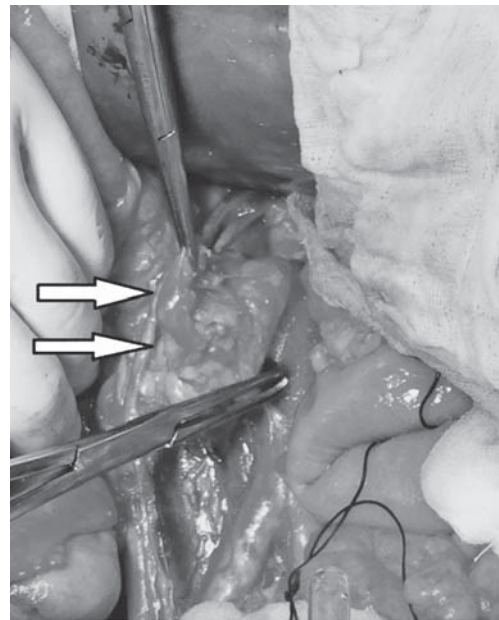


Figure 6. Resection of enlarged lymph node

tion and suboptimal cytoreduction were compared. If complete cytoreduction is not possible, the surgical goal should be optimal cytoreduction (26). There was no improvement in OS when residual disease of  $>2$  cm and  $<2$  cm were compared (25).

During surgical procedure the most difficult areas should be assessed first and if they are unresectable to a diameter  $\leq 1$  cm further cytoreduction is not indicated except for palliation (18,25,26). In these patients ovaries must be resected to prove the origin of tumor. If most difficult areas of the

tumor are resectable aggressive surgical procedure is continued. Methods used to achieve complete cytoreduction are omentectomy, total hysterectomy with bilateral salpingo-oophorectomy, peritoneal stripping of the diaphragm (Figure 4) and abdominopelvic surfaces, bladder or ureteral resection, diaphragmatic resection, bowel resection (Figure 5) and/or appendectomy, gastric resection, liver resection, cholecystectomy, distal pancreatectomy, splenectomy, resection of pulmonary metastases and selective resection of suspicious or enlarged lymph nodes (Figure 6) (3, 26, 27).

Chi et al. (22,28) showed that using extensive upper abdominal surgical procedures resulted in increased optimal cytoreduction rates and significantly improved PFS and OS. Harter et al. (29) showed that the rates of complete cytoreduction in their institution increased from 33% to 62% by implementing aggressive surgical approach with consequent improved OS.

The role of systematic pelvic and para-aortic lymphadenectomy in patients with advanced ovarian cancer is controversial (30,31). National comprehensive cancer network (NCCN) guidelines propose pelvic and para-aortic lymphadenectomy in all patients with macroscopic, extrapelvic, peritoneal metastasis  $\leq 2$  cm in greatest dimension (3). According to previous FIGO staging classification (1988) positive lymph nodes in those patients with apparent FIGO stage IIIB upstage them in FIGO stage IIIC. FIGO (1988) stage IIIC patients with regional lymph node metastasis have better prognosis compared to the patients with FIGO (1988) stage IIIC with macroscopic, extrapelvic, peritoneal metastasis  $>2$  cm (32). In recognition of the prognostic importance of lymph node metastasis the FIGO staging classification was revised (31,32,33). Last versions of FIGO staging classification (2014) defines regional lymph node metastasis as stage IIIA1 and extrapelvic, peritoneal metastasis  $>2$  cm with or without regional lymph node metastasis as stage IIIC (Table 1) (1, 32, 33). There is no need for diagnostic pelvic and para-aortic lymphadenectomy in patients with macroscopic, extrapelvic, peritoneal metastasis  $\leq 2$  cm because positive lymph nodes in those patients do not upstage them. Paik et al. (32) analyzed the prognostic role of revised version of FIGO staging classification in EOC patients and compared it with previous version and found that

revised FIGO staging classification has an independent prognostic role especially in IC3 and IIIC, which were not shown in IC and IIIC of previous FIGO stage.

In 2005, Panici et al. (30) conducted a randomized clinical trial, including 427 patients with FIGO stage IIIB-IV EOC, to determine whether systematic pelvic and para-aortic lymph node dissections improves PFS and OS compared with resection of bulky nodes only. They concluded that systematic lymphadenectomy improves PFS (five to seven months) but not OS in women with optimally debulked advanced ovarian carcinoma (30). According to these findings routine systematic lymphadenectomy is not indicated in women with optimally debulked advanced ovarian carcinoma. In 2010, Kim et al. (34) conducted a meta-analysis including 21,919 patients with EOC and showed that systematic pelvic and para-aortic lymph node dissections improve OS with marginal significance for patients with advanced EOC.

In 2011, Trimbois (11) in the review concluded with the recommendation that lymphadenectomy in advanced ovarian cancer patients can be considered when complete cytoreduction is achieved or when there are bulky nodes. The clinical significance and efficacy of lymphadenectomy in advanced ovarian cancer remains highly controversial. Resection of all grossly suspicious lymph nodes must be done to achieve maximal tumor debulking.

Standard of postoperative care for patients with advanced-stage disease is adjuvant chemotherapy (23).

## INTERVAL DEBULKING SURGERY

It is difficult to predict which patients had disease so extensive that optimal primary cytoreduction could not be achieved (35). Usually it is not possible to evaluate the resectability of tumor until the debulking procedure starts. In cases of suboptimal primary cytoreduction, interval debulking surgery (IDS) is second attempt to achieve optimal cytoreduction. Interval debulking surgery is also reserved for patients who cannot tolerate primary debulking surgery (36). Criteria for primary chemotherapy and IDS are shown in table 2.

Interval debulking surgery is usually performed after two to four cycles of chemotherapy based on the clinical judgment of the gynecologic

Table 2.

CRITERIA FOR PRIMARY CHEMOTHERAPY  
AND INTERVAL DEBULKING SURGERY

Involvement of the superior mesenteric artery
Diffuse deep infiltration of the small bowel mesentery.
Diffuse and confluent carcinomatosis of the stomach and/or large parts of the small or large bowel
Multiple parenchymal liver metastases
Tumor infiltration of the hepatoduodenal ligament, celiac trunk or behind the porta hepatis
Brain metastases
Comorbidity not allowing primary debulking surgery
Patients nonacceptance of potential supportive measures as blood transfusion or temporary stomas

oncologist (3, 35, 37). If there is an evidence of disease progression during chemotherapy, IDS is not performed.

In 1995, Van der Burg et al. (38) assessed the value of IDS among 319 women with advanced-stage disease and concluded that women who underwent IDS after suboptimal primary cytoreduction had significantly longer disease-free survival and a significant six-month prolongation in median survival (26 versus 20 months) compared with women who received chemotherapy alone after suboptimal primary cytoreduction. In this study many patients underwent less aggressive attempts at primary debulking surgery by surgeons who were not experienced gynecologic oncologists.

In 2004, Gynecologic Oncology Group (39) evaluated the effect of IDS on PFS and OS among 550 women with advanced ovarian cancer and suboptimal primary cytoreduction and concluded that addition of IDS to postoperative chemotherapy with paclitaxel plus cisplatin does not improve PFS or OS.

In 2007, Bristow et al. (40) systematically reviewed all investigational studies with evaluable survival data on IDS for ovarian cancer between 1989 and 2006 and concluded that IDS after suboptimal primary cytoreduction does not have an impact on survival outcome. Aggressive primary debulking surgery offers the best opportunity for achieving extended survival and remains the standard procedure in treating women with advanced ovarian cancer (18, 40).

In 2010, European Organization for the Research and Treatment of Cancer 55971 trial showed

similar survival rates of patients with bulky FIGO stage IIIC or IV ovarian carcinoma treated with neoadjuvant chemotherapy and interval debulking surgery (NACT-IDS) or primary debulking surgery and adjuvant chemotherapy (41). No difference in median PFS or OS was found. The perioperative morbidity and mortality were lower after IDS than after primary debulking surgery (41).

In 2013, Tangjitgamol et al (37) in their systematic review did not find strong evidence to support the superiority of IDS over primary debulking surgery in subgroup of women whose primary surgery has been performed by the gynecologic oncologist or with maximal surgical effort, while they found benefit of IDS in the subgroup of women whose primary surgery has not been performed by the gynecologic oncologist or without maximum surgical effort.

In 2015, Bian et al. (42) retrospectively reviewed 339 patients with stage IIIC or IV EOC and showed that NACT-IDS provide equal survival compared with primary debulking surgery and adjuvant chemotherapy.

Despite the benefits of NACT-IDS on perioperative morbidity and mortality and higher rate of optimal cytoreduction, NACT-IDS does not improve survival outcomes compared with standard primary surgery (37, 39, 40, 41). NACT-IDS may be a better alternative treatment option for the group of highly selected women not suitable for primary debulking surgery (37, 43, 44).

Also if optimal primary cytoreduction could not be achieved, especially when primary surgery has not been performed by the gynecologic oncologist or without maximum surgical effort, then NACT-IDS might be beneficial (37, 38, 41, 44).

The volume of residual tumor remaining after IDS is one of the most important independent prognostic factors for survival, as it is after primary debulking surgery (41, 45).

Further well-designed randomised controlled trials will complement our knowledge on benefits of IDS.

## SECONDARY CYTOREDUCTION

Secondary cytoreductive surgery can be considered in patients with platinum-sensitive locally recurrent ovarian cancer (3, 46). The benefits of secondary cytoreductive surgery are not clearly



established because of the lack of large, randomized trials (46, 47). In the DESKTOP I trial only complete resection during secondary cytoreductive surgery for relapsed ovarian cancer was associated with prolonged survival (46). Four independent factors for indicating complete resection were good performance status, early-stage of disease (FIGO stages I/II) at initial diagnosis, complete resection at primary surgery and the absence of ascites (46). A combination of these variables predicts complete resection in 79% of patients (46). Salani et al. (48) evaluate the role of secondary cytoreductive surgery in the outcome of 55 patients who had recurrent EOC and reported improved survival in women with diagnosis-to-recurrence interval  $\geq 18$  months (survival 49 months versus 3 months), improved survival in women with one or two radiographic recurrence sites (survival 50 months versus 12 months for three or more radiographic recurrence sites) and improved survival in women with no macroscopic residual disease (survival 50 months versus 7.2 months for patients with macroscopic residual disease). One or two radiographic recurrence sites define localized recurrent ovarian cancer (48).

Surgical therapy of recurrent disease after secondary cytoreductive surgery may also offer a survival benefit. Size and number of disease implants on preoperative imaging may guide the selection of patients for further cytoreductive surgeries (49, 50). Methods used to achieve complete cytoreduction during secondary cytoreductive surgery are the same as for primary debulking surgery and/or IDS.

## CONCLUSION

Surgery is the cornerstone of effective management of the ovarian, tubal and peritoneal cancer. Complete removal of all visible tumors remains the surgical goal whenever cytoreductive surgery is performed. Gynecologic oncologist should be involved in surgical decision making and treatment, only that guarantees optimal treatment of these patients.

## REFERENCES

1. Prat J; FIGO Committee on Gynecologic Oncology. Staging classification for cancer of the ovary, fallopian tube, and peritoneum. *Int J Gynecol Obstet.* 2014 Jan; 124(1):1-5. doi: 10.1016/j.ijgo.2013.10.001.
2. Giede KC, Kieser K, Dodge J, Rosen B. Who should operate on patients with ovarian cancer? An evidence-based review. *Gynecol Oncol.* 2005;99:447.
3. [http://www.nccn.org/professionals/physician\\_gls/pdf/ovarian.pdf](http://www.nccn.org/professionals/physician_gls/pdf/ovarian.pdf) Accessed on 09.12.2015.
4. Ditto A, Martinelli F, Reato C, Kusamura S, Solima E, Fontanelli R, Haeusler E, Raspagliesi F. Systematic para-aortic and pelvic lymphadenectomy in early stage epithelial ovarian cancer: a prospective study. *Ann Surg Oncol.* 2012;19(12):3849-55. doi: 10.1245/s10434-012-2439-7.
5. Mikami M. Role of lymphadenectomy for ovarian cancer. *J Gynecol Oncol.* 2014;25:279-81. doi: 10.3802/jgo.2014.25.4.279.
6. Suzuki M, Ohwada M, Yamada T, Kohno T, Sekiguchi I, Sato I. Lymph node metastasis in stage I epithelial ovarian cancer. *Gynecol Oncol.* 2000;79(2):305-8.
7. Fournier M, Stoeckle E, Guyon F, Brouste V, Thomas L, MacGrogan G, Floquet A. Lymph node involvement in epithelial ovarian cancer: sites and risk factors in a series of 355 patients. *Int J Gynecol Cancer.* 2009; 19(8):1307-13.
8. Kleppe M, Wang T, Van Gorp T, Slangen BF, Kruse AJ, Kruitwagen RF. Lymph node metastasis in stages I and II ovarian cancer: a review. *Gynecol Oncol.* 2011; 123(3):610-4.
9. Timmers PJ, Zwinderman K, Coens C, Vergote I, Trimpos JB. Lymph node sampling and taking of blind biopsies are important elements of the surgical staging of early ovarian cancer. *Int J Gynecol Cancer.* 2010; 20(7):1142-7.
10. Whitney CW, Spirto N. *Gynecologic Oncology Group Surgical Procedures Manual.* Philadelphia: Gynecologic Oncology Group; 2010.
11. Trimpos JB. Lymphadenectomy in ovarian cancer: standard of care or unnecessary risk. *Curr Opin Oncol.* 2011;23(5):507-11. doi: 10.1097/CCO.0b013e32834847e7.
12. Angioli R, Plotti F, Palaia I, Calcagno M, Montera R, Cafà EV, Sereni MI, Panici PB. Update on lymphadenectomy in early and advanced ovarian cancer. *Curr Opin Obstet Gynecol.* 2008 Feb;20(1):34-9. doi: 10.1097/GCO.0b013e3282f2fd68.
13. Lesieur B, Kane A, Duvillard P, Gouy S, Pautier P, Lhomme C, Morice P, Uzan C. Prognostic value of lymph node involvement in ovarian serous borderline tumors. *Am J Obstet Gynecol.* 2011;204(5):438.e1-7. doi: 10.1016/j.ajog.2010.12.055.
14. Seidman JD, Kurman RJ. Ovarian serous borderline tumors: a critical review of the literature with emphasis on prognostic indicators. *Hum Pathol.* 2000;31(5): 539-57.
15. Brown J, Sood AK, Deavers MT, Milojevic L, Gershenson DM. Patterns of metastasis in sex cord-stromal tu-



- mors of the ovary: can routine staging lymphadenectomy be omitted? *Gynecol Oncol.* 2009;113(1):86-90.
16. Abu-Rustum NR, Restivo A, Ivy J, Soslow R, Sabbatini P, Sonoda Y, Barakat RR, Chi DS. Retroperitoneal nodal metastasis in primary and recurrent granulosa cell tumors of the ovary. *Gynecol Oncol.* 2006;103(1):31-4.
  17. Skírnisdóttir I, Garmo H, Wilander E, Holmberg L. Borderline ovarian tumors in Sweden 1960-2005: trends in incidence and age at diagnosis compared to ovarian cancer. *Int J Cancer.* 2008;123(8):1897-901.
  18. Chang SJ, Bristow RE, Chi DS, Cliby WA. Role of aggressive surgical cytoreduction in advanced ovarian cancer. *J Gynecol Oncol.* 2015 Oct;26(4):336-42. doi: 10.3802/jgo.2015.26.4.336.
  19. McCreath WA, Chi DS. Surgical cytoreduction in ovarian cancer. *Oncology.* 2004 May;18(5):645-53, discussion 653-4, 656, 658.
  20. Vergote I, Amant F, Kristensen G, Ehlen T, Reed NS, Casado A. Primary surgery or neoadjuvant chemotherapy followed by interval debulking surgery in advanced ovarian cancer. *Eur J Cancer.* 2011 Sep;47 Suppl 3:S88-92. doi: 10.1016/S0959-8049(11)70152-6.
  21. Wimberger P, Lehmann N, Kimmig R, Burges A, Meier W, Du Bois A, Arbeitsgemeinschaft Gynaekologische Onkologie Ovarian Cancer Study Group. Prognostic factors for complete debulking in advanced ovarian cancer and its impact on survival. An exploratory analysis of a prospectively randomized phase III study of the Arbeitsgemeinschaft Gynaekologische Onkologie Ovarian Cancer Study Group (AGO-OVAR). *Gynecol Oncol.* 2007;106(1):69-74.
  22. Chi DS, Eisenhauer EL, Zivanovic O, Sonoda Y, Abu-Rustum NR, Levine DA, Guile MW, Bristow RE, Aghajanian C, Barakat RR. Improved progression-free and overall survival in advanced ovarian cancer as a result of a change in surgical paradigm. *Gynecol Oncol.* 2009;114(1):26-31.
  23. Maggioni A, Benedetti Panici P, Dell'Anna T, Landoni F, Lissoni A, Pellegrino A, Rossi RS, Chiari S, Campagnutta E, Greggi S, Angioli R, Mancini N, Calcagno M, Scambia G, Fossati R, Floriani I, Torri V, Grassi R, Mangioni C. Randomised study of systematic lymphadenectomy in patients with epithelial ovarian cancer macroscopically confined to the pelvis. *Br J Cancer.* 2006;95(6):699-704.
  24. Wimberger P, Wehling M, Lehmann N, Kimmig R, Schmalfeldt B, Burges A, Harter P, Pfisterer J, du Bois A. Influence of residual tumor on outcome in ovarian cancer patients with FIGO stage IV disease: an exploratory analysis of the AGO-OVAR (Arbeitsgemeinschaft Gynaekologische Onkologie Ovarian Cancer Study Group). *Ann Surg Oncol.* 2010 Jun;17(6):1642-8. doi: 10.1245/s10434-010-0964-9.
  25. Elattar A, Bryant A, Winter-Roach BA, Hatem M, Naik R. Optimal primary surgical treatment for advanced epithelial ovarian cancer. *Cochrane Database Syst Rev.* 2011 Aug 10;(8):CD007565. doi: 10.1002/14651858.CD007565.pub2.
  26. Chang SJ, Hodeib M, Chang J, Bristow RE. Survival impact of complete cytoreduction to no gross residual disease for advanced-stage ovarian cancer: a meta-analysis. *Gynecol Oncol.* 2013 Sep;130(3):493-8.
  27. Benedetti Panici P, Di Donato V, Fischetti M, Casorelli A, Perniola G, Musella A, Marchetti C, Palaia I, Berloco P, Muzii L. Predictors of postoperative morbidity after cytoreduction for advanced ovarian cancer: Analysis and management of complications in upper abdominal surgery. *Gynecol Oncol.* 2015;137(3):406-11. doi: 10.1016/j.ygyno.2015.03.043.
  28. Chi DS, Franklin CC, Levine DA, Aksefrod F, Sabbatini P, Jarnagin WR, DeMatteo R, Poynor EA, Abu-Rustum NR, Barakat RR. Improved optimal cytoreduction rates for stages IIIC and IV epithelial ovarian, fallopian tube, and primary peritoneal cancer: a change in surgical approach. *Gynecol Oncol.* 2004;94(3):650-4.
  29. Harter P, Muallem ZM, Buhmann C, Lorenz D, Kaub C, Hils R, Kommoss S, Heitz F, Traut A, du Bois A. Impact of a structured quality management program on surgical outcome in primary advanced ovarian cancer. *Gynecol Oncol.* 2011;121(3):615-9. doi:10.1016/j.ygyno.2011.02.014
  30. Panici PB, Maggioni A, Hacker N, Landoni F, Ackermann S, Campagnutta E, Tamussino K, Winter R, Pellegrino A, Greggi S, Angioli R, Mancini N, Scambia G, Dell'Anna T, Fossati R, Floriani I, Rossi RS, Grassi R, Favalli G, Raspagliesi F, Giannarelli D, Martella L, Mangioni C. Systematic aortic and pelvic lymphadenectomy versus resection of bulky nodes only in optimally debulked advanced ovarian cancer: a randomized clinical trial. *J Natl Cancer Inst.* 2005;97(8):560-6.
  31. Gao J, Yang X, Zhang Y. Systematic lymphadenectomy in the treatment of epithelial ovarian cancer: a meta-analysis of multiple epidemiology studies. *Jpn J Clin Oncol.* 2015;45(1):49-60. doi:10.1093/jco/hyu175.
  32. Paik ES, Lee YY, Lee EJ, Choi CH, Kim TJ, Lee JW, Bae DS, Kim BG. Survival analysis of revised 2013 FIGO staging classification of epithelial ovarian cancer and comparison with previous FIGO staging classification. *Obstet Gynecol Sci.* 2015;58(2):124-34. doi: 10.5468/ogs.2015.58.2.124.
  33. Prat J, Belhadj H, Berek J, Bermudez A, Bhatla N, Cain J, Denny L, Fujiwara K, Hacker N, Avall-Lundqvist E, Mutch D, Odicino F, Pecorelli S, Quinn M, Seoud MA, Shrivastava SK; FIGO Committee on Gynecologic Oncology. Abridged republication of FIGO's staging classification for cancer of the ovary, fallopian tube, and peritoneum. *Eur J Gynecol Oncol.* 2015;36(4):367-9.
  34. Kim HS, Ju W, Jee BC, Kim YB, Park NH, Song YS, Kim SC, Kang SB, Kim JW. Systematic lymphadenectomy for survival in epithelial ovarian cancer: a meta-analysis. *Int J Gynecol Cancer.* 2010;20(4):520-8. doi: 10.1111/IGC.0b013e3181d6de1d.
  35. Zheng H, Gao YN. Primary debulking surgery or neoadjuvant chemotherapy followed by interval debulking surgery for patients with advanced ovarian can-

- cer. *Chin J Cancer Res.* 2012;24(4):304-9. doi: 10.3978/j.issn.1000-9604.2012.09.02.
36. Solmaz U, Mat E, Levent Dereli M, Turan V, Peker N, Tosun G, Dogan A, Adiyeye M, Ozdemir A, Gungorduk K, Sancı M, Yildirim Y. Does neoadjuvant chemotherapy plus cytoreductive surgery improve survival rates in patients with advanced epithelial ovarian cancer compared with cytoreductive surgery alone? *J BUON.* 2015;20:580-7.
  37. Tangjitgamol S, Manusirivithaya S, Laopaiboon M, Lumbiganon P, Bryant A. Interval debulking surgery for advanced epithelial ovarian cancer. *Cochrane Database Syst Rev.* 2013;4:CD006014. doi:10.1002/14651858.CD006014.pub6.
  38. van der Burg ME, van Lent M, Buyse M, Kobierska A, Colombo N, Favalli G, Lacave AJ, Nardi M, Renard J, Pecorelli S. The effect of debulking surgery after induction chemotherapy on the prognosis in advanced epithelial ovarian cancer. *Gynecological Cancer Cooperative Group of the European Organization for Research and Treatment of Cancer.* *N Engl J Med.* 1995;332(10):629-34.
  39. Rose PG, Nerenstone S, Brady MF, Clarke-Pearson D, Olt G, Rubin SC, Moore DH, Small JM, Gynecologic Oncology Group. Secondary surgical cytoreduction for advanced ovarian carcinoma. *N Engl J Med.* 2004;351(24):2489-97.
  40. Bristow RE, Eisenhauer EL, Santillan A, Chi DS. Delaying the primary surgical effort for advanced ovarian cancer: a systematic review of neoadjuvant chemotherapy and interval cytoreduction. *Gynecol Oncol.* 2007;104(2):480-90.
  41. Vergote I, Tropé C. G., Amant F., et al. Neoadjuvant chemotherapy or primary surgery in stage IIIC or IV ovarian cancer. *N Engl J Med.* 2010;363:943–53. doi: 10.1056/nejmoa0908806
  42. Bian C, Yao K, Li L, Yi T, Zhao X. Primary debulking surgery vs. neoadjuvant chemotherapy followed by interval debulking surgery for patients with advanced ovarian cancer. *Arch Gynecol Obstet.* 2016 Jan;293(1):163-8. doi: 10.1007/s00404-015-3813-z
  43. Vergote I, Amant F, Kristensen G, Ehlen T, Reed NS, Casado A. Primary surgery or neoadjuvant chemotherapy followed by interval debulking surgery in advanced ovarian cancer. *Eur J Cancer.* 2011;47 Suppl 3:S88-92. doi: 10.1016/S0959-8049(11)70152-6.
  44. Rutten MJ, Sonke GS, Westermann AM, van Driel WJ, Trum JW, Kenter GG, Buist MR. Prognostic value of residual disease after Interval Debulking Surgery for FIGO Stage IIIC and IV epithelial ovarian cancer. *Obstet Gynecol Int.* 2015;2015:464123. doi: 10.1155/2015/464123.
  45. Markauskas A, Mogensen O, dePont Christensen R, Jensen PT. Primary surgery or interval debulking for advanced epithelial ovarian cancer: does it matter? *Int J Gynecol Cancer.* 2014;24:1420-8. doi: 10.1097/IGC.000000000000241.
  46. Harter P, du Bois A, Hahmann M, Hasenburg A, Burges A, Loibl S, Gropp M, Huober J, Fink D, Schröder W, Muenstedt K, Schmalfeldt B, Emons G, Pfisterer J, Wollschlaeger K, Meerpohl HG, Breitbach GP, Tanner B, Sehouli J; Arbeitsgemeinschaft Gynaekologische Onkologie Ovarian Committee; AGO Ovarian Cancer Study Group. Surgery in recurrent ovarian cancer: the Arbeitsgemeinschaft Gynaekologische Onkologie (AGO) DESKTOP OVAR trial. *Ann Surg Oncol.* 2006;13:1702-10.
  47. Park JY, Eom JM, Kim DY, Kim JH, Kim YM, Kim YT, Nam JH. Secondary cytoreductive surgery in the management of platinum-sensitive recurrent epithelial ovarian cancer. *J Surg Oncol.* 2010;101(5):418-24.
  48. Salani R, Santillan A, Zahurak ML, Giuntoli RL 2nd, Gardner GJ, Armstrong DK, Bristow RE. Secondary cytoreductive surgery for localized, recurrent epithelial ovarian cancer: analysis of prognostic factors and survival outcome. *Cancer.* 2007;109(4):685-91.
  49. Leitao MM Jr, Kardos S, Barakat RR, Chi DS. Tertiary cytoreduction in patients with recurrent ovarian carcinoma. *Gynecol Oncol.* 2004;95:181-8.
  50. Shih KK, Chi DS, Barakat RR, Leitao MM Jr. Beyond tertiary cytoreduction in patients with recurrent epithelial ovarian, fallopian tube, or primary peritoneal cancer. *Gynecol Oncol.* 2010;116(3):364-9.

*Author's address: Damir Danolić, Department of Gynecologic Oncology, University Hospital for Tumors, University Hospital Center Sestre milosrdnice, Ilica 197, 10000 Zagreb, Croatia. e-mail: damir.danolic@gmail.com*

