

Spinal Subdural Hematoma Associated with Lumbar Puncture - a Case Report

Paun, Tomislav; Zavoreo, Iris; Jurašić, Miljenka-Jelena; Jadrijević Tomas, Ana; Bašić Kes, Vanja

Source / Izvornik: **Acta clinica Croatica, 2022, 61, 149 - 151**

Journal article, Published version

Rad u časopisu, Objavljena verzija rada (izdavačev PDF)

<https://doi.org/10.20471/acc.2022.61.01.19>

Permanent link / Trajna poveznica: <https://urn.nsk.hr/urn:nbn:hr:220:793001>

Rights / Prava: [In copyright](#)/[Zaštićeno autorskim pravom.](#)

Download date / Datum preuzimanja: **2024-11-26**



Repository / Repozitorij:

[Repository of the Sestre milosrdnice University
Hospital Center - KBCSM Repository](#)



SPINAL SUBDURAL HEMATOMA ASSOCIATED WITH LUMBAR PUNCTURE – A CASE REPORT

Tomislav Paun¹, Iris Zavoreo², Miljenka-Jelena Jurašić², Ana Jadrijević Tomas² and Vanja Bašić Kes²

¹Department of Neurology, Požega General Hospital, Požega, Croatia;

²Department of Neurology, Sestre milosrdnice University Hospital Center, Zagreb, Croatia

SUMMARY – Spinal subdural hematoma caused by lumbar puncture is a rare state of acute blood clot in spinal subdural space, and in some cases, it can be the cause of local compression and consecutive neurological symptoms. We present a 36-year-old female patient who was hospitalized due to persistent headache despite pharmacological therapy. Therefore, we performed lumbar puncture in order to measure intracranial pressure and evaluate cerebrospinal fluid. After lumbar puncture, the patient was complaining of pain in the lumbar region. Emergency magnetic resonance imaging (MRI) of the lumbosacral (LS) region was performed to show acute subdural hematoma of up to 7.3 mm in the dorsal part of the spinal canal at the level of L1 vertebra to the inferior endplate of L4 vertebra. Repeat LS MRI after 3 hours showed unchanged finding. The patient reported gradual regression of pain in the LS region over the next few days, therefore conservative treatment was applied. Patients with a previously known blood clotting disorder and patients on anticoagulation therapy have worse outcome as compared with patients without such disorders. During treatment, it is necessary to monitor patient clinical state and consider the need of surgical treatment.

Key words: *Lumbar puncture; Complications; Subdural hematoma*

Introduction

Lumbar puncture is an important diagnostic procedure in patients with different neurological disorders. It can provide valuable information from the results of cerebrospinal fluid (CSF) analysis and intracranial pressure (ICP) values. Lumbar puncture with appropriate needle insertion in the spinal canal may, however, cause injury to some of the vascular structures. Such vascular injury can lead to development of hematoma, which can be epidural, subdural and subarachnoid. Depending on the size and localization of

subdural hematoma, patient can develop some neurological symptoms due to compression of the medulla and neurovascular structures. It can present as pain in the spinal region, disturbances of sphincter control, and/or different level of motor and sensory deficits¹⁻³.

Case Report

A 36-year-old female patient was hospitalized due to occipital and vertex headache, nausea and occasional vomiting in the past two years. Before hospitalization, the patient had two magnetic resonance imaging (MRI) scans of the brain because of temporary menstrual bleeding disorders and high levels of prolactin. Brain MRI scans indicated the possible presence of hypophyseal microadenoma. Therefore, the patient was also evaluated by an endocrinologist.

Correspondence to: *Assist. Prof. Iris Zavoreo, MD, PhD*, Department of Neurology, Sestre milosrdnice University Hospital Center, Vinogradska c. 29, HR-10000 Zagreb, Croatia
E-mail: iris_zavoreo@yahoo.com

Received November 21, 2016, accepted December 28, 2016

On the first day of hospitalization, lumbar puncture was performed and the results showed normal CSF findings with normal function of the blood-brain barrier and without intrathecal immunoglobulin G (IgG) synthesis (negative oligoclonal bands-type 1). Also, ICP was measured in supine position, showing low values of 3 cmH₂O. After lumbar puncture, the patient started complaining of pain in the lumbosacral (LS) region at the site of lumbar puncture. The pain was spreading to the right leg and gradually became stronger without motor and sensory deficit, while sphincter control was normal. Emergency LS MRI scan was performed to show acute subdural he-

matoma of up to 7.3 mm in T1 sequence, in the dorsal part of the spinal canal at the level of L1 vertebra to the inferior endplate of L4 vertebra (Figs. 1-4). The patient was examined by a neurosurgeon who indicated repeat LS MRI scan after three hours, which showed unchanged result. The next day, the patient was clinically better and pain in the LS region was in regression. Follow up MRI scan performed 24 hours after lumbar puncture showed no changes. During hospital stay, the patient had normal sphincter control without motor and sensory deficit. Laboratory findings were normal, and so were coagulation parameters.

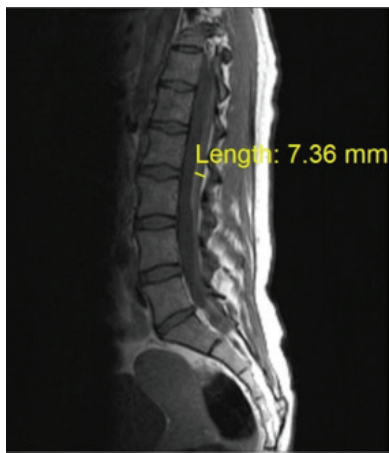

Fig 1. Sagittal T1-weighted LS MRI scan shows acute spinal subdural hematoma from vertebral body L1 to L4.

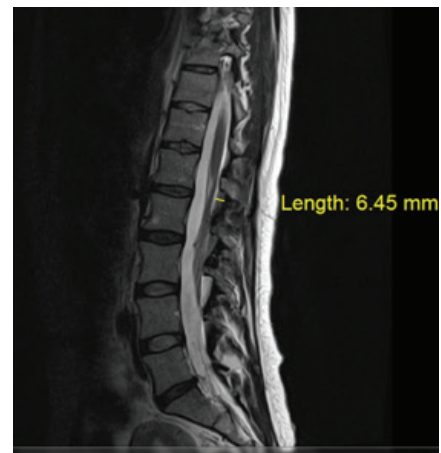


Fig 2. Sagittal T2-weighted LS MRI scan shows acute spinal subdural hematoma from vertebral body L1 to L4.

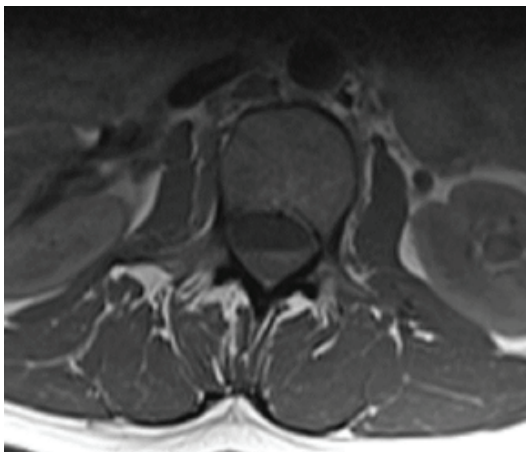


Fig 3. Axial T1-weighted LS MRI scan shows acute spinal subdural hematoma at the level of L2 vertebral body.

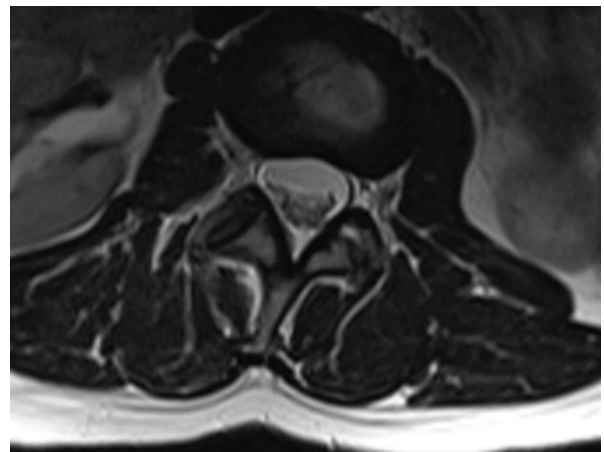


Fig 4. T2-weighted LS MRI scan shows acute spinal subdural hematoma at the level of L2 vertebral body.

Discussion

Spinal subdural hematoma caused by lumbar puncture is a rare but serious condition and it should be considered in the differential diagnosis of post puncture disorders. We present a female patient with strong stabbing pain in the LS region with radicular spread to the right leg without development of other neurological symptoms. In other patients reported in the literature, there was development of progressive motor weakness, presented as paraplegia with sensory deficit in legs and saddle region. In almost all patients, there was dysfunction of sphincter control. In more than half of the patients, there was stabbing pain in the LS region with radicular spread^{1,2}. Brown *et al.* concluded in their study that patients with existing disorder of blood coagulation and spinal hematoma caused by lumbar puncture statistically had poor clinical outcome after 6 to 12 months compared to patients without blood coagulation disorder³. There are literature reports of patients with thrombocytopenia, infection diseases, neoplasms, and pregnancy on anticoagulation and antiaggregation therapy³⁻⁶. Brown *et al.* also showed that there was no statistically significant difference between conservative and surgical treatment, but time to developing symptoms and time to starting treatment may have strong influence on treatment outcome³. Some studies showed that early surgical treatment had better impact on treatment outcome, whereas Qureshi and Sell report that early surgical treatment is not associated with better treatment outcome after one year^{7,8}.

Conclusion

Spinal subdural hematoma caused by lumbar puncture is a rare complication that must be considered on the differential diagnosis of post puncture complications⁹. There is a significant connection with poor treatment outcome in patients with blood coagulation disorder. There are scarce literature data for making recommendation for surgical treatment. Every treatment must be personalized. The patient clinical con-

dition should be followed up, aggressive treatment of blood coagulation disorders introduced, and the need of surgical treatment considered depending on the time and rate of neurological symptom development¹⁰.

References

1. Domenicucci M, Ramieri A, Ciappetta P, Delfini R. Nontraumatic acute spinal subdural hematoma: report of five cases and review of the literature. *J Neurosurg.* 1999;91(1 Suppl):65-73. PMID: 10419371.
2. Kennedy JG, Soffe KE, McGrath A, Stephens MM, Walsh MG, McManus F. Predictors of outcome in cauda equina syndrome. *Eur Spine J.* 1999;8(4):317-22. doi: 10.1007/s005860050180
3. Brown MW, Yilmaz TS, Kasper EM. Iatrogenic spinal hematoma as a complication of lumbar puncture: what is the risk and best management plan? *Surg Neurol Int.* 2016;7(Suppl 22):S581-9. doi: 10.4103/2152-7806.189441
4. Ruff RL, Dougherty JH. Complications of lumbar puncture followed by anticoagulation stroke. 1981;12(6):879-81. doi: 10.1161/01.str.12.6.879
5. Oh SH, Han IB, Koo YH, Kim OJ. Acute spinal subdural hematoma presenting with spontaneously resolving hemiplegia. *J Korean Neurosurg Soc.* 2009;45(6):390-3. doi: 10.3340/jkns.2009.45.6.390
6. Ayerbe J, Quiñones D, Prieto E, Sousa P. Spinal subarachnoid hematoma after lumbar puncture in a patient with leukemia: report of a case and review of the literature *Neurocirugia (Astur).* 2005;16(5):447-52. PMID: 16276453
7. Gurkanlar D, Acikbas C, Cengiz GK, Tuncer R. Lumbar epidural hematoma following lumbar puncture: the role of high dose LMWH and late surgery. A case report. *Neurocirugia (Astur).* 2007;18(1):52-5. doi: 10.1016/s1130-1473(07)70312-3
8. Qureshi A, Sell P. Cauda equina syndrome treated by surgical decompression: the influence of timing on surgical outcome. *Eur Spine J.* 2007;16:2143-51. doi: 10.1007/s00586-007-0491-y
9. Bilić N, Djaković I, Kličan-Jaić K, Sabolović Rudman S, Ivanec Ž. Epidural analgesia in labor – controversies. *Acta Clin Croat.* 2015;54(3):330-6. PMID: 26666104
10. Kennedy JG, Soffe KE, McGrath A, Stephens MM, Walsh MG, McManus F. Predictors of outcome in cauda equina syndrome. *Eur Spine J.* 1999;8(4):317-22. doi: 10.1007/s005860050180

Sažetak

SPINALNI SUBDURALNI HEMATOM POVEZAN S LUMBALNOM PUNKCIJOM – PRIKAZ SLUČAJA

T. Paun, I. Zavoreo, M.-J. Jurašić, A. Jadrijević Tomas i V. Bašić Kes

Spinalni subduralni hematom uzrokovan lumbalnom punkcijom je rijetko stanje akutnog nakupljanja krvi u spinalnom subduralnom prostoru, što u nekim slučajevima može dovesti do kompresivnog učinka i razvoja neurološkog deficita. Prikazujemo bolesnicu u dobi od 36 godina koja je hospitalizirana zbog obrade glavobolja. Učinjena je lumbalna punkcija nakon koje se bolesnica žalila na bol u lumbalnoj kralježnici. Hitno je učinjena magnetska resonancija (MR) lumbalne kralježnice koja je pokazala akutni subduralni hematom od 7,3 mm u dorzalnom dijelu spinalnog kanala od trupa kralješka L1 do donje pokrovne plohe kralješka L4. Ponovljena MR lumbalne kralježnice nakon 3 sata pokazala je nepromijenjen nalaz. Bolesnica je tijekom hospitalizacije cijelo vrijeme urednog neurološkog statusa s postupnom regresijom bolova u lumbalnoj kralježnici te je provedeno konzervativno liječenje. Bolesnici s ranije poznatim poremećajima zgrušavanja krvi i bolesnici na antikoagulantnoj terapiji imaju lošiji ishod liječenja nakon godine dana u odnosu na bolesnike bez poremećaja zgrušavanja krvi. U tijeku liječenja treba pratiti kliničko stanje bolesnika te razmotriti potrebu operativnog liječenja.

Ključne riječi: Lumbalna punkcija; Komplikacije; Subduralni hematom