

Impact of Neurotropic Viruses on Survival of Patients with Surgically Treated Glioblastoma

Koruga, Nenad; Pekmezović, Tatjana; Tomaš, Ilijan; Soldo Koruga, Anamarija; Marjanović, Ksenija; Rajc, Jasmina; Rotim, Ante; Rotim, Krešimir

Source / Izvornik: **Acta clinica Croatica, 2022, 61, 476 - 481**

Journal article, Published version

Rad u časopisu, Objavljena verzija rada (izdavačev PDF)

<https://doi.org/10.20471/acc.2022.61.03.12>

Permanent link / Trajna poveznica: <https://urn.nsk.hr/urn:nbn:hr:220:026625>

Rights / Prava: [Attribution-NonCommercial-NoDerivatives 4.0 International/Imenovanje-Nekomercijalno-Bez prerada 4.0 međunarodna](#)

Download date / Datum preuzimanja: **2024-09-15**



Repository / Repozitorij:

[Repository of the Sestre milosrdnice University Hospital Center - KBCSM Repository](#)



IMPACT OF NEUROTROPIC VIRUSES ON SURVIVAL OF PATIENTS WITH SURGICALLY TREATED GLIOBLASTOMA

Nenad Koruga¹, Tatjana Pekmezović², Ilijan Tomaš³, Anamarija Soldo Koruga⁴, Ksenija Marjanović⁵,
Jasmina Rajc⁵, Ante Rotim⁶ and Krešimir Rotim⁶

¹Department of Neurosurgery, University Hospital Center Osijek, Croatia, Faculty of Medicine, University of J.J. Strossmayer Osijek, Croatia

²Institute of Epidemiology, Faculty of Medicine, University of Belgrade, Serbia

³Department of Oncology, University Hospital Center Osijek, Croatia, Faculty of Medicine, University of J.J. Strossmayer Osijek, Croatia

⁴Department of Neurology, University Hospital Center Osijek, Croatia, Faculty of Medicine, University of J.J. Strossmayer Osijek, Croatia

⁵Department of Pathology, University Hospital Center Osijek, Croatia, Faculty of Medicine, University of J.J. Strossmayer Osijek, Croatia

⁶Department of Neurosurgery, Sestre milosrdnice University Hospital Center, Zagreb, Croatia, Faculty of Medicine, University of Zagreb, Zagreb, Croatia

SUMMARY – Introduction: Glioblastoma represents the most aggressive tumor of the brain with an estimated survival rate of twelve to fifteen months after the primary diagnosis. The role of neurotropic viruses in pathogenesis of the tumor has remained unclear to date. During the last two decades, many studies were conducted with the aim of confirming viral influence in the development of glioblastoma.

Methods: We conducted a retrospective study in a time period of five years using formalin-fixed paraffin-embedded tissues of glioblastoma. Immunohistochemistry was performed for three viruses: CMV, EBV and HSV-1, using an automated staining system.

Results: Mean age of patients in our group was 66.7±8.5 years. A slight male dominance was noted. Negative immunohistochemistry results were obtained for CMV and EBV, which were excluded from further investigation. Based on IRS score, we confirmed six HSV-1 samples which were rated as IRS score 2. Five more samples of HSV-1 were rated as IRS score 1 and were excluded from the study.

Conclusion: According to our retrospective study and its results, we found no impact of neurotropic viruses in the survival rate of glioblastoma. Further studies should be conducted including a wider range of viral detection methods.

Key words: *glioblastoma; brain neoplasms; cytomegalovirus; herpes simplex; antibodies*

Introduction

Glioblastoma (GB) is the most aggressive primary tumor of the brain and the most fatal malignant brain tumor in adults. It represents a surgical challenge due to its aggressive growth and spread along the white

Correspondence to:

Nenad Koruga, MD, University Hospital Center Osijek, Department of Neurosurgery, J. Huttlera 4, 31000 Osijek, Croatia
E-mail: nkoruga@gmail.com

ORCID: 0000-0001-7555-1155

Received May 24, 2021, accepted June 11, 2021

matter tracts. Aggressiveness of tumor is connected to its highly invasive nature, which results in abnormal vascularization and necrosis. The median survival rate after the final diagnosis has been estimated to be 12 to 15 months, despite a variety of therapies available^{1,2}. Additionally, many genetic disorders have been associated with the development of GB, such as Neurofibromatosis type I, Li Fraumeni syndrome and Multiple Endocrine Neoplasia type IIA^{3,4}. Global incidence of glioblastoma is less than 10/100,000, i.e. 3.19/100,000 adults each year in Europe and America^{5,6}.

Factors which determine the outcome of glioblastoma treatment have already been defined, but during the last two decades dozens of studies have been conducted to confirm the influence of neurotropic viruses (NTV) in the development of GB and its survival outcome. The most common viruses associated with the brain tumors are the BK virus (BKV), John Cunningham virus (JCV), polyomaviruses and Simian virus (SV40)⁷⁻⁹. Also, human herpes viruses were recently thoroughly analyzed (10). Nevertheless, potential viral influence associated with tumorigenesis is still controversial. The mechanism of encephalitis caused by herpes simplex virus (HSV) is well-established, as well as its role as an oncolytic virus in tumoral lysis¹⁰. Recent studies of viral influence in the pathogenesis of GB did not confirm its clear role in the development of GB.

Methods

We conducted a retrospective cohort study using a multidisciplinary database for cases of glioblastoma at the University Hospital Center Osijek, Croatia. We evaluated sixty-three patients surgically treated of glioblastoma in a time period of five years, from January 1, 2012 to December 31, 2017. All cases of lower grades of glial tumors according to WHO classification were excluded from the study. Archived formalin-fixed paraffin-embedded GB tissue sections were independently re-evaluated under a microscope (Olympus® CX 40) by two pathologists. The study was approved by the ethics committee of our institution.

Immunohistochemistry

Immunohistochemistry (IHC) staining was performed for three viruses: citomegalovirus (CMV), Epstein-Barr virus (EBV) and herpes simplex virus type I (HSV-1) on formalin-fixed paraffin-embedded

(FFPE) glioblastoma tissue. Seven-micrometer tissue sections were cut for the staining process. All tissue sections were processed according to standardized protocol, and subsequent IHC was performed using an automated Ventana BenchMark (Roche®) staining system following the manufacturer instructions. We used CMV mouse ready-to-use monoclonal antibody (8B1.2, 1G5.2, 2D4.2) - Roche® (Basel, Switzerland), HSV polyclonal ready-to-use antibody (10A3) Dako® (Glostrup, DK-2600, Denmark) and EBV mouse monoclonal ready-to-use antibody (Clones CS. 1-4 - Dako® Glostrup, DK-2600, Denmark). All sections were counterstained with hematoxylin.

Results

The total number of cases included in our study was sixty-three (37 men and 26 women) with an average patient age of 66.7±8.5 years. Immunohistochemistry staining of archived formalin-fixed paraffin-embedded tissues of GB underwent semiquantitative immunoreactive score of Remmele and Stegner (IRS) score evaluation which revealed six HSV-1 positive tissue sections (11%). According to the IRS scoring system, negative results of immunohistochemical staining were obtained for EBV and CMV (IRS 0), which were excluded from further analysis in the study, as well as five HSV-1 specimens evaluated as IRS score 1 (Fig. 1). The Overall survival log-rank test did not reveal statistical significance when comparing HSV-1 positive and HSV-1 negative groups ($p=0.65$) (Fig. 2). Furthermore, a progression-free survival log-rank test comparing the same groups revealed statistical insignificance ($p=0.82$) (Fig. 3).

Statistical analysis

Data were presented as mean±standard deviation or frequencies (%) as appropriate. We calculated the probability of progression-free survival and overall survival using Kaplan-Meier curves.

All values with $p < 0.05$ obtained from the long rank test were considered statistically significant.

Data were analyzed using the SPSS 21.0 software package.

Discussion

Glioblastoma is the most malignant primary brain tumor. Its prognostic factors determine the expected outcome in the treatment of GB, although neurotropic viruses were not included as a possible prognostic

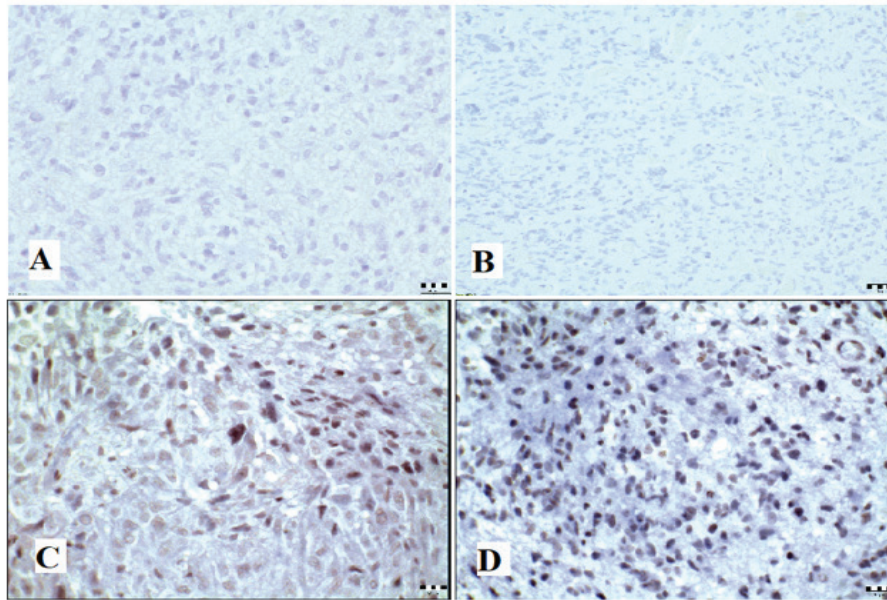


Fig. 1. Representative immunohistochemical stains for the tissue sections of GB, hematoxylin counterstain. All images shown at 400x magnification. Scale bar represents 200 μm. A – negative IHC staining for CMV; B – negative IHC staining for EBV; C – positive IHC staining for HSV-1 (IRS score 1); D – positive IHC staining for HSV-1 (IRS score 2)

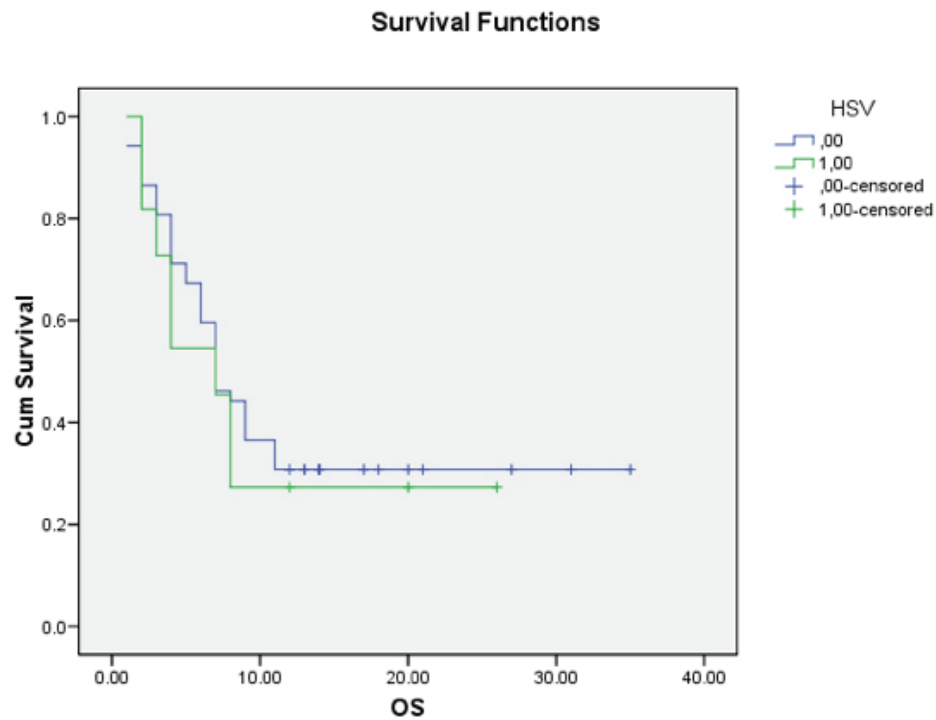


Fig. 2. Kaplan-Meier curves displaying the overall survival of glioblastoma patients with detectable HSV-1.

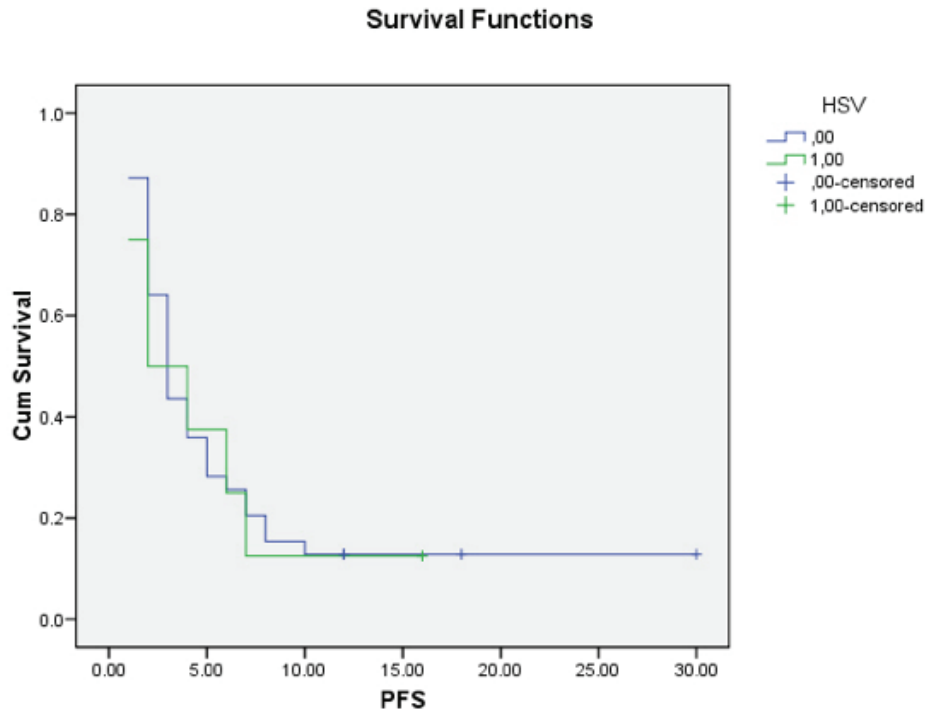


Fig. 3. Kaplan-Meier curves displaying the progression-free survival in glioblastoma patients with detectable HSV-1.

factor. Therefore, the aim of our study was to examine NTV as a prognostic factor in the treatment of GB and analyze its prevalence in the development of GB within our population. Recent studies did not confirm a clear connection between the presence of neurotropic viruses in glioblastoma and their potential mechanism in the development of GB¹¹⁻¹⁴.

Our study included immunohistological staining of CMV, EBV and HSV-1 in FFPE tissue sections of surgically treated GB. The results of our study revealed the complete absence of CMV and EBV. Six FFPE samples of GB were found to be HSV-1 positive according to the IRS scale. Nevertheless, despite its presence, the impact on PFS and OS was not found to be significant. Currently, there is a lack of evidence of the viral presence and its role in the tumorigenesis of GB. Furthermore, many studies have been conducted using several techniques, but their results were insufficient to confirm the theory of viral influence in tumorigenesis^{15,16}. A possible explanation of the viral role is its ability to establish latency in its host resulting in possible viral reactivation, which might lead to its scarce presence in tumor tissue¹⁷.

Human herpesvirus has attracted attention as a possible factor in human brain tumors. A study con-

ducted in Slovenia by Strojnik *et al.* detected three species of herpes viruses in a heterogeneous group of high-grade glioma tissues: HSV-2, Epstein-Barr virus (EBV), HHV-6, and one human enterovirus using the real-time PCR.

Also, low HSV-1 and HSV-2 immunoreactivity were found in five cases in sera of patients, but were not detected in their tumour tissue¹⁸. A similar study was conducted by Wrench *et al.*, where serological IgG ELISA assays were used to present seropositivity for HSV-1 and HSV-2. According to their results, there is no clear evidence that tissue levels or blood levels of HSV indicate possible GB tumorigenesis¹⁹.

The aim of recent studies was focused mainly on CMV which is a member of the Herpesviridae family, carried by 70-100% of population, depending on the geographic region. CMV, as a member of the Herpesviridae family, is carried by 70-100% of population, depending on the geographic region. EBV is present in more than 90% of the adult population, and HSV-1 is present in approximately of 67% of the population²⁰⁻²². The advantage of our study was the homogeneous tumor sample of sixty-three patients with GB²⁹. The main disadvantages of our retrospective study were the application of only one technique and the inability

to perform sera testing. Other studies have not confirmed HSV-1 in tumor tissue sections despite their advantage of a considerably wider range of real-time testing techniques¹⁸. Therefore, we were unable to fully compare our results to other studies. Nevertheless, we have to emphasize that our study included the largest amount of positive HSV-1 tumor tissues. This result may be explained by geographic predilection and high seropositivity within our population. We can conclude that further studies should be designed to confirm HSV-1 seropositivity in surgically treated patients.

The role of neurotropic viruses in CNS diseases has not yet been clearly defined despite the capability of NTV to reach and infect the CNS, which is increased by the fact that HSV-1 establishes latency in trigeminal ganglia²³. A wide variety of symptoms may be present, such as encephalitis, meningitis, flaccid paralysis, etc.^{24,25}. Our study excluded the presence of CMV and EBV, but the presence of HSV-1 might indicate possible viral seropositivity within our population and perioperative viral activation. The most commonly presented radiographic finding of CNS infection refers to HSV encephalitis (HSE). HSE usually presents as edema, hemorrhage or necrosis affecting the frontal and the temporal lobe of the brain, as well as the limbic system²⁶. In addition to its latency, viral breakthrough may occur by two possible routes: the bloodstream and peripheral neurons^{27,28}. The aggressive nature of GB may lead to the disruption of the blood-brain barrier, which facilitates viral spreading within tumor and peritumoral tissue. Due to its behavior, there is a need to further examine its activation path and viral spreading.

According to our results, we can conclude that HSV-1 had no impact on survival rate in our group of patients. The role of NTV in pathogenesis of GB is yet to be determined, but the nature of neurotropic viruses implicates its activation in immunocompromised patients. It is necessary to design future studies in our country by implementing a wider range of methods.

Conflict of interests: None.

References

- Aliferis C, Trafalis DT. Glioblastoma multiforme: Pathogenesis and treatment. *Pharmacol Ther.* 2015;152:63-82.
- Omuro A, De Angelis LM. Glioblastoma and other malignant gliomas: a clinical review. *J Am Med Assoc.* 2013;310:1842-50.
- Sánchez-Ortiga R, Boix Carreño E, Moreno-Pérez O, et al. Glioblastoma multiforme and multiple endocrine neoplastic type 2 A. *Med Clin (Barc).* 2009;133:196-7.
- Broekman ML, Risselada R, Engelen-Lee J, et al. Glioblastoma multiforme in the posterior Cranial fossa in a patient with neurofibromatosis type I. *Case Report Med.* 2009;2009:757898. doi: 10.1155/2009/757898
- Thakkar JP, Dolecek TA, Horbinski C, et al. Epidemiologic and molecular prognostic review of Glioblastoma. *Cancer Epidemiol Biomarkers Prev.* 2014;23:1985-96.
- Ohgaki H, Kleihues P. Epidemiology and etiology of gliomas. *Acta Neuropathol* 2005;109:93-108.
- Del Valle L, Gordon J, Assimakopoulou M, Enam S, Geddes JF, Varakis JN, Katsetos CD, Croul S, Khalili K. Detection of JC virus DNA sequences and expression of the viral regulatory protein T-antigen in tumours of the central nervous system. *Cancer Res.* 2001;61:4287-93.
- Piña-Oviedo S, De León-Bojorge B, Cuesta-Mejías T, White MK, Ortiz-Hidalgo C, Khalili K, Del Valle L. Glioblastoma multiforme with small cell neuronal-like component: association with human neurotropic JC virus. *Acta Neuropathol.* 2006;111:388-96.
- Mazzoni E, Gerosa M, Lupidi F, Corallini A, Taronna AP, D'Agostino A, Bovenzi M, Ruggeri G, Casali F, Rotondo JC, Rezza G, Barbanti-Brodano G, Tognon M, Martini F. Significant prevalence of antibodies reacting with simian virus 40 mimotopes in sera from patients affected by glioblastoma multiforme. *Neuro-Oncol.* 2014;16:513-9.
- Todo T, Tanaka M, Ito M, Ito H, Ino Y. Clinical trials of a third-generation recombinant oncolytic HSV-1 in recurrent glioblastoma and olfactory neuroblastoma patients. *Neuro-Oncology.* 2014;16(Suppl. 3):III51-III51.
- Cobbs CS, Harkins L, Samanta M, et al. Human cytomegalovirus infection and expression in human malignant glioma. *Cancer Res.* 2002;62:3347-50.
- Scheurer ME, Bondy ML, Aldape KD, et al. Detection of human cytomegalovirus in different histological types of gliomas. *Acta Neuropathol.* 2008;116:79-86.
- Yamashita Y, Ito Y, Isomura H, et al. Lack of presence of the human cytomegalovirus in human glioblastoma. *Mod Pathol.* 2014;27:922-9.
- Ranganathan P, Clark PA, Kuo JS, et al. Significant association of multiple human cytomegalovirus genomic loci with glioblastoma multiforme samples. *J Virol.* 2012;86:854-64.
- Lau SK, Chen YY, Chen WG, et al. Lack of association of cytomegalovirus with human brain tumors. *Mod Pathol.* 2005;18:838-43.
- Holdhoff M, Guner G, Rodriguez FJ, et al. Absence of cytomegalovirus in glioblastoma and other high-grade gliomas by real-time PCR, immunohistochemistry, and in situ hybridization. *Clin Cancer Res.* 2017;23(12):3150-7. doi: 10.1158/1078-0432.CCR-16-1490.
- Tang KW, Hellstrand K, Larsson E. Absence of cytomegalovirus in highcoverage DNA sequencing of human glioblastoma multiforme. *Int J Cancer.* 2015;136:977-81.
- Strojnik T, Duh D, Lah TT. Prevalence of neurotropic viruses in malignant glioma and their onco-modulatory potential. *In Vivo.* 2017;31:221-9. doi:10.21873/in vivo.11049
- Wrensch M, Weinberg A, Wiencke J, Miike R, Barger G, Kelsey K. Prevalence of antibodies to four herpesviruses among adults with glioma and controls. *Am J Epidemiol.* 2001;154:161-5.

20. Cannon MJ, Schmid DS, Hyde TB. Review of cytomegalovirus seroprevalence and demographic characteristics associated with infection. *Rev Med Virol.* 2010;20:202-13.
21. Niedobitek G, Meru N, Delecluse HJ. Epstein-Barr virus infection and human malignancies. *Int J Exp Pathol.* 2001;82:149-70.
22. Looker KJ, Magaret AS, Turner KM, Vickerman P, Gottlieb SL, Newman LM. Global estimates of prevalent and incident herpes simplex virus type 2 infections in 2012. *PLoS ONE.* 2015;10:e114989.
23. Roizman B, Zhou G, Du T. Checkpoints in productive and latent infections with herpes simplex virus 1: conceptualization of the issues. *J Neurovirol.* 2011;17:512-7. doi:10.1007/s13365-011-0058-x
24. Libbey JE, Cusick MF, Fujinami RS. Role of pathogens in multiple sclerosis. *Int Rev Immunol.* 2014;33:266-83.
25. Bello-Morales R, Andreu S, López-Guerrero JA. The role of herpes simplex virus type 1 infection in demyelination of the central nervous system. *Int J Mol Sci.* 2020;21:5026.
26. Shivkumar M, Milho R, May JS, Nicoll MP, Efstathiou S, Stevenson PG. Herpes Simplex Virus 1 Targets the Murine Olfactory Neuroepithelium for Host Entry. *J Virol.* 2013;87:10477-88.
27. Dando SJ, Mackay-Sim A, Norton RE, Currie BJ, John JS, Ekberg JA, Batzloff M, Ulett GC, Beacham IR. Pathogens Penetrating the Central Nervous System: Infection Pathways and the Cellular and Molecular Mechanisms of Invasion. *Clin Microbiol Rev.* 2014;27:691-726.
28. Swanson P, McGavern DB. Portals of Viral Entry into the Central Nervous System. In *The Blood Brain Barrier in Health and Disease Volume 2: Pathophysiology and Pathology*; Dorovini-Zis K, Ed.; CRC Press: Boca Raton, FL, USA, 2015; Volume 2.
29. Koruga, N., Pekmezović, T., Tomaš, I., Soldo Koruga, A., Butković Soldo, S., Užarević, Z. i Rotim, K. (2021). Factors Affecting Outcome in the Treatment of Glioblastoma. *Acta clinica Croatica*, 60. (3.), 373-378. <https://doi.org/10.20471/acc.2021.60.03.06>

Sažetak

UTJECAJ NEUROTROPNIH VIRUSA NA PREŽIVLJENJE PACIJENATA OPERIRANIH OD GLIOBLASTOMA

N. Koruga, T. Pekmezović, I. Tomaš, A. Soldo Koruga, K. Marjanović, J. Rajc, A. Rotim i K. Rotim

Uvod: Glioblastom predstavlja najagresivniji tumor mozga s procijenjenom stopom preživljenja od dvanaest do petnaest mjeseci nakon primarne dijagnoze. Uloga neurotropskih virusa u patogenezi tumora do danas je nejasna. Tijekom posljednja dva desetljeća provedena su mnoga istraživanja s ciljem potvrde utjecaja virusa na razvoj glioblastoma.

Metode: Provedena je retrospektivna studija u vremenskom razdoblju od pet godina. Korištena su arhivska tkiva glioblastoma uklopljena u parafin. Imunohistokemija je rađena za tri virusa: CMV, EBV i HSV-1 pomoću automatiziranog sustava bojenja.

Rezultati: Prosječna dob bolesnika u našoj skupini bila je $66,7 \pm 8,5$ godina. Zabilježena je blaža predominacija oboljelih muškaraca. Dobiveni su negativni imunohistokemijski rezultati za CMV i EBV koji su isključeni iz daljnjeg ispitivanja. Prema IRS procjeni potvrdili smo šest uzoraka HSV-1 koji su ocijenjeni kao IRS 2. Još pet uzoraka HSV-1 ocijenjeno je kao IRS 1 i izuzeti su iz studije.

Zaključak: Prema našoj retrospektivnoj studiji i posljedičnim rezultatima, nismo pronašli utjecaj neurotropskih virusa na stopu preživljenja u oboljelih od glioblastoma, no potrebna su daljnja istraživanja koja uključuju širi spektar metoda dokazivanja virusa.

Ključne riječi: *glioblastom, tumori mozga, citomegalovirus, herpes simplex, protutijela*