

Microsurgical Management of Low-Grade Spinal Cord Astrocytoma in Adults: a Personal Case Series Report and Brief Literature Review

Pojskić, Mirza; Rotim, Krešimir; Splavski, Bruno; I. Arnautović, Kenan

Source / Izvornik: *Acta clinica Croatica*, 2020, 59, 505 - 512

Journal article, Published version

Rad u časopisu, Objavljena verzija rada (izdavačev PDF)

<https://doi.org/10.20471/acc.2020.59.03.15>

Permanent link / Trajna poveznica: <https://um.nsk.hr/um:nbn:hr:220:624635>

Rights / Prava: [Attribution-NonCommercial-NoDerivatives 4.0 International](#)/[Imenovanje-Nekomercijalno-Bez prerada 4.0 međunarodna](#)

Download date / Datum preuzimanja: **2024-09-08**



Repository / Repozitorij:

[Repository of the Sestre milosrdnice University Hospital Center - KBCSM Repository](#)



MICROSURGICAL MANAGEMENT OF LOW-GRADE SPINAL CORD ASTROCYTOMA IN ADULTS: A PERSONAL CASE SERIES REPORT AND BRIEF LITERATURE REVIEW

Mirza Pojskić^{1,2}, Krešimir Rotim^{2,3,4}, Bruno Splavski^{2,3,4,5} and Kenan I. Arnautović^{6,7}

¹Department of Neurosurgery, University of Marburg, Marburg, Germany;

²Faculty of Medicine, Josip Juraj Strossmayer University of Osijek, Osijek, Croatia;

³Department of Neurosurgery, Sestre milosrdnice University Hospital Centre, Zagreb, Croatia;

⁴University of Applied Health Sciences, Zagreb, Croatia;

⁵School of Dental Medicine and Health, Josip Juraj Strossmayer University of Osijek, Osijek, Croatia;

⁶Semmes-Murphey Neurologic & Spine Institute, Memphis, TN, United States;

⁷Department of Neurosurgery, University of Tennessee Health Science Center, Memphis, TN, United States

SUMMARY – Astrocytoma is the second most common intramedullary tumor of predominantly low-grade malignancy in adult patients. Adult astrocytomas have better-quality prognosis compared with astrocytomas in children. Although a standardized surgical management protocol for spinal cord glioma is currently unavailable, surgery of low-grade astrocytoma should be aimed at gross total resection to preserve neurological function and to improve the outcome. Herein, we present a personal case series of four consecutive adult spinal cord astrocytoma patients who were operated on during the last few years. Tumor resection was performed in all patients utilizing microsurgical technique and intraoperative neurophysiologic monitoring. We also provide a literature review of the treatment of intramedullary astrocytoma in adults and discuss contemporary surgical management and prognosis.

Key words: *Intramedullary tumor; Low-grade astrocytoma; Microsurgical management*

Introduction

Spinal cord astrocytoma is an intradural intramedullary glial cell tumor accounting for 6%-8% of all primary spinal cord growths¹⁻⁵. It is the most common intramedullary pediatric tumor and occurs secondary to ependymoma in adult patients. Adult astrocytomas have better-quality prognosis compared with astrocytomas in children. Although classified as histologically malignant according to the 2016 World Health Organization (WHO) tumor classification⁶, these tumors are predominantly of low-grade malignancy, including

diffuse and pilocytic astrocytoma¹⁻⁵. Since the average age at presentation in adults is 29±18 years⁷, it can be said that it predominantly affects younger patients, but steady age distribution from early childhood to the advanced age is not rare⁷. In general, low-grade astrocytoma has longer disease history with a range of various symptoms that are reliant on tumor volume and location, growth pattern, and histology⁸.

Notwithstanding their low-grade histologic nature, these tumors can be well enhanced on contrast magnetic resonance imaging (MRI) of the spine², which improves distinction between more common solid and less common cystic types of the tumor, which are usually more malignant⁴ but can be better gross totally resected due to their less infiltrative growth pattern⁹. Nevertheless, a standardized surgical management

Correspondence to: *Kenan Arnautović, MD, PhD*, 6325 Humphreys Blvd, Memphis, TN 38120, US

E-mail: kenanarnaut@yahoo.com

Received April 23, 2020, accepted August 28, 2020

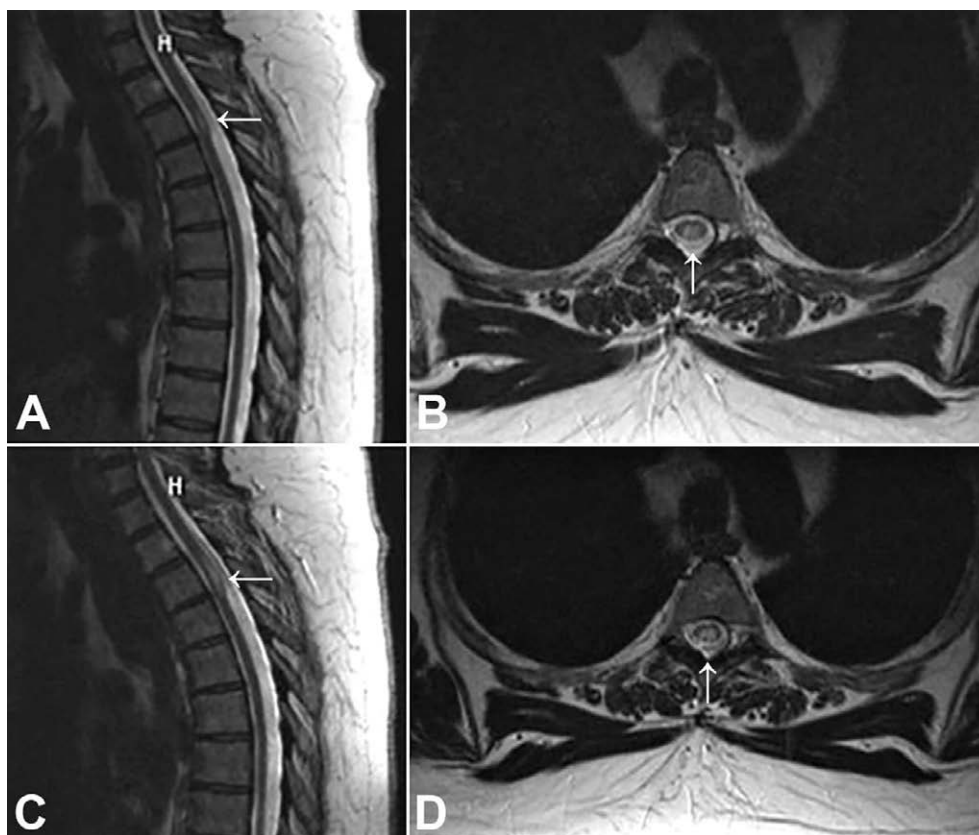


Fig. 1. Sagittal T2-weighted magnetic resonance imaging (MRI) of the thoracic spine (A) showing the hyperintense intramedullary lesion at T1 (arrow); axial T2-weighted MRI of the thoracic spine showing lesion at the same level (arrow) (B); sagittal (C) and axial (D) T2-weighted MRI of the thoracic spine at 6-year follow-up revealing lesion growth (arrow).

protocol for spinal cord glioma is currently unavailable^{4,10,11}, although the treatment of low-grade tumors should be aimed at radical, gross total microsurgical resection to improve and preserve neurological function^{2,8,12}.

Herein, we present a personal surgical case series of four spinal cord astrocytoma adult patients, and describe contemporary microsurgical techniques that are intended to assure complete tumor resection. We also provide a literature review and discuss the extent of resection, neurological outcome, and prognosis.

Case Series Report

During the last few years, four consecutive adult spinal cord astrocytoma patients were operated on by a senior neurosurgeon (K.I.A.). This personal series of surgical patients included three females and one male,

mean age 55.5 years at the time of surgery. Immediate postoperative recovery was favorable in all patients, whose neurological and functional status much improved following surgery.

Case 1

A 61-year-old female presented with type 2 diabetes, diabetic polyneuropathy, and gait disturbances with minor motor weakness in her lower limbs (light paraparesis). She was previously diagnosed with an intramedullary tumor mass at the T1 level and was clinically and radiologically followed-up for several years. Her preoperative cervical and thoracic spine contrast-enhanced magnetic resonance imaging (MRI) at 8 years, 2 years, and immediately prior to surgery are depicted in Figures 1 and 2.

Due to worsening of neurological deficit related to tumor progression, she was eventually operated on.

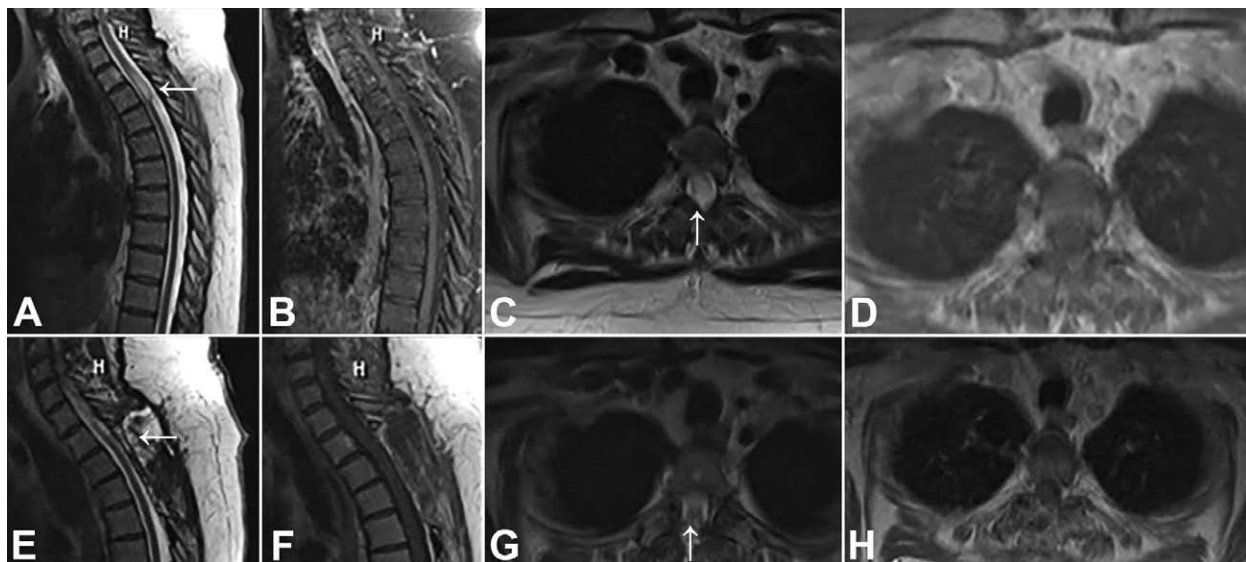


Fig. 2. Preoperative sagittal T2-weighted (A), sagittal T1-weighted post-contrast (B), axial T2-weighted (C), and post-contrast axial T1-weighted (D) magnetic resonance imaging (MRI) of the cervicothoracic spine showing an intramedullary tumor (arrows); postoperative sagittal T2-weighted (E), sagittal T1-weighted post-contrast (F), axial T2-weighted (G), and axial T1-weighted post-contrast (H) MRI of the cervicothoracic spine demonstrating complete tumor resection (arrows).

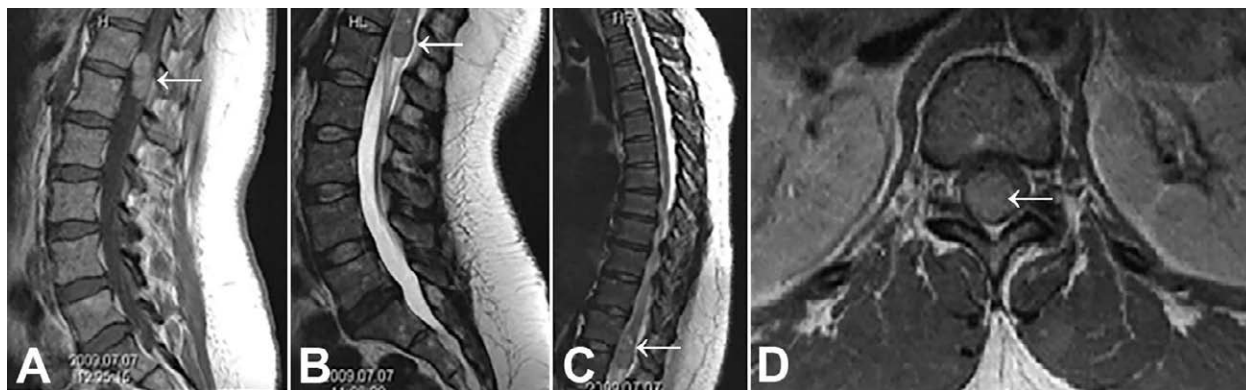

Fig. 3. Sagittal T1-weighted post-contrast magnetic resonance imaging (MRI) of the lumbar spine showing well-demarcated homogeneously enhanced intramedullary lesion (arrow) (A); sagittal T2-weighted (B), sagittal T2-weighted (C), and axial post-contrast T1-weighted MRI (D) of the lumbar and thoracic spine depicting intramedullary tumor at T12 level (arrows).

The tumor was completely resected and histopathologic analysis of tissue samples confirmed the tumor as a low-grade astrocytoma (WHO grade II). Postoperative MRI of the cervicothoracic spine showed complete tumor resection (Fig. 2A-H).

Case 2

A 45-year-old female presented with lower back pain, decreased motor strength of lower limbs, and

perineal numbness. Sagittal and axial MRI reformations of the entire spine showed an intramedullary tumor growth at the T12-L1 levels (Fig. 3A-D). The tumor was resected using a meticulous microsurgical technique and intraoperative neurophysiological monitoring to record motor evoked potentials (MEP). The immediate postoperative imaging of the lumbar and thoracic spine are depicted in Figure 4(A-C). Histopathologic diagnosis defined the tumor as anaplastic

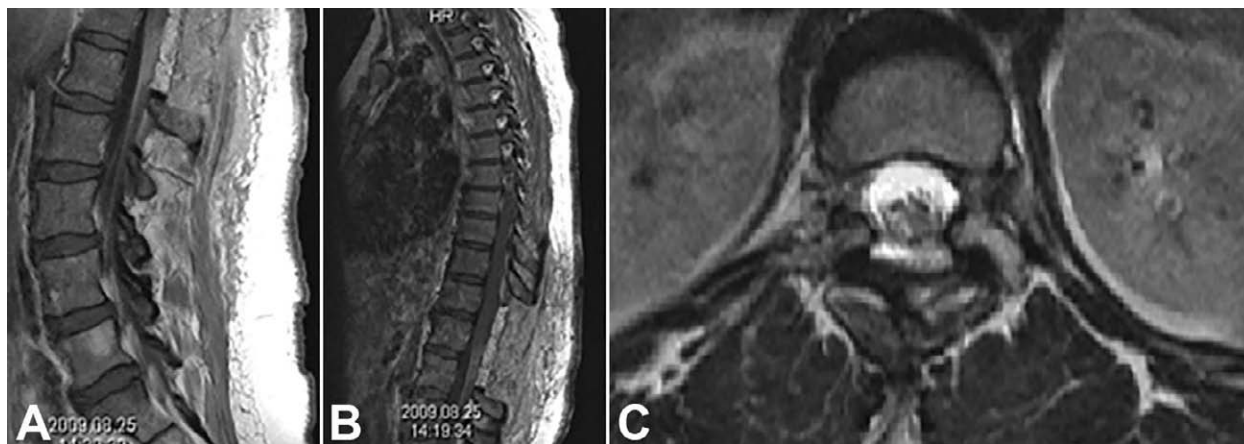

Fig. 4. Postoperative T1-weighted post-contrast sagittal magnetic resonance imaging (MRI) of the lumbar (A) and thoracic (B) spine showing complete tumor resection; axial T2-weighted MRI of the resection cavity at T12 level (C).

astrocytoma (WHO grade III). Postoperative focal irradiation of the tumor field was applied.

Case 3

A 58-year-old male presented with lower limb motor weakness and sensory loss at the T1 level. Whole spine MRI identified an intramedullary tumor growth at the T1-2 level (Fig. 5A-C), which was successfully resected by microsurgical technique with the help of intraoperative neurophysiological monitoring (Fig. 5D-F). Histopathologic diagnosis confirmed it as low-grade astrocytoma (WHO grade II).

Case 4

A 58-year-old female presented with lower limb motor weakness (paraparesis). Preoperative contrast-enhancing spinal MRI showed an intramedullary tumor at the T4 level (Fig. 6A-D). Gross total tumor microsurgical resection was achieved, which was confirmed by postoperative MRI of the thoracic spine (Fig. 7A-C). Histopathologic diagnosis identified the tumor as low-grade spinal cord astrocytoma (WHO grade II).

Discussion

After reviewing the literature, we found the mean patient age at presentation to range from 28.3 to 41±17 years^{7,12,13}. Five-year survival of patients with low-grade tumors (WHO grades I and II) ranged from 54% to 78% with median survival of 8-13 years. A de-

tailed literature review of spinal cord astrocytomas has been published recently by our group⁸.

Preoperative neuroradiological evaluation includes MRI with and without contrast of the selected areas of the spine. Enhancement of spinal cord astrocytomas appears to vary and may include cystic formations within. Anteroposterior/lateral and flexion and extension x-rays are important to assess the potential spinal instability and the need of instrumentation.

Laminectomy with the patient in prone position is the most common surgical approach used to expose the posterior/dorsal part of the vertebral canal, spinal cord, and intramedullary lesions. Laminoplasty can also be utilized, especially in younger patients and in patients with multiple levels of involvement. Instrumented fusion can be considered especially in cervicothoracic and thoracolumbar junctions. Dura opening, arachnoid dissection, and myelotomy are usually performed dorsally through a midline incision *via* the posterior midline septum. The aim of surgery is to separate tumor margins meticulously from the surrounding cord tissue, which is not always easy to achieve when infiltrating tumors of more malignant grades are encountered^{8,14}. Yet, sharp dissection and creation of clear tumor planes is necessary to better expose the tumor, but may be challenging, which calls for high surgical skills.

We follow these rules for microsurgical technique and employed the same operative technique in the patients from this series^{8,14}. Recently, we have published a video clip of the surgical removal of spinal cord astrocytoma, which is available with free access¹⁴.

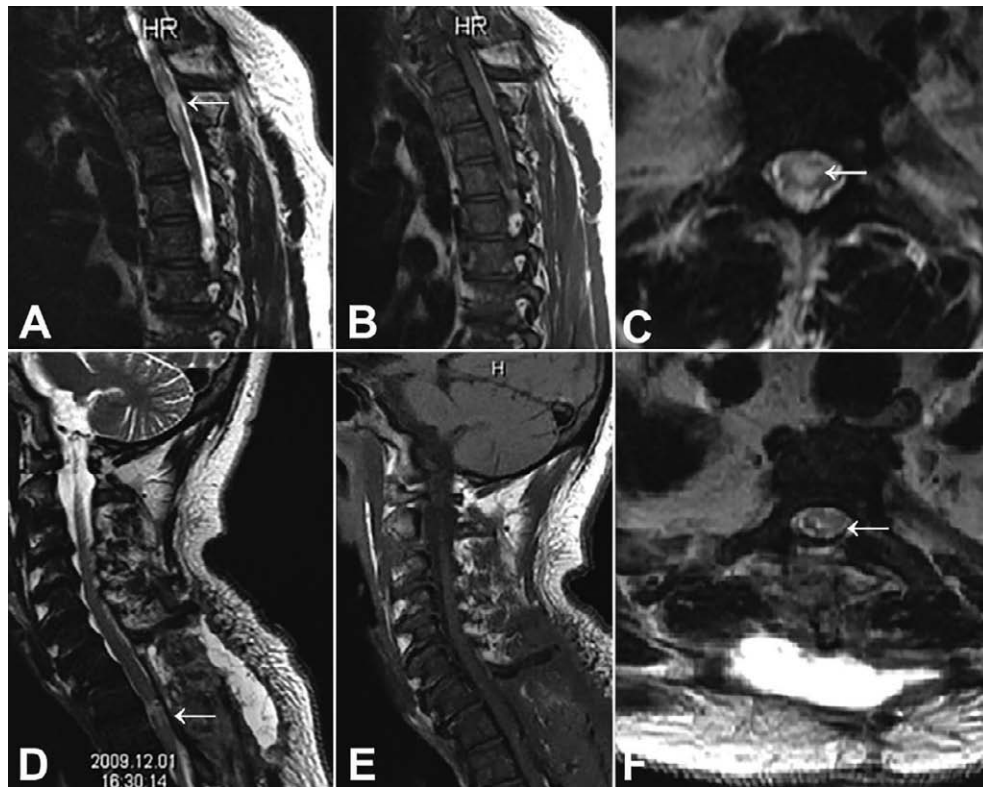


Fig. 5. Sagittal T2-weighted (A), sagittal post-contrast T1-weighted (B), axial T2-weighted magnetic resonance imaging (MRI) (C), sagittal T2-weighted (D), and sagittal post-contrast T1-weighted (E) MRI of the thoracic spine showing complete resection of intramedullary tumor; axial T2-weighted spinal MRI showing tumor resection cavity (F) (arrows).

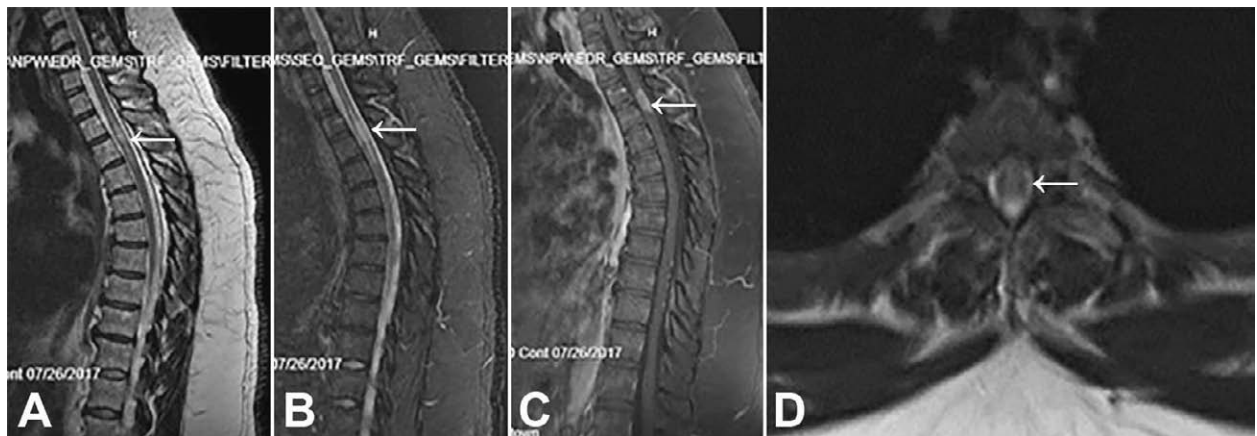


Fig. 6. Preoperative sagittal magnetic resonance imaging (MRI) of the spine showing T2-weighted hyperintense (A, B) intramedullary contrast-enhancing tumor at T4 level (C) (arrows); axial T2-weighted MRI at the level of the tumor (D) (arrow).

Recent analyses have shown that intraoperative neurophysiological monitoring and computed tomography neuro-navigation with advanced multi-modal

options of microscope-based augmented reality, as well as other up-to-date, cutting-edge microsurgical armamentarium may be very helpful in providing accurate

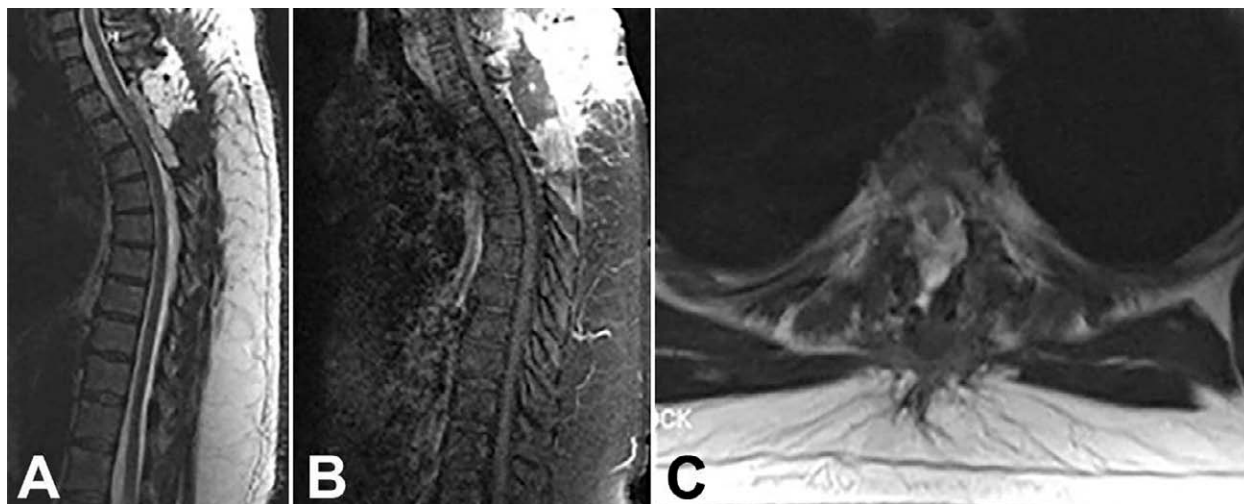


Fig. 7. Postoperative sagittal (A), post-contrast sagittal (B), and axial (C) magnetic resonance imaging of the thoracic spine showing successful gross total tumor microsurgical resection.

tumor visualization and in ensuring high-precision dissection when intradural spinal growths are concerned^{15,16}. In spite of that, literature data on gross tumor resection rates for low-grade spinal cord glioma range between 5% and 72.7% of cases^{13,17-20}, although population-based studies confirmed improved outcomes and overall survival in these patients²¹⁻²⁵, especially those of younger age^{26,27}. However, preoperative and postoperative neurological condition, extent of resection, and low histological grade remain the strongest outcome predictors^{3,4,8,10,22 28-32}.

Gross total tumor resection was achieved in all four patients in our series. Their immediate postoperative recovery was favorable, which allowed for marked improvement in neurological functioning in all of them. Nonetheless, having in mind that a significant percentage of low-grade astrocytomas are more likely to be removed completely, it seems that the extent of resection alone may not be the only predictive outcome parameter^{4,8}.

Since the postoperative recurrence rate of low-grade astrocytoma is usually low, it appears that adjuvant therapy is not obligatory in all cases. Accordingly, some authors recommend radiotherapy for patients with high-grade tumors only⁷. We have opted for the same strategy in this series of patients, bearing in mind that the main factor influencing prognosis and outcome of these, as well as other primary intramedullary spinal cord tumors is not the mode of treatment, but

tumor grading, preoperative and postoperative neurological condition, and the extent of resection^{28,33,34}.

In conclusion, we believe that surgery of adult low-grade spinal cord astrocytoma should be aimed at gross total tumor resection in cautiously selected patients, which could result in a favorable outcome. Simultaneously, cutting-edge microsurgical equipment and technique should be engaged to achieve the goals of surgery. Neurophysiological monitoring during surgery is of utmost importance.

Nonetheless, continuous supplementary research in a greater number of patients is required in order to endorse these suggestions further.

Acknowledgments

The authors wish to thank Andrew J. Gienapp, Neuroscience Institute, Le Bonheur Children's Hospital and Department of Neurosurgery, University of Tennessee Health Science Center, Memphis, TN, United States, for copy editing and formatting the manuscript.

References

1. Epstein FJ, Farmer JP, Freed D. Adult intramedullary astrocytomas of the spinal cord. *J Neurosurg.* 1992;77(3):355-9. doi: 10.3171/jns.1992.77.3.0355.
2. Houten JK, Cooper PR. Spinal cord astrocytomas: presentation, management and outcome. *J Neurooncol.* 2000;47(3): 219-24. doi: 10.1023/a:1006466422143.

3. Minehan KJ, Shaw EG, Scheithauer BW, Davis DL, Onofrio BM. Spinal cord astrocytoma: pathological and treatment considerations. *J Neurosurg.* 1995;83(4):590-5. doi: 10.3171/jns.1995.83.4.0590.
4. Ryu SJ, Kim JY, Kim KH, Park JY, Kuh SU, Chin DK, *et al.* A retrospective observational study on the treatment outcomes of 26 patients with spinal cord astrocytoma including two cases of malignant transformation. *Eur Spine J.* 2016;25(12):4067-79. doi: 10.1007/s00586-016-4475-7.
5. Yang S, Yang X, Hong G. Surgical treatment of one hundred seventy-four intramedullary spinal cord tumors. *Spine (Phila Pa 1976).* 2009;34(24):2705-10. doi: 10.1097/BRS.0b013e3181b43484.
6. Louis DN, Perry A, Reifenberger G, von Deimling A, Figarella-Branger D, Cavenee WK, *et al.* The 2016 World Health Organization Classification of Tumors of the Central Nervous System: a summary. *Acta Neuropathol.* 2016;131(6):803-20. doi: 10.1007/s00401-016-1545-1.
7. Klekamp J, Samii M. *Surgery of Spinal Tumors.* Berlin/Heidelberg, Germany: Springer-Verlag; 2007. ISBN 978-3-540-44715-3.
8. Pojskić M, Arnautovic KI. Spinal cord astrocytomas. In: Arnautovic KI, Gokaslan ZL, editors. *Spinal Cord Tumors.* Cham, Switzerland: Springer Nature; 2019, p. 211-41. ISBN 978-3-319-99438-3.
9. Zhao M, Shi B, Chen T, Zhang Y, Geng T, Qiao L, *et al.* Axial MR diffusion tensor imaging and tractography in clinically diagnosed and pathology confirmed cervical spinal cord astrocytoma. *J Neurol Sci.* 2017;375:43-51. doi: 10.1016/j.jns.2017.01.044.
10. Kim MS, Chung CK, Choe G, Kim IH, Kim HJ. Intramedullary spinal cord astrocytoma in adults: postoperative outcome. *J Neurooncol.* 2001;52(1):85-94. doi: 10.1023/a:1010680924975.
11. Kim WH, Yoon SH, Kim CY, Kim KJ, Lee MM, Choe G, *et al.* Temozolomide for malignant primary spinal cord glioma: an experience of six cases and a literature review. *J Neurooncol.* 2011;101(2):247-54. doi: 10.1007/s11060-010-0249-y.
12. Klekamp J. Treatment of intramedullary tumors: analysis of surgical morbidity and long-term results. *J Neurosurg Spine.* 2013;19(1):12-26. doi: 10.3171/2013.3.SPINE121063.
13. Fakhreddine MH, Mahajan A, Penas-Prado M, Weinberg J, McCutcheon IE, Pudukvalli V, *et al.* Treatment, prognostic factors, and outcomes in spinal cord astrocytomas. *Neuro Oncol.* 2013;15(4):406-12. doi: 10.1093/neuonc/nos309.
14. Pojskić M, Arnautovic KI. Microsurgical resection of low-grade spinal cord astrocytoma: 2-dimensional operative video. *Oper Neurosurg (Hagerstown).* 2019;17(3):E107-E8. doi: 10.1093/ons/opy386.
15. Carl B, Bopp M, Sass B, Voellger B, Nimsky C. Implementation of augmented reality support in spine surgery. *Eur Spine J.* 2019;28(7):1697-711. doi: 10.1007/s00586-019-05969-4.
16. Carl B, Bopp M, Sass B, Pojskić M, Nimsky C. Augmented reality in intradural spinal tumor surgery. *Acta Neurochir (Wien).* 2019;161(10):2181-93. doi: 10.1007/s00701-019-04005-0.
17. Babu R, Karikari IO, Owens TR, Bagley CA. Spinal cord astrocytomas: a modern 20-year experience at a single institution. *Spine (Phila Pa 1976).* 2014;39(7):533-40. doi: 10.1097/BRS.000000000000190.
18. Parker F, Campello C, Lejeune JP, David P, Herbrecht A, Aghakhani N, *et al.* Astrocytomes intramédullaires: analyse rétrospective française multicentrique. [Intramedullary astrocytomas: a French retrospective multicenter study]. *Neurochirurgie.* 2017;63(5):402-9. doi: 10.1016/j.neuchi.2016.09.007.
19. Sandalcioglu IE, Gasser T, Asgari S, Lazorisak A, Engelhorn T, Egelhof T, *et al.* Functional outcome after surgical treatment of intramedullary spinal cord tumors: experience with 78 patients. *Spinal Cord.* 2005;43(1):34-41. doi: 10.1038/sj.sc.3101668.
20. Ardeshiri A, Chen B, Hutter BO, Oezkan N, Wanke I, Sure U, *et al.* Intramedullary spinal cord astrocytomas: the influence of localization and tumor extension on resectability and functional outcome. *Acta Neurochir (Wien).* 2013;155(7):1203-7. doi: 10.1007/s00701-013-1762-5.
21. Adams H, Avendano J, Raza SM, Gokaslan ZL, Jallo GI, Quinones-Hinojosa A. Prognostic factors and survival in primary malignant astrocytomas of the spinal cord: a population-based analysis from 1973 to 2007. *Spine (Phila Pa 1976).* 2012;37(12):E727-35. doi: 10.1097/BRS.0b013e31824584c0.
22. Abdel-Wahab M, Etuk B, Palermo J, Shirato H, Kresl J, Yapiçier O, *et al.* Spinal cord gliomas: a multi-institutional retrospective analysis. *Int J Radiat Oncol Biol Phys.* 2006;64(4):1060-71. doi: 10.1016/j.ijrobp.2005.09.038.
23. Nakamura M, Chiba K, Ishii K, Ogawa Y, Takaishi H, Matsumoto M, *et al.* Surgical outcomes of spinal cord astrocytomas. *Spinal Cord.* 2006;44(12):740-5. doi: 10.1038/sj.sc.3101932.
24. Benes V 3rd, Barsa P, Benes V Jr, Suchomel P. Prognostic factors in intramedullary astrocytomas: a literature review. *Eur Spine J.* 2009;18(10):1397-422. doi: 10.1007/s00586-009-1076-8.
25. Diaz-Aguilar D, ReFaey K, Clifton W, Durcanova B, Chen SG, Deen HG, *et al.* Prognostic factors and survival in low grade gliomas of the spinal cord: a population-based analysis from 2006 to 2012. *J Clin Neurosci.* 2019;61:14-21. doi: 10.1016/j.jocn.2018.11.025.
26. Rodrigues GB, Waldron JN, Wong CS, Laperriere NJ. A retrospective analysis of 52 cases of spinal cord glioma managed with radiation therapy. *Int J Radiat Oncol Biol Phys.* 2000;48(3):837-42. doi: 10.1016/s0360-3016(00)00690-8.
27. Lee HK, Chang EL, Fuller GN, Aldape KD, Atkinson GJ, Levy LB, *et al.* The prognostic value of neurologic function in astrocytic spinal cord glioma. *Neuro Oncol.* 2003;5(3):208-13. doi: 10.1215/S1152851702000595.
28. Huddart R, Traish D, Ashley S, Moore A, Brada M. Management of spinal astrocytoma with conservative surgery and radiotherapy. *Br J Neurosurg.* 1993;7(5):473-81. doi: 10.3109/02688699308995069.
29. Jyothirmayi R, Madhavan J, Nair MK, Rajan B. Conservative surgery and radiotherapy in the treatment of spinal cord astrocytoma. *J Neurooncol.* 1997;33(3):205-11. doi: 10.1023/a:1005758313700.

30. Khalid S, Kelly R, Carlton A, Wu R, Peta A, Melville P, *et al.* Adult intradural intramedullary astrocytomas: a multicenter analysis. *J Spine Surg.* 2019;5(1):19-30. doi: 10.21037/jss.2018.12.06.
31. McGirt MJ, Goldstein IM, Chaichana KL, Tobias ME, Kothbauer KF, Jallo GI. Extent of surgical resection of malignant astrocytomas of the spinal cord: outcome analysis of 35 patients. *Neurosurgery.* 2008;63(1):55-60. doi: 10.1227/01.NEU.0000335070.37943.09.
32. Brotchi J. Intramedullary astrocytoma surgery in adult patients: the rationale for cautious surgery. *World Neurosurg.* 2013; 80(5):e139-40. doi: 10.1016/j.wneu.2011.12.065.
33. Karikari IO, Nimjee SM, Hodges TR, Cutrell E, Hughes BD, Powers CJ, *et al.* Impact of tumor histology on resectability and neurological outcome in primary intramedullary spinal cord tumors: a single-center experience with 102 patients. *Neurosurgery.* 2015;76 Suppl 1:S4-13. doi: 10.1227/NEU.0b013e3181fe3794.
34. Omerhodžić I, Pojskić M, Splavski B, Rotim K, Rasulić L, Arnautović KI. Myxopapillary ependymomas of the spinal cord in adults: a report of personal series and review of literature. *Acta Clin Croat.* 2020;59(2):329-37. doi: 10.20471/acc.2020.59.02.17.

Sažetak

ASTROCITOM KRALJEŽNIČKE MOŽDINE NISKOG STUPNJA MALIGNOSTI U ODRASLIH: PRIKAZ OSOBNE SERIJE BOLESNIKA I PREGLED LITERATURE

M. Pojskić, K. Rotim, B. Splavski i K.I. Arnautović

Astroцитом кралјежничке мождине је тумор претежито ниског ступња малигности који је по учесталости други интрамедуларни тумор у одраслих у којих је његова прогноза знатно повољнија у упоредаби с прогнозом у дјече. Унаточ тому што стандардизирани протокол за хируршко liječenje глиомских тумора кралјежничке мождине засад не постоји, циљ оваквог liječenja требао би бити усмјерен ка уклањању тумора у цијелости како би се очувала невролошка функционалност и побољшала успјешност liječenja. У овом раду дајемо приказ особне серије током неколико последњих година суслједно оперираних четворо одраслих болесника с астрочитомом кралјежничке мождине у којих је тумор микрохирурски уклоњен уз помоћ интраоперацијског физиолошког праћења. У раду такође доносимо преглед литературе о lijeчењу интрамедуларних астрочитума у одраслих, расправљајући о савременом хирурском lijeчењу оваквих тумора и прогнози болести.

Кључне ријечи: *Intramedularni tumor; Astroцитом, ниски ступањ малигности; Микрохирурско liječenje*