

Minimally Invasive Treatment of Idiopathic Syringomyelia Using Myringotomy T-Tubes: a Case Report and Technical Note

Jugović, Domagoj; Bošnjak, Roman; Rotim, Krešimir; C. Feigl, Günther

Source / Izvornik: *Acta clinica Croatica*, 2020, 59, 177 - 182

Journal article, Published version

Rad u časopisu, Objavljena verzija rada (izdavačev PDF)

<https://doi.org/10.20471/acc.2020.59.01.23>

Permanent link / Trajna poveznica: <https://um.nsk.hr/um:nbn:hr:220:021766>

Rights / Prava: [Attribution-NonCommercial-NoDerivatives 4.0 International](#)/[Imenovanje-Nekomercijalno-Bez prerada 4.0 međunarodna](#)

Download date / Datum preuzimanja: **2024-11-12**



Repository / Repozitorij:

[Repository of the Sestre milosrdnice University Hospital Center - KBCSM Repository](#)



MINIMALLY INVASIVE TREATMENT OF IDIOPATHIC SYRINGOMYELIA USING MYRINGOTOMY T-TUBES: A CASE REPORT AND TECHNICAL NOTE

Domagoj Jugović^{1,2}, Roman Bošnjak^{2,3}, Krešimir Rotim^{4,5,6} and Günther C. Feigl^{1,7,8}

¹Department of Neurosurgery, Bamberg General Hospital, Bamberg, Germany;

²University of Ljubljana, Faculty of Medicine, Ljubljana, Slovenia;

³Department of Neurosurgery, University Medical Centre Ljubljana, Ljubljana, Slovenia;

⁴Department of Neurosurgery, Sestre milosrdnice University Hospital Centre, Zagreb, Croatia;

⁵Josip Juraj Strossmayer University of Osijek, Faculty of Medicine, Osijek, Croatia;

⁶University of Applied Health Sciences, Zagreb, Croatia;

⁷Department of Neurosurgery, Tübingen University Hospital, Tübingen, Germany;

⁸Department of Neurological Surgery, Houston Methodist Hospital, Houston, Texas, USA

SUMMARY – Syringomyelia is characterized by a fluid-filled cavity within the spinal cord. Expansion of the syrinx often results in the clinical course of progressive neurologic deficit. Surgery for syringomyelia generally aims to treat the underlying cause, if it is known. However, little is known about idiopathic syringomyelia, which requires specific management. In our paper, an alternative, minimally invasive treatment option for large symptomatic idiopathic cervicothoracic syrinx is described and discussed. We present a case of a 44-year-old male without a history of spinal cord trauma, infection, or other pathologic processes, who presented for thoracic pain. Due to progressive pain and left leg paresis, magnetic resonance imaging (MRI) was performed and revealed extensive septated syringomyelia from T5 to T7 and hydromyelia cranially. We applied minimally invasive technique for shunting the idiopathic syrinx into the subarachnoid space using two Richards modified myringotomy T-tubes. Postoperative MRI revealed significant decrease in the syrinx size and clinical six-month follow-up showed improvement of clinical symptoms. This minimally invasive treatment of syringomyelia was found to be an effective method for idiopathic septated syrinx, without evident underlying cause. However, long-term follow-up and more patients are necessary for definitive evaluation of this technique.

Key words: *Syringomyelia; Magnetic resonance imaging; Cerebrospinal fluid shunts; Middle ear ventilation*

Introduction

Syringomyelia is an etiologically diverse disorder caused by disturbance of physiological cerebrospinal fluid flow circulation¹. Enlargement of the fluid-filled

cavity within the spinal cord often results in the clinical course of progressive neurologic deficit, such as sensory loss, pain, motor weakness, and autonomic dysfunction². Many papers have been published on syringomyelia related to Chiari malformation, but little is known about idiopathic syringomyelia, which requires specific management³. Over years, numerous theories have attempted to explain the pathogenesis of syringomyelia. A recent study supports the hypothesis

Correspondence to: Domagoj Jugović, Klinikum Bamberg, Buger Straße 80, 96049 Bamberg, Germany

E-mail: djugovic@yahoo.com

Received February 1, 2020, accepted February 28, 2020

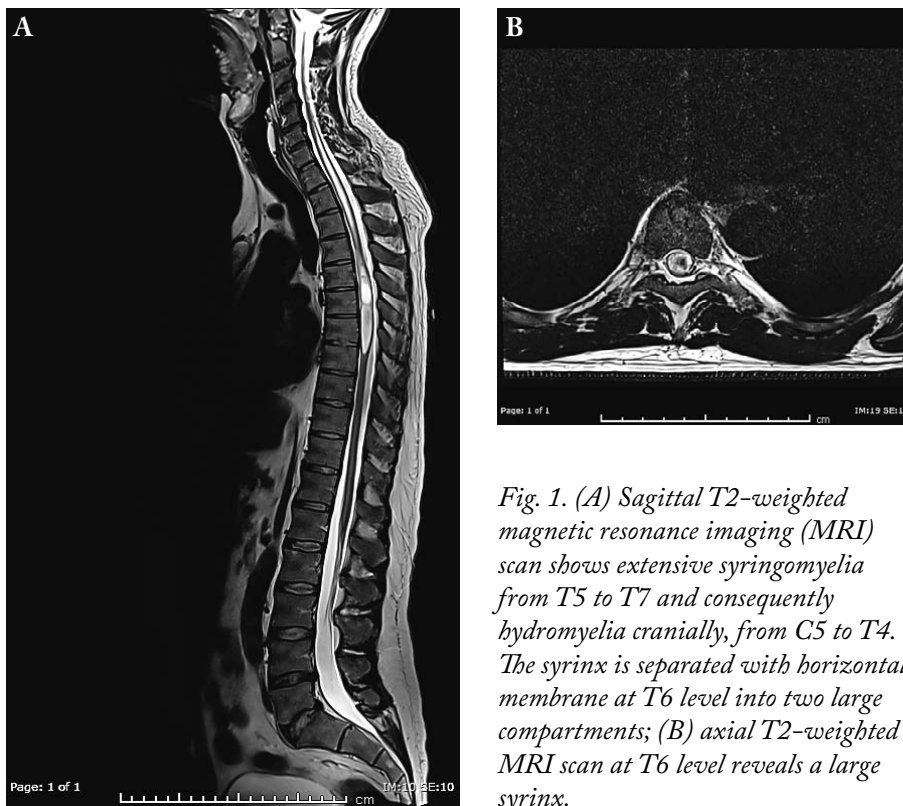


Fig. 1. (A) Sagittal T2-weighted magnetic resonance imaging (MRI) scan shows extensive syringomyelia from T5 to T7 and consequently hydromyelia cranially, from C5 to T4. The syrinx is separated with horizontal membrane at T6 level into two large compartments; (B) axial T2-weighted MRI scan at T6 level reveals a large syrinx.

that perivascular spaces play an important role in facilitating fluid flow in the spinal cord tissue, and their integrity is compromised in syringomyelia. An impaired blood spinal cord barrier and increased vesicular transport may provide an additional route of fluid ingress that destabilizes normal volume regulation of the spinal cord⁴.

In our paper, an alternative, minimally invasive treatment option for large symptomatic idiopathic cervicothoracic syrinx is described and discussed. Surgical intervention resulted in improvement of clinical symptoms. Only a few publications have reported a similar method⁵⁻⁷.

Case Report

A 44-year-old male patient without a history of column or cord trauma, infection, or other pathologic processes reported thoracic spine pain radiating into the left chest. The patient presented with progressive left leg paresis and reduced pain sensitivity on the right side of his body, from lower abdomen to the right foot. Neurological examination revealed mild weak-

ness of the left leg, decreased sensation to pinprick and temperature in the right leg, without a clear sensory level and reduced proprioception and vibration sensations in the left leg. Magnetic resonance imaging (MRI) showed extensive syringomyelia from T5 to T7 and hydromyelia cranially, from C5 to T4. The syrinx was separated with horizontal membrane at T6 level into two large compartments (Fig. 1). The patient elected to proceed with surgery once conservative management including physical therapy and analgesics had failed.

Minimally invasive surgery was performed in prone position in general anesthesia under continuous intraoperative neurophysiological monitoring and using microsurgical technique. The correct thoracic spine level (T6) was localized by fluoroscopy. Hemilaminectomy at T6 level was done on the right side using a high-speed drill, while the spinous processes and interspinous ligament were left intact. Additional undercutting toward the opposite, left side with Kerrison punch and drill was performed, so that the underlying dura was fully exposed. Dura was visualized at T6 level and incised in the midline. We did not find any sub-




Fig. 2. Richards modified myringotomy T-tube; soft silicone, internal diameter 1.32 mm, length 4.8 mm.

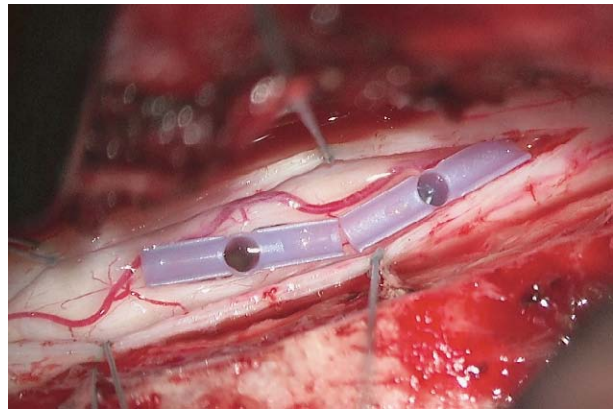

Fig. 3. Two Richards modified myringotomy T-tubes are inserted within the myelotomies at T6 level, maintaining the newly created communications from the syrinx to the subarachnoid space.

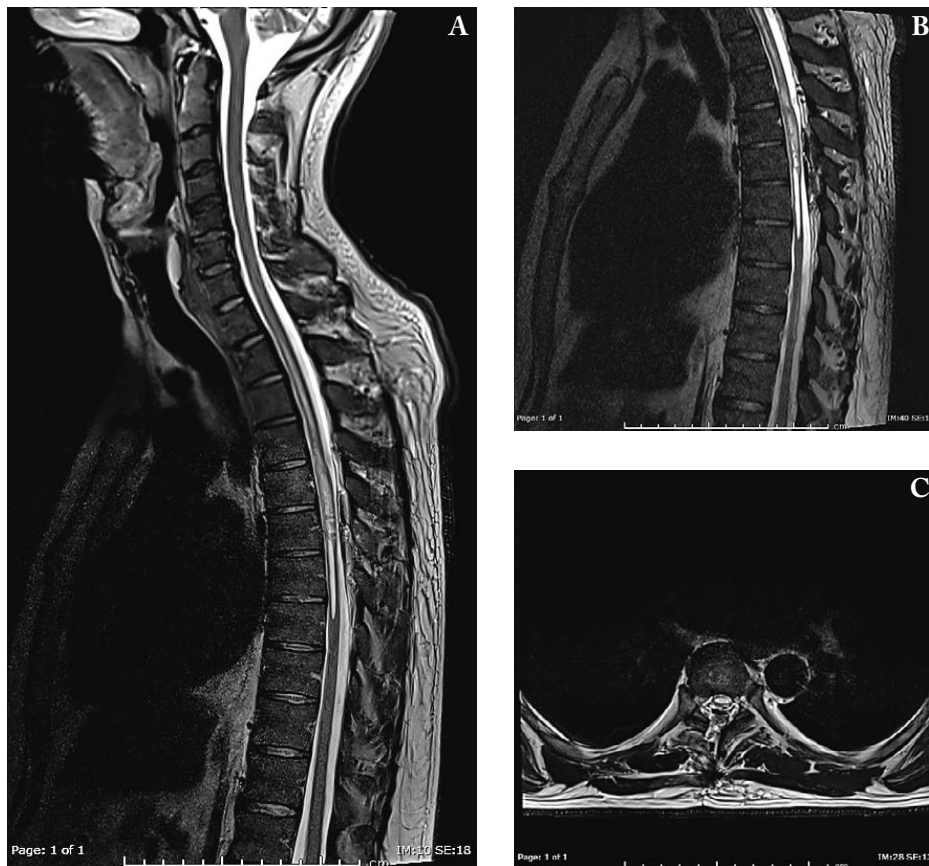


Fig. 4 (A) Postoperative sagittal T2-weighted magnetic resonance imaging (MRI) scan (one day after surgery) shows significant decrease in the size of both the syrinx and hydromyelia; (B) sagittal T2-weighted SPACE (sampling perfection with application-optimized contrasts using different flip-angle evolution) image; (C) axial T2-weighted MRI scan at T6 level after hemilaminectomy.

dural and subarachnoid irregularity or liquor flow obstruction. Two small myelotomies were performed in the midline, along the posterior median sulcus, after mobilization of the dorsal medial vein. The first myelotomy was done caudally and second cranially from the syrinx septum at T6 level, causing a gush of fluid from the myelon. After syrinx decompression, myelon pulsations were noticed. The septum inside the syrinx was fenestrated using Rhoton micro hooks and then two Richards modified myringotomy T-tubes (Ultrasil silicone, internal diameter 1.32 mm, length 4.8 mm; Gyrus ACMI, Southborough, MA, USA) were inserted within the myelotomies, maintaining the newly created communications from the syrinx to the subarachnoid space (Figs. 2 and 3). The communication between both syrinx compartments was also proven (water flows freely between the two tubes). The dura was closed in a watertight fashion and the wound in usual manner. There was no change in the intraoperative motor and somatosensory evoked potentials.

Postoperatively, follow-up MRI one day after the surgery showed a significant decrease in the size of both the syrinx and hydromyelia (Fig. 4). The patient strength examination was stable, but he revealed numbness and tingling in the right leg. The pain in the thoracic spine and left chest was significantly diminished. At three- and six-month follow-up, the patient's strength in the left leg and sensation in the right leg improved continuously. At three months, he had returned to work. Follow-up MRI three months after the surgery (performed at another institution) revealed slight refilling of the syrinx without hydromyelia cranially.

Discussion

Regional cerebrospinal fluid blockage and liquor pressure differentials have been recognized as key factors in the pathophysiology of syringomyelia⁸. The understanding of the cerebrospinal fluid dynamics in each individual case of syringomyelia is the key in identifying the proper surgical treatment. In the absence of posterior fossa/craniocervical junction pathology (most commonly found in association with syringomyelia), a local cerebrospinal fluid flow disturbance within the subarachnoid compartment could be responsible for syrinx development. An animal model demonstrated fluid flow from the spinal subarachnoid

space into the perivascular spaces and then into the central canal or syrinx. Fluid flowed preferentially at the level of the syrinx, suggesting that a change in the subarachnoid space compliance potentiates a local arterial-driven perivascular flow⁹. In our case, the etiology of syringomyelia was unknown. The patient did not have any evident cause in the craniocervical junction. He did not undergo preoperative myelography that could disclose possible flow block implying cerebrospinal fluid obstruction at the syrinx level. However, intraoperatively, local finding was regular, without subarachnoid obstruction for cerebrospinal fluid (arachnoid cyst, adhesions, 'occult' arachnoid web)¹⁰.

Surgery for syringomyelia generally aims to treat the underlying cause, if it is known. In such cases, surgical procedure that successfully opens the subarachnoid space can correct the underlying pathophysiology of syringomyelia and eliminate the syrinx¹¹. However, the optimal management for idiopathic syringomyelia is unclear and syrinx shunting to the subarachnoid space is an option in these cases¹². Nonetheless, placement of all types of shunts (syringosubarachnoid, syringoperitoneal, and syringopleural) may be followed by significant morbidity requiring one or more additional surgical procedures¹³.

We used a minimally invasive technique for shunting the idiopathic syrinx into the subarachnoid space using two Richards modified myringotomy T-tubes. Extramedullary parts of T-tubes with perpendicular flanges prevent dislocation while also acting as a gutter that directs the fluid and keep the subarachnoid space open. According to the preoperative MRI, which showed membrane within the syrinx, two tubes were inserted providing drainage from both syrinx compartments. The membrane was fenestrated, but there is no guarantee that it would stay open. In standard syringosubarachnoid shunt, the catheter is inserted by 2-3 cm into the syrinx cavity and subarachnoid space. The shunt catheter has to be long enough (at least 4 cm) and must be sutured to the arachnoid, to lower the risk of shunt dislocation¹⁴. Our shunt is significantly shorter (4.8 mm length) and can be easily trimmed to adapt to the syrinx size. Because the T-tube is designed with flanges, after insertion and dura closure, it stays stable in myelotomy without additional fixation. Short length and proportionally wide lumen facilitate drainage with less possibility of clogging. Indeed, Poiseuille's law shows that the volume flow rate is exponentially

proportional to radius (r^4) and inversely correlated with tube length. Important contributors to shunt malfunction are occlusion from arachnoiditis and adhesions around the catheter tip. We suppose that our technique can minimize scarring and reduce the possibility of this complication, as the T-tube is significantly shorter and does not require suturing to the arachnoid to prevent migration. Furthermore, the use of the myringotomy tube by its nature avoids shunt-induced complications at distant body cavities (peritoneal, pleural)⁶. Our minimally invasive approach with small skin incision, unilateral dissections of paravertebral muscles, limited removal of bone structures (one-level hemilaminectomy) and ligamentum flavum enables maximal preservation of normal anatomy and less surgery-related trauma, fibrosis, infection, and spinal instability¹⁵. As the proprioception and vibration were already preoperatively affected, we chose a dorsal midline approach. This approach is advocated by many authors as it implies the least invasive and minimally morbid exposure to the centrally placed lesions. However, our patient complained of numbness and tingling in the right leg during two weeks postoperatively. The use of dorsal root entry zone myelotomy would be an alternative option¹⁵⁻¹⁸.

The idea of syringosubarachnoid shunt using a few foreign materials as possible is not new. In Echol's method, a drain made by twisting several tantalum sutures together was inserted into the syrinx and brought out through another opening. The ends of the drain were sutured to the deep surface of the dura and the dura was closed tightly^{19,20}. In another recent study, the silastic wedges were used to preserve patency of the communication between the syrinx cavity and the subarachnoid space by preventing healing of the myelotomy edges and by maintaining an artificial conduit between the syrinx cavity and the subarachnoid space²¹. However, we consider that currently, myringotomy tubes are most suitable for this task.

Conclusion

Our minimally invasive treatment of syringomyelia using the Richards modified myringotomy T-tubes is an effective method for idiopathic septated syrinx without evident underlying cause. However, long-term follow-up and more patients are necessary for definitive evaluation of this technique.

References

- Vandertop WP. Syringomyelia. *Neuropediatrics*. 2014;45:3-9. doi: 10.1055/s-0033-1361921.
- Kyoshima K, Kuroyanagi T, Oya F, Kamijo Y, El-Noamany H, Kobayashi S. Syringomyelia without hindbrain herniation: tight cisterna magna. Report of four cases and a review of the literature. *J Neurosurg*. 2002;96:239-49. doi: 10.3171/spi.2002.96.2.0239.
- Giner J, Pérez López C, Hernández B, Gómez de la Riva Á, Isla A, Roda JM. Update on the pathophysiology and management of syringomyelia unrelated to Chiari malformation. *Neurologia*. 2019;34:318-25. doi: 10.1016/j.nrl.2016.09.010.
- Berliner J, Hemley S, Najafi E, Bilston L, Stoodley M, Lam M. Abnormalities in spinal cord ultrastructure in a rat model of post-traumatic syringomyelia. *Fluids Barriers CNS*. 2020; 17:11. doi: 10.1186/s12987-020-0171-4.
- Ventureyra EC, Tekkök IH. Syringostomy using myringostomy tube: technical note. *Neurosurgery*. 1997;41:495-7. doi: 10.1097/00006123-199708000-00039.
- Leschke JM, Mumert ML, Kurpad SN. Syringosubarachnoid shunting using a myringotomy tube. *Surg Neurol Int*. 2016;7 Suppl 1:S8-S11. doi: 10.4103/2152-7806.173559.
- Tassigny D, Abu-Serieh B, Fofe DT, Born J, Milbouw G. Shunting of syringomyelic cavities by using a myringotomy tube: technical note and long-term results. *World Neurosurg*. 2017;98:1-5. doi: 10.1016/j.wneu.2016.10.067.
- Clarke EC, Stoodley MA, Bilston LE. Changes in temporal flow characteristics of CSF in Chiari malformation type I with and without syringomyelia: implications for theory of syrinx development. *J Neurosurg*. 2013;118:1135-40. doi: 10.3171/2013.2.JNS12759.
- Broadbelt AR, Stoodley MA, Watling AM, Tu J, Jones NR. Fluid flow in an animal model of post-traumatic syringomyelia. *Eur Spine J*. 2003;12:300-6. doi: 10.1007/s00586-002-0492-9.
- Sayal PP, Zafar A, Carroll TA. Syringomyelia secondary to „occult“ dorsal arachnoid webs: report of two cases with review of literature. *J Craniovertebr Junction Spine*. 2016;7:101-4. doi: 10.4103/0974-8237.181862.
- Heiss JD, Snyder K, Peterson MM, Patronas NJ, Butman JA, Smith RK, *et al.* Pathophysiology of primary spinal syringomyelia. *J Neurosurg Spine*. 2012;17:367-80. doi: 10.3171/2012.8.SPINE111059.
- Davidson KA, Rogers JM, Stoodley MA. Syrinx to subarachnoid shunting for syringomyelia. *World Neurosurg*. 2018; 110:e53-9. doi: 10.1016/j.wneu.2017.09.205.
- Batzdorf U, Klekamp J, Johnson JP. A critical appraisal of syrinx cavity shunting procedures. *J Neurosurg*. 1998;89:382-8. doi: 10.3171/jns.1998.89.3.0382.
- Soleman J, Roth J, Constantini S. Syringo-subarachnoid shunt: how I do it. *Acta Neurochir (Wien)*. 2019;161:367-70. doi: 10.1007/s00701-019-03810-x.

15. Gezen F, Kahraman S, Ziyal IM, Canakçi Z, Bakir A. Application of syringosubarachnoid shunt through key-hole laminectomy. Technical note. *Neurosurg Focus*. 2000;8:E10. doi: 10.3171/foc.2000.8.3.10.
16. Prestor B, Benedicic M. Electrophysiologic and clinical data support the use of dorsal root entry zone myelotomy in syringosubarachnoid shunting for syringomyelia. *Surg Neurol*. 2008;69:466-73. doi: 10.1016/j.surneu.2007.02.056.
17. Prestor B, Zgur T, Dolenc VV. Subpially recorded cervical spinal cord evoked potentials in syringomyelia. *Electroencephalogr Clin Neurophysiol*. 1991;80:155-8. doi: 10.1016/0168-5597(91)90153-o.
18. Prestor B, Golob P. Intra-operative spinal cord neuromonitoring in patients operated on for intramedullary tumors and syringomyelia. *Neurol Res*. 1999;21:125-9. doi: 10.1080/01616412.1999.11740908.
19. Kirgis HD, Echols DH. Syringo-encephalomyelia; discussion of related syndromes and pathologic processes, with report of a case. *J Neurosurg*. 1949;6:368-75. doi: 10.3171/jns.1949.6.5.0368.
20. Peterson MM, Craciun L, Heiss JD. Echols' procedure for treating syringomyelia: case report and historical review. *J Neurosurg Spine*. 2009 Jan;10(1):73-8. doi: 10.3171/2008.10.SPI08291.
21. Soo TM, Sandquist L, Tong D, Barrett R. Surgical treatment of idiopathic syringomyelia: silastic wedge syringosubarachnoid shunting technique. *Surg Neurol Int*. 2014;5:114. doi: 10.4103/2152-7806.137536.

Sažetak

MINIMALNO INVAZIVNO LIJEČENJE IDIOPATSKE SIRINGOMIJELIJE
UPORABOM VENTILACIJSKIH T-CJEVČICA ZA BUBNJIĆ:
PRIKAZ SLUČAJA I OPERATIVNE TEHNIKE

D. Jugović, R. Bošnjak, K. Rotim i G.C. Feigl

Siringomijeliju predstavlja stvaranje šupljina ispunjenih tekućinom unutar kralježnične moždine. Širenje šupljine često dovodi do pojave neuroloških poremećaja koji se postupno pogoršavaju. Operativno liječenje je usmjereno na otklanjanje uzroka siringomijelije, ako je taj uzrok poznat. Međutim, malo se zna o idiopatskoj siringomijeliji koja zahtijeva poseban tretman. U našem članku opisujemo alternativnu, minimalno invazivnu metodu liječenja velike simptomatske idiopatske vratno-prsne siringomijelije. Prikazujemo slučaj 44-godišnjeg bolesnika bez prethodno poznate ozljede, upale ili drugih bolesti kralježnične moždine, koji se žalio na bolove u prsnoj kralježnici. Zbog pogoršanja bolova i slabosti lijeve noge učinjena je magnetska rezonanca koja je pokazala veliku pregrađenu siringomijeliju u razini od 5. do 7. prsnog kralješka i kranijalno posljedičnu hidromijeliju. Primijenili smo minimalno invazivnu tehniku drenaže sirinksa u subarahnoidni prostor uporabom dviju ventilacijskih cjevčica za bubnjić (Richardsove modificirane T-cjevčice). Snimke nakon operacije su pokazale značajno smanjenje sirinksa, a kontrolni pregled nakon šest mjeseci poboljšanje neuroloških simptoma. Ova minimalno invazivna operacija siringomijelije se pokazala učinkovitom metodom u liječenju idiopatskog, membranom pregrađenog sirinksa nepoznate etiologije. Međutim, za konačnu procjenu ove metode potrebno je duže praćenje i veći broj slučajeva.

Ključne riječi: *Siringomijelija; Magnetska rezonancija, snimanje; Cerebrospinalni likvor, kirurški šantovi; Srednje uho, ventilacija*