

# Resection of a pleuropulmonary solitary fibrous tumor via video-assisted thoracoscopic surgery (VATS) : A case report

---

Bečejac, Tomislav; Jalšovec, Dubravko; Vrančić, Marko; Gospić, Marko; Penović, Toni; Danolić, Damir

Conference presentation / Izlaganje na skupu

Permanent link / Trajna poveznica: <https://um.nsk.hr/um:nbn:hr:220:194396>

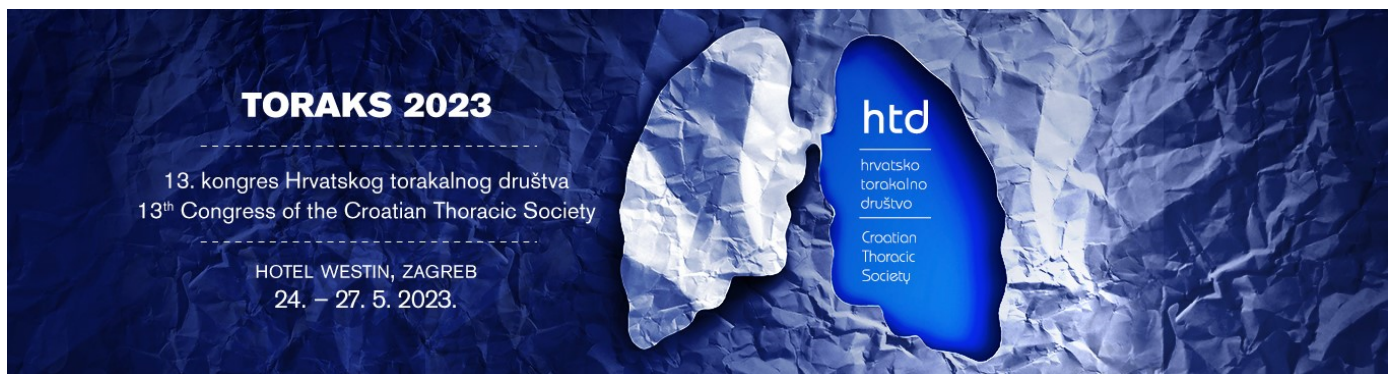
Rights / Prava: [In copyright](#)/[Zaštićeno autorskim pravom](#).

Download date / Datum preuzimanja: **2025-02-20**



Repository / Repozitorij:

[Repository of the Sestre milosrdnice University Hospital Center - KBCSM Repository](#)



# RESECTION OF A PLEUROPULMONARY SOLITARY FIBROUS TUMOR VIA VIDEO-ASSISTED THORACOSCOPIC SURGERY (VATS)-A CASE REPORT

BEČEJAC T.<sup>1</sup>, Jalšovec D.<sup>1</sup>, Vrančić M.<sup>1</sup>, Gospić M.<sup>3</sup>, Penović T.<sup>1</sup>, Danolić D.<sup>2</sup>

<sup>1</sup> University Hospital Centre Zagreb, ZAGREB, Croatia  
*Department of Thoracic Surgery*

<sup>2</sup> Sestre Milosrdnice University Hospital Center, ZAGREB, Croatia  
*University Hospital for Tumours*

<sup>3</sup> Clinical Hospital Center Rijeka, Rijeka, Croatia  
*Department of Thoracic Surgery*

## Objective:

Introduction: Pleuropulmonary solitary fibrous tumors are rare mesenchymal neoplasms with intermediate biological potential and rarely metastasize. In some cases (10-30%), solitary fibrous tumors can recur or metastasize. The risk factors include large tumors of at least 10 cm in size, necrotic nonpedunculated tumors, severe atypia, mitotic count of at least four mitoses per 10 high-power fields, and a Ki67 labeling index of at least 2%. Both female and male patients are affected, usually aged 40-70 years. Pleural tumors are usually discovered incidentally and are mostly asymptomatic. They are well-defined on CT scans, often can be lobulated, and show low metabolic activity on PET/CT scans. Radical surgical resection is the best treatment method, and long-term surveillance is advised.



Case report: We present a case of a 72-year-old male patient with a suspected costal pleura tumor. After a covid infection, a chest X-ray revealed a nodal lesion in the left lower lung lobe. MSCT and PET/CT scans showed an expansive tumor of costal pleura in the left thoracic cavity, 4x2,2x3,8 cm in size and with increased metabolism of FDG glucose but of low intensity (SUVmax=3,0), suggesting a well-differentiated tumor or a tumor of low malignant potential. Transthoracic biopsy under MSCT guidance was inconclusive and revealed a nodular mesotel-hystiocyte hyperplasia. Surgical resection was then indicated, and an uniportal VATS (UVATS) procedure was selected.

Intraoperative findings showed not a costal pleural tumor but, in fact, a pedunculated tumor of a left lower lung lobe. UVATS atypical left lower lung lobe resection was then performed. Pathohistological analysis revealed a solitary fibrous tumor with up to 4 mitoses per 10 high-power fields and necrosis in more than 10% of tumor mass (around 40%). Proliferative activity measured by Ki67 index was low, tumor cells were STAT6 positive, mostly CD34 positive, and CKAE1/AE3, SMA, Desmin, and S-100 markers were negative. Using a risk stratification model classification of solitary fibrous tumors which consists of groups of low, intermediate, and high risk for metastasis formation, the tumor was classified as a tumor with an intermediate risk of metastasizing. The patient was discharged from the hospital on the 4<sup>th</sup> postoperative day. Oncologist indicated long-term surveillance and no chemoradiotherapy was necessary.

Conclusions: VATS is an excellent procedure for radical surgical resections of smaller pleuropulmonary solitary fibrous tumors. It is less painful, provides early patient mobilization with fewer perioperative complications, and enables a shorter hospital stay.

Keywords: solitary fibrous tumor, transthoracic biopsy, VATS

# TORAKS 2023

13. kongres Hrvatskog torakalnog društva  
13<sup>th</sup> Congress of the Croatian Thoracic Society

HOTEL WESTIN, ZAGREB  
24. – 27. 5. 2023.



htd

hrvatsko  
torakalno  
društvo

Croatian  
Thoracic  
Society