

# Transient clitoromegaly in an extremely preterm twin infant with popliteal pterygium

---

La Grasta Sabolić, Lavinia; Kovačević, Ana; Trtanj, Lucija Ana; Valent Morić, Bernardica; Tumbri, Jasna

Source / Izvornik: **Pediatric Endocrinology Diabetes and Metabolism, 2024, 30, 163 - 167**

Journal article, Published version

Rad u časopisu, Objavljena verzija rada (izdavačev PDF)

<https://doi.org/10.5114/pedm.2024.142585>

Permanent link / Trajna poveznica: <https://urn.nsk.hr/urn:nbn:hr:220:926457>

Rights / Prava: [In copyright](#)/[Zaštićeno autorskim pravom.](#)

Download date / Datum preuzimanja: **2025-01-06**



Repository / Repozitorij:

[Repository of the Sestre milosrdnice University  
Hospital Center - KBCSM Repository](#)

# Transient clitoromegaly in an extremely preterm twin infant with popliteal pterygium

Przemijający przerost łechtaczki u skrajnego wcześniaka bliźniaka z objawem popliteal pterygium

<sup>1</sup>Lavinia La Grasta Sabolić, <sup>2</sup>Ana Kovačević, <sup>3</sup>Lucija Ana Trtanj, <sup>1,2</sup>Bernardica Valent Morić, <sup>3</sup>Jasna Tumbri

<sup>1</sup>Department of Paediatrics, Sestre milosrdnice University Hospital Center, Zagreb, Croatia

<sup>2</sup>Catholic University of Croatia's School of Medicine, Zagreb, Croatia

<sup>3</sup>Department of Obstetrics and Gynaecology, Sestre milosrdnice University Hospital Center, Zagreb, Croatia

## Abstract

Clitoromegaly can be congenital or acquired, and it is usually associated with exposure to androgen excess. Pathophysiological mechanisms responsible for transient clitoromegaly in premature female infants have not been fully elucidated. Herein, we present the case of an extremely premature female twin infant, with an extensive web of skin on the back of the left leg, hypoplastic left labia majora, and normal clitoris appearance at birth. At the age of 48 days, clitoral enlargement was observed. Significantly elevated levels of gonadotropins, testosterone, and dehydroepiandrosterone sulphate (DHEAS) were recorded. 17-hydroxyprogesterone (17OHP) was unremarkable, and anti-Müllerian hormone (AMH) was low, in accordance with normal female karyotype. Ovaries were not visualised ultrasonographically. During the following weeks, gradual normalisation of gonadotropin, testosterone, and DHEAS levels was accompanied by regression of clitoromegaly. As described in this case, transient clitoral enlargement may appear in extremely premature female infants due to transitory elevated androgens of ovarian and adrenal origin.

**Key words:** preterm neonate, transient clitoromegaly, popliteal pterygium.

## Introduction

The rate of preterm birth ranges from 4 to 16% worldwide. In 2020, approximately 13.4 million neonates were born prior to completing 37 weeks of gestation [1]. Neonates born before 28 weeks of gestation are considered extremely premature. In these newborns, enlargement of the clitoris without a recognisable conventional cause is sporadically described.

Absence of a standard clitoromegaly definition, subjectivity in visual estimate, and inconsistencies in measurement technique make the objective assessment of clitoral enlargement in neonates and infants difficult [2]. Despite racial and ethnic differences [3, 4], clitoral length > 9 mm and width > 6 mm in full-term infants are considered abnormal. Recently, the first set of reference values for premature female neonates was published, defining clitoromegaly as clitoral length > 6.5 mm, with values ≥8 mm requiring rapid investigation [5]. Falsely perceived clitoromegaly in preterm newborns may be the result of complete clitoris development by the 27<sup>th</sup> week of gestation, with surrounding labial tissues and vulvar subcutaneous fat still underdeveloped at that time [2]. Hypoplasia of the labia majora, as a feature of popliteal pterygium syndrome (PPS), which is a rare autosomal dominant disorder with diverse clinical

presentations including orofacial, skin, and genital abnormalities [6], may also contribute to the impression of an enlarged clitoris. While the presence of clitoromegaly at birth reflects excess prenatal androgen exposure of foetal (congenital adrenal hyperplasia), maternal, or placental origin, or rarely a non-hormonal condition (Beckwith-Wiedemann syndrome, clitoral cyst, or tumour), the exact underlying mechanisms for postnatal transient clitoromegaly in infants born prematurely are still insufficiently understood [7–10].

In this report, alongside presenting a case of an extremely premature twin infant with popliteal pterygium and transient clitoral enlargement associated with elevated circulating androgen levels, we highlight the current shortcomings in our understanding of sex hormone physiology in prematurity.

### Bioethical standards

Ethics Committee approval and parents' informed consent for publication were obtained (No approval. 251-29-11-24-12).

## Case presentation

The patient is a female infant born to a 30-year-old mother, from a dichorionic diamniotic twin pregnancy. Because of

Received: 24.02.2024

Accepted: 27.06.2024

Conflict of interest: not declared.

Funding: no external funding.

Ethics approval: The study was approved by the Ethics Committee (No. approval 251-29-11-24-12).

Lavinia La Grasta Sabolić

Department of Pediatrics,

Sestre milosrdnice University Hospital Center,

Catholic University of Croatia's School of Medicine,

Zagreb, Croatia

e-mail: [lavinia.la.grasta.sabolic@gmail.com](mailto:lavinia.la.grasta.sabolic@gmail.com)

163



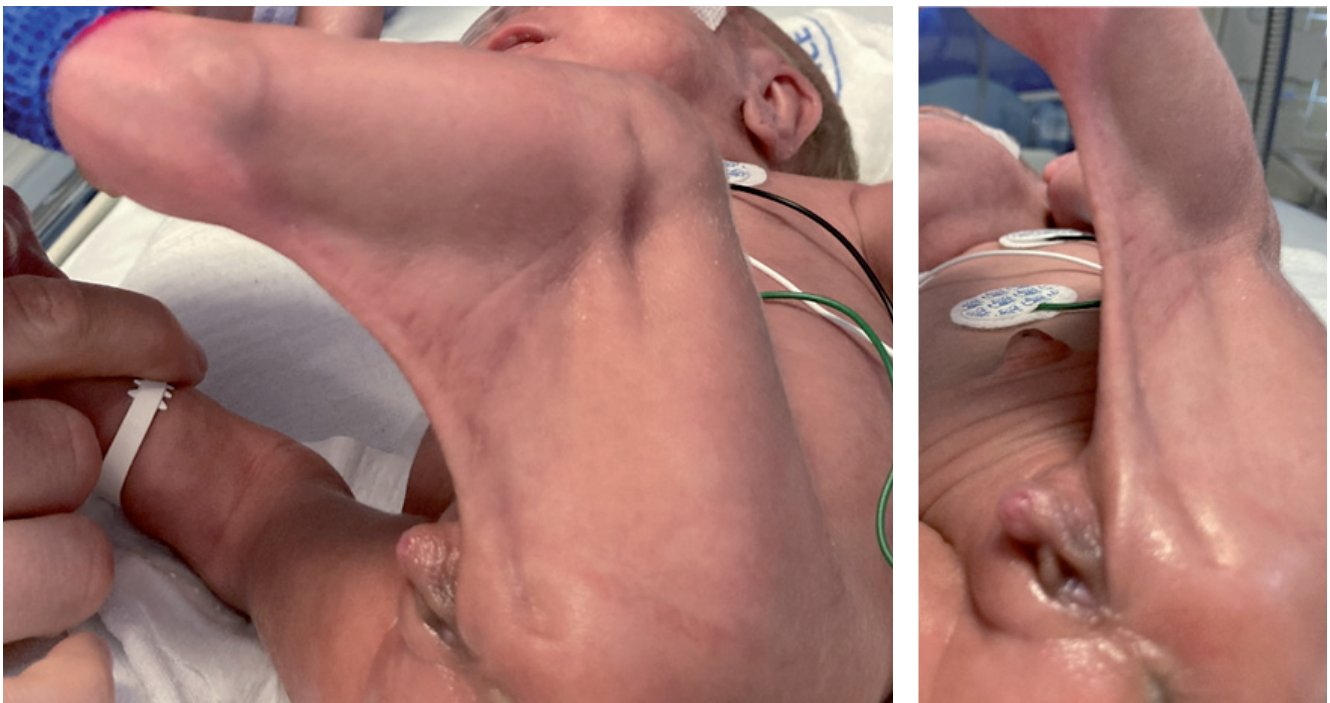
gestational diabetes mellitus, the mother was treated with insulin. Tocolysis was initiated at 27 + 2 weeks of gestation, and subsequently accompanied by parenteral antibiotic therapy. However, preterm delivery occurred, and the patient was born vaginally at 27 + 5 weeks of gestation, as the first female twin (birth weight 992 g, birth length 34 cm, Apgar scores 7 and 9). Due to a prolapsed arm, the patient's twin sister was delivered by caesarean section (birth weight 1095 g, birth length 36 cm, Apgar scores 7 and 9).

Immediately after birth, webbing of the skin from the ischium to the heel, on the back of the patient's left leg was observed, with hypoplastic left labia majora, and without marked clitoromegaly. Cleft lip/palate or other visible anomalies of PPS were absent. Clinical exome sequencing performed subsequently did not reveal pathogenic variants in the *IRF6* gene. The patient required non-invasive ventilation, surfactant and caffeine administration, ampicillin and gentamicin for suspected perinatal infection, insulin therapy for hyperglycaemia, as well as spironolactone and hydrochlorothiazide for bronchopulmonary dysplasia. Additional complications included neonatal jaundice, anaemia requiring red blood cell concentrate transfusion, patent foramen ovale, and patent ductus arteriosus (PDA). Fluconazole prophylaxis, oral erythromycin for feeding intolerance, and acetaminophen in the attempt of pharmacological PDA closure were also employed.

Unexpectedly, clitoris enlargement (length 1.2 cm, width 0.7 cm) was noted at the age of 48 days (corrected gesta-

tional age [CGA] 34 + 4 weeks) (Fig. 1). There were no other features of virilisation, nor obvious hypogastric/labial/upper leg swelling. 17-hydroxyprogesterone (17OHP) was unremarkable. However, luteinising hormone (LH), follicle stimulating hormone (FSH), testosterone, and dehydroepiandrosterone sulphate (DHEAS) were elevated (Table I). Anti-Müllerian hormone (AMH) was low, in accordance with XX female karyotype. Internal genitalia and left kidney were not visualised on ultrasound. High levels of LH, FSH, testosterone, and DHEAS subsequently normalised (Table I), which was accompanied by regression of clitoromegaly (Fig. 2). At the age of 4 months and 3 weeks (corrected age [CA] 2 months) the right ovary and ipsilateral segment of the uterus were ultrasonographically detected inside the patient's inguinal hernial sac. A week later, repair of the right-sided inguinal hernia containing ovary and fallopian tube was performed. During surgery, however, the uterus was not visualised. Multi-step surgical correction of popliteal pterygium, transcatheter closure of patent ductus arteriosus, and repair of the left-sided inguinal hernia (CA 20 months 1 week) were performed as well.

Interestingly, at the age of 1 month and 3 weeks (CGA 34 weeks), the patient's twin sister was ultrasonographically diagnosed with simple ovarian cyst. She did not have clitoromegaly, hypogastric/labial/upper leg swelling, breast enlargement, or vaginal bleeding. Due to ovarian cyst enlargement and right-sided inguinal hernia, she was surgically treated at the age of 78 days (CA 38 + 6 weeks).

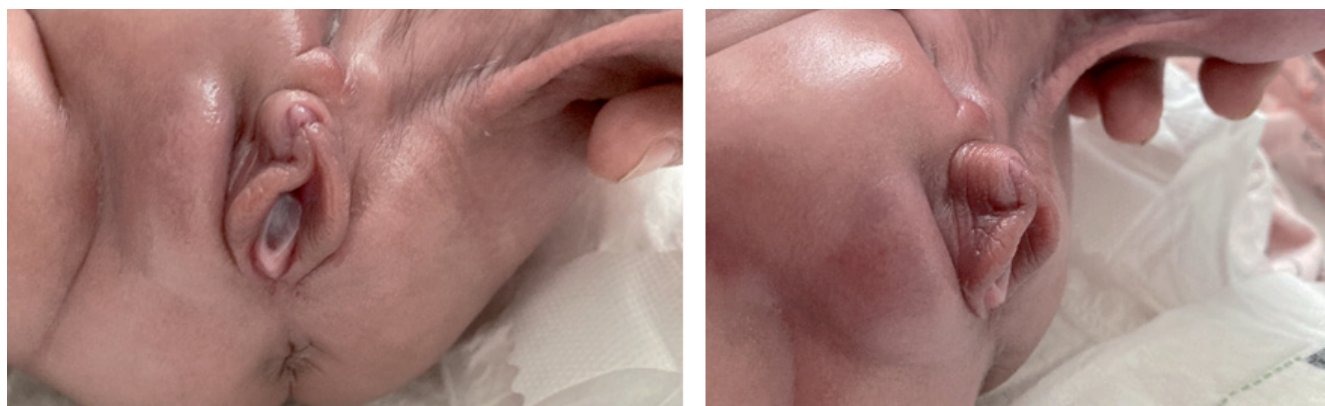


**Figure 1.** Clitoromegaly at the age of 48 days (corrected gestational age 34 + 4 weeks) in a premature infant with popliteal pterygium

**Table I.** Diagnostic workup at the onset of clitoromegaly and during follow-up

Test	Corrected gestational age (weeks + days)				Corrected age post term (months)	Reference range (neonatal age)
	34 + 4	35 + 4	37 + 4	39 + 5		
17OHP (nmol/l)	26.4	13.7			4	< 36.3
DHEAS ( $\mu$ mol/l)	17.3	7.68				2.0–7.3
LH (IU/l)	139.0	195.0	149.0	19.0	<0.3	0.3–124
FSH (IU/l)	> 200	> 200	> 200	69.3	2.0	2.6–181
Testosterone (nmol/l)	9.3	6.4	8.5	4.4	< 0.4	< 1.7
Oestradiol (pmol/l)		105.0			< 27	73–512
AMH (pmol/l)		2.0				0-7.6
Karyotype			46,XX			

17OHP – 17-hydroxyprogesterone; DHEAS – dehydroepiandrosterone sulphate; LH – luteinising hormone; FSH – follicle stimulating hormone; AMH – anti-Müllerian hormone



**Figure 2.** Regression of clitoromegaly at the age of 91 days (corrected gestational age 40 + 6 weeks)

## Discussion

Potential for clitoromegaly overdiagnosis in extremely premature female infants is high due to yet underdeveloped labial tissues and lack of vulvar subcutaneous fat [2]. Despite the popliteal pterygium with left labia majora hypoplasia, which could additionally enhance the impression of clitoral enlargement, in our patient the diagnostic criteria for clitoromegaly were fulfilled.

Enlarged clitoris present at birth, as an isolated feature or combined with various degrees of genital ambiguity, requires prompt evaluation. It is important to avoid congenital adrenal hyperplasia (CAH) related salt-wasting crisis, and to rule out the 46,XY difference in sex development (DSD) with significant

undervirilisation. The diagnostic procedure usually involves detailed pre- and postnatal history, physical examination, electrolyte and hormone analysis, karyotyping, and diagnostic imaging. There are some reports of transient clitoromegaly in infants, in which the aforementioned causes have been ruled out, as was the case in our patient, but the underlying mechanisms remained obscure. Greaves *et al.* described 2 premature female infants with isolated clitoral enlargement and initial laboratory findings pointing either to less common forms of CAH or persistent foetal adrenal zone activity [7]. Due to the transient nature of clitoromegaly, its presence was attributed to the latter. Furthermore, in 3 premature female infants with clitoromegaly, who were initially treated as CAH, genetic analysis revealed no CYP21 mutations. Hydrocortisone therapy was discontinued,

with unremarkable clinical course thereafter [8]. Dumont *et al.* presented a case of clitoral enlargement with increased androgen levels of unknown aetiology, which spontaneously resolved with normalisation of androgen levels [9]. Nerré *et al.* acknowledged ovarian androgen involvement in 2 extremely premature girls with transient clitoral hypertrophy [10]. Regardless of whether clitoromegaly was observed at birth [7, 10] or postnatally [8, 9], the unique characteristic of all the previously mentioned cases was the transient nature of clitoral enlargement.

However, the exact mechanisms behind this transient phenomenon in extremely preterm infants are not yet fully understood. It seems that premature birth interrupts the physiological course of foetal hypothalamic-pituitary-gonadal (HPG) axis maturation [11]. Gonadotropin levels normally peak at mid-gestation and subsequently decrease toward birth, probably as a result of gradual increase in the production of placental oestrogens toward the end of gestation. This trend is abruptly terminated by a preterm delivery, at a point of yet insufficiently matured HPG axis, which offers a reasonable explanation for exaggerated and prolonged postnatal gonadotropin surge in premature infants [12]. Only rarely, preterm ovarian hyperstimulation syndrome (POHS) characterised by high serum gonadotropin and oestradiol levels, ovarian cyst/cysts formation and hypogastric/upper leg swelling develops. In some premature female infants with accentuated LH surge or increased LH to FSH ratio, excessive androgen production was described [13]. The persistence of foetal adrenal zone may also create a hyperandrogenaemic state due to higher DHEAS levels [14, 15]. Our patient's findings (transiently elevated gonadotropins, testosterone, and to a lesser degree DHEAS) are consistent with the aforementioned pathophysiological mechanisms. Other proposed mechanisms behind transient clitoromegaly include altered binding protein concen-

trations, differences in end organ sensitivity, and localised conversion of foetal steroids to more potent androgens in the genitalia [2]. It should be mentioned that our patient received red blood cell concentrate transfusion in NICU. Although a case of a female neonate who developed clitoromegaly during the second month of life after repeated whole blood transfusions from her father was described [16], the authors of a recent retrospective multicentre cohort study concluded that sex hormones delivered via plasma transfusions from adult male donors do not significantly impact the circulating plasma hormone concentrations in preterm infants [17].

We were not able to visualise our patient's ovaries at the time of clitoromegaly onset, but approximately at the same time, a large simple cyst of the right ovary was detected on abdominal ultrasound in the patient's twin sister. She developed neither POHS nor clitoromegaly, but due to the cyst enlargement she was eventually surgically treated. As mentioned before, our patient and her sister were fraternal twins, and they had no major differences in their clinical courses regarding prematurity and NICU stay, allowing us to speculate that their phenotypic variability was genetically determined. Because recent discoveries have pointed to androgen-led ovarian programming and its possible association with subsequent development of conditions such as polycystic ovary syndrome (PCOS) [18], dedicated follow-up of female neonates with intrauterine/early postnatal androgen exposure is required.

In conclusion, development of the HPG axis in the prenatal period and early infancy is influenced by premature birth, which interrupts this physiological process in its inception. Consequently, some extremely premature infants present with clitoromegaly, which can be transient. After exclusion of CAH and DSD, observation is the most appropriate strategy, because hyperandrogenism and clitoromegaly usually regress with time.

## References

- Ohuma EO, Moller AB, Bradley E, et al. National, regional, and worldwide estimates of preterm birth in 2020, with trends from 2010: a systematic analysis. *Lancet* 2023; 402: 1261–1271. doi: 10.1016/S0140-6736(23)00878-4.
- Gupta M, Chambers C, O'Flynn O'Brien K, et al. Clitoromegaly in premature infants: is it truly pathologic? *Acad J Ped Neonatol* 2021; 10: 555843.
- Jarrett OO, Ayoola OO, Jonsson B, et al. Country-based reference values and international comparisons of clitoral size in healthy Nigerian newborn infants. *Acta Paediatr* 2015; 104: 1286–1290. doi: 10.1111/apa.13219
- Mondal R, Chatterjee K, Samanta M, et al. Clitoral length and anogenital ratio in Indian newborn girls. *Indian Pediatr* 2016; 53: 299–303. doi: 10.1007/s13312-016-0840-1
- Castets S, Nguyen KA, Plaisant F, et al. Reference values for the external genitalia of full-term and pre-term female neonates. *Arch Dis Child Fetal Neonatal Ed* 2021; 106: 39–44. doi: 10.1136/archdischild-2019-318090
- Gorlin RJ, Sedano HO, Cervenka J. Popliteal pterygium syndrome: a syndrome comprising cleft lip-palate, popliteal and intercrural pterygia, digital and genital anomalies. *Pediatrics* 1968; 41: 503–509.
- Greaves R, Kanumakala S, Read A, Zacharin M. Genital abnormalities mimicking congenital adrenal hyperplasia in premature infants. *J Paediatr Child Health* 2004; 40: 233–236. doi: 10.1111/j.1440-1754.2004.00345.x.
- Couch R, Girgis R. Postnatal virilization mimicking 21-hydroxylase deficiency in 3 very premature infants. *Pediatrics* 2012; 129: e1364–e1367. doi: 10.1542/peds.2011-1895
- Dumont T, Black AY, Ahmet A, Fleming NA. Isolated transient neonatal clitoromegaly with hyperandrogenism of unknown etiology. *J Pediatr Adolesc Gynecol* 2009; 22: 142–145. doi: 10.1016/j.jpog.2009.01.066.
- Nerré AL, Bétrémieux P, Nivot-Adamiak S. Case report of clitoral hypertrophy in 2 extremely premature girls with an ovarian cyst. *Pediatrics* 2017; 140: 20161807. doi: 10.1542/peds.2016-1807.
- Lanciotti L, Cofini M, Leonardi A, et al. Up-to-date review about minipuberty and overview on hypothalamic-pituitary-gonadal axis activation in fetal and neonatal life. *Front Endocrinol (Lausanne)* 2018; 9: 410. doi: 10.3389/fendo.2018.00410.

12. Greaves RF, Pitkin J, Ho CS, et al. Hormone modeling in preterm neonates: establishment of pituitary and steroid hormone reference intervals. *J Clin Endocrinol Metab* 2015; 100: 1097–1103. doi: 10.1210/jc.2014-3681.
13. Greaves R, Hunt RW, Zacharin M. Transient anomalies in genital appearance in some extremely preterm female infants may be the result of foetal programming causing a surge in LH and the over activation of the pituitary-gonadal axis. *Clin Endocrinol (Oxf)* 2008; 69: 763–768. doi: 10.1111/j.1365-2265.2008.03298.x.
14. Midgley PC, Russell K, Oates N, et al. Activity of the adrenal fetal zone in preterm infants continues to term. *Endocr Res* 1996; 22: 729–733. doi: 10.1080/07435809609043769.
15. Geliebter R, Derrick K, Drzewiecki BA, et al. New onset clitoromegaly in a preterm infant: premature ovarian hyperstimulation syndrome. *Mathews J Pediatr* 2021; 6: 252021.
16. Akçam M, Topaloglu AK. Extremely immature infant who developed clitoromegaly during the second month of her postnatal life probably due to frequent whole blood transfusion from an adult male. *Pediatr Int* 2003; 45: 347–348. doi: 10.1046/j.1442-200x.2003.01731.x.
17. Nilsson AK, Hellgren G, Sjöbom U, et al. Preterm infant circulating sex steroid levels are not altered by transfusion with adult male plasma: a retrospective multicentre cohort study. *Arch Dis Child Fetal Neonatal Ed* 2022; 107: 577–582. doi: 10.1136/archdisc-hild-2021-323433.
18. Barsky M, Merkison J, Hosseinzadeh P, et al. Fetal programming of polycystic ovary syndrome: Effects of androgen exposure on prenatal ovarian development. *J Steroid Biochem Mol Biol* 2021; 207: 105830. doi: 10.1016/j.jsbmb.2021.105830.