

Nocardia Asteroides Pulmonary Infection: A Case Report

Jajić-Benčić, Ines; Gaćina, Petar; Katalinić-Janković, Vera; Benčić, Ivan

Source / Izvornik: **Acta clinica Croatica, 2002, 41, 259 - 262**

Journal article, Published version

Rad u časopisu, Objavljena verzija rada (izdavačev PDF)

Permanent link / Trajna poveznica: <https://um.nsk.hr/um:nbn:hr:220:118811>

Rights / Prava: [Attribution-NonCommercial-NoDerivatives 4.0 International/Imenovanje-Nekomercijalno-Bez prerada 4.0 međunarodna](#)

Download date / Datum preuzimanja: **2025-01-31**



Repository / Repozitorij:

[Repository of the Sestre milosrdnice University Hospital Center - KBCSM Repository](#)

NOCARDIA ASTEROIDES PULMONARY INFECTION: A CASE REPORT

Ines Jajić-Benčić¹, Petar Gaćina², Vera Katalinić-Janković³ and Ivan Benčić⁴

¹Department of Microbiology, Parasitology and Hospital Infections, ²Department of Hematology, Sestre milosrdnice University Hospital, ³Department of Mycobacteriology, Croatian National Institute of Public Health, ⁴University Hospital of Traumatology, Zagreb, Croatia

SUMMARY – Presentation is made of a 53-year-old woman with pulmonary infection caused by *Nocardia asteroides*. Tracheal aspirate was obtained and examined microbiologically. Direct smear of the tracheal aspirate stained with Gram stain revealed gram-positive branched filamentous hyphae and numerous leukocytes. Pure culture of colonies of a chalky white appearance grew on the blood agar after prolonged incubation. The Gram stained direct slide prepared from the culture showed gram-positive branching filaments. The microorganism was identified as *Nocardia asteroides* by standard methods.

Key words: *Nocardia infections – diagnosis; Pneumonia, bacterial – diagnosis; Pneumonia, bacterial – microbiology*

Introduction

Pulmonary nocardiosis is a severe infection due to *Nocardia* spp., microorganisms that may behave as either opportunistic or primary pathogens. It is a community-acquired, late-presenting infection, occurring most frequently in patients who are severely immunocompromised¹.

Nocardia spp. are ubiquitous, soil-borne, aerobic, very fine and branching gram-positive and weakly acid-fast filamentous actinomycetes with a tendency to fragment into bacillary and coccoid forms².

Care Report

Our patient was a 53-year-old woman, diabetic, without other serious illnesses in her case history. Several months before, she had become forgetful and confused. She complained of getting tired easily and having an increased need of sleep. She denied headache, nausea, vom-

iting, and loss of consciousness. Magnetic resonance imaging (MRI) of the brain revealed an expansive process in the frontal region bilaterally. Craniotomy with reduction of a tumor mass was performed. Pathohistologic examination revealed a diffuse, large B-cell non-Hodgkin lymphoma. Antiedematous therapy with mannitol infusion, dexamethasone and phenobarbitone was initiated, however, the patient's condition deteriorated. She developed fever (38 °C), tachycardia and tachypnea, with the Glasgow Coma Scale (GCS) 6. Laboratory tests showed findings indicating acute infection: leukocytosis 14.5x10⁹/L with 87% of neutrophils, erythrocyte sedimentation rate (ESR) 105 mm/h, CRP 68.9 mg/L, fibrinogen 7.3 g/L. Transaminase values were also elevated (AST 114 U/L and ALT 255 U/L).

The following samples for bacteriologic analysis were obtained: blood, cerebrospinal fluid (CSF), tracheal aspirate and urine as well as nasal and pharyngeal swabs. Blood and CSF cultures remained sterile. A large number of *Streptococcus agalactiae* were isolated from the pharyngeal swab culture. *Staphylococcus aureus* was isolated from the nasal swab culture, and *Enterococcus* sp. from urine culture (>10 E5/ml). Triple antibiotic therapy with amoxicillin + clavulanic acid, gentamicin and metronidazole was applied, but no improvement in the patient's condition was not-

Correspondence to: Ines Jajić-Benčić, M.D., M.S., Department of Microbiology, Parasitology and Hospital Infections, Sestre milosrdnice University Hospital, Vinogradska c. 29, HR-10000 Zagreb, Croatia
E-mail: ines.jajic-bencic@zg.hinet.hr

Received April 26, 2002, accepted in revised form June 12, 2002

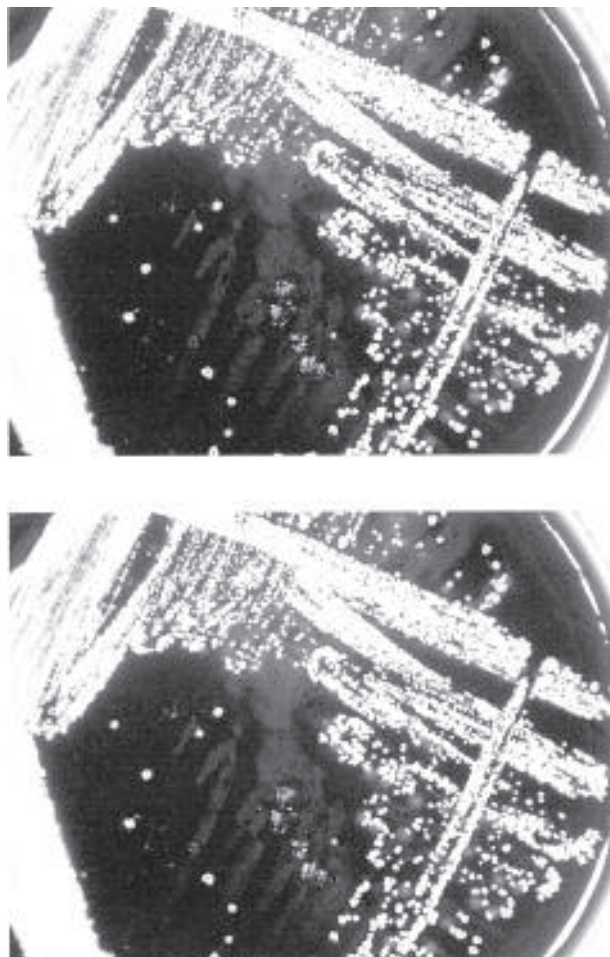


Fig. 1. *Nocardia asteroides* colonies with a chalky white appearance.

ed. X-ray of the lungs showed no visible recent foci or infiltrates. Direct smear of tracheal aspirate was stained with Gram stain and examined microscopically. The Gram stained smear showed gram-positive branched filamentous hyphae and numerous leukocytes. Culture of tracheal aspirate was done and submitted to prolonged incubation because of the mentioned findings in the direct microscopic preparation. After seven days of incubation, a large number of colonies of a chalky white appearance grew on blood agar in pure culture (Fig. 1). The microorganism was referred to the Department of Mycobacteriology, Croatian National Institute of Public Health, for further identification and was identified as *Nocardia asteroides* by using standard methods. The strain was subcultivated in Löwenstein-Jensen medium and Middlebrook 7H10 agar, and was observed to produce branched vegetative hyphae and aerial hyphae, two important criteria for the establishment of an

organism as member of the genus *Nocardia*. Microscopic examination of the slide preparation showed gram-positive branching filaments (Fig. 2), which were partially acid-fast by the modified Kinyoun procedure. Thin-layer chromatography showed the isolate to contain mesoisomer of di-*amino*pimelic acid as well as galactose and arabinose. The strain failed to hydrolyze casein, xanthine and tyrosine but did hydrolyze esculin and urea, and was resistant to lysozyme. No other bacterial pathogens were isolated from tracheal aspirate. Susceptibility testing of *Nocardia asteroides* was performed, and the strain showed sensitivity to amikacin, amoxicillin-clavulonate, ampicillin, cefotaxime, ciprofloxacin, minocycline and sulfonamides.

Sulfonamide therapy (sulfamethoxazole + trimethoprim, dose 15 mg/kg/day) was instituted immediately^{2,3}.

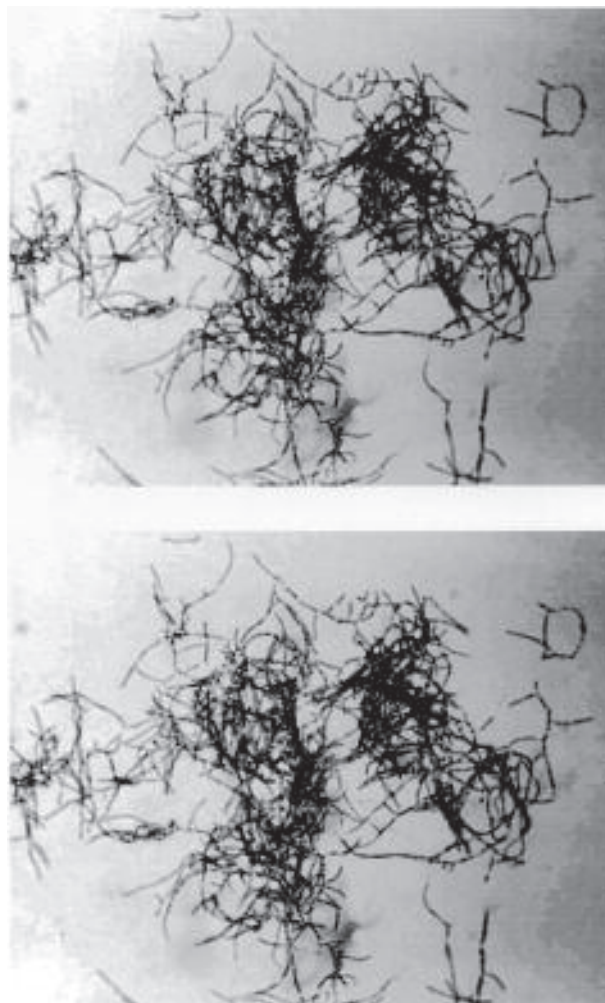


Fig. 2. *Nocardia asteroides* branching filaments. A slide prepared from a culture (Gram stain).

Based on the improved general condition of the patient, it was decided to apply De Angelis chemotherapeutic protocol (intravenous and intrathecal application of methotrexate)^{4,5}. However, the patient's condition deteriorated with tumor progression and progressive pulmonary insufficiency in the form of adult respiratory distress syndrome. The patient died three weeks after the initiation of anti-*Nocardia* therapy. Autopsy was not performed because the family refused it.

Discussion

Since *Nocardia* sp. are ubiquitous microorganisms, the isolation of this microorganism from sputum culture of an immunocompetent host may not always indicate invasive infection but may instead reflect respiratory colonization⁶. Respiratory tract colonization with *Nocardia* sp. has been noted to occur in patients with underlying pulmonary disorders (chronic obstructive pulmonary disease, asthma, bronchiectasis). The development of clinical disease occurs, and the most common clinical presentations caused by *Nocardia* sp. are invasive pulmonary infection and disseminated infection^{1,6}. The development of clinical disease occurs in patients with impaired local pulmonary defense, chronic obstructive pulmonary disease, asthma, bronchiectasis, and alveolar proteinosis. Patients with systemic immunosuppression are also predisposed to the development of invasive pulmonary nocardiosis. Treatment with corticosteroids, cytotoxic agents appear to be an important risk factor for the development of this infection. Invasive pulmonary nocardiosis has been reported to occur in renal and cardiac patients, transplant recipients, and patients with malignant neoplasms, lymphoma, sarcoidosis, collagen vascular diseases (especially systemic lupus erythematosus), dysgammaglobulinemia, chronic granulomatous disease, chronic alcoholism, diabetes mellitus, trauma or surgery, and human immunodeficiency virus infection. Thus, *Nocardia* sp. are uncommon pathogens in humans, involving mainly immunosuppressed or debilitated patients^{1,7-11}.

Our patient had several risk factors for the development of *Nocardia* infection. She was diabetic, was treated with corticosteroids, and had a malignant disease, lymphoma. During the past decade, there has been a marked increase in the number of severely immunocompromised patients. Many of them are extremely susceptible to the development of nocardiosis. Since the number of severely immunocompromised patients shows no tendency to

diminish, *Nocardia* sp. infection will likely continue to emerge as an important opportunistic disease⁶.

Nocardiae are difficult to recognize and identify in a diagnostic laboratory because they are slowly growing microorganisms that require a prolonged period of incubation. Their relatively slow growth results in the cultures being discarded before the nocardiae can be visualized. Thus, isolation of *Nocardia asteroides* in a clinical microbiology laboratory is a kind of success and quality of the diagnostic procedure. Therefore, all microbiologic laboratories should consider the introduction of a prolonged incubation time following findings of gram-positive branched filamentous hyphae in direct microscopic smear in view of the possible isolation of *Nocardia* sp.

The pathologic feature of pulmonary nocardiosis is usually a suppurative response, however, a granulomatous response or a mixture of these resulting in radiographic presentations that are pleomorphic and not specific may occur. The manifestation within the lungs may vary from a mild, diffuse infiltration to a lobar or multilobar consolidation. There may be solitary masses, reticulonodular infiltrates, large irregular nodules, interstitial infiltrates, and pleural effusions. The lesions produced in the lungs may be necrotizing abscesses. Granulomas may occur¹¹⁻¹³.

There are no specific clinical signs diagnostic of pulmonary nocardiosis, whereas clinical presentation of the disease may run the full spectrum of either acute or chronic pulmonary infection. There may be pneumonia, abscess formation, or granulomatous response similar to tuberculosis⁶. An accurate diagnosis can be reached by isolation of the organism in pure culture from the affected area⁶.

In our case, the *Nocardia asteroides* related pulmonary infection was not confirmed by x-rays. However, our assumption that this microorganism had caused respiratory infection was supported by the following: 1) laboratory findings indicating the presence of acute infection after administration of corticosteroids; 2) isolation and identification of *Nocardia asteroides* in pure culture associated with a large number of leukocytes in direct microscopic slide preparation from tracheal aspirate; and 3) improved general condition of the patient after the introduction of sulfonamides.

In conclusion, clinicians should maintain a high degree of suspicion for this pathogen in severely immunocompromised patients, because *Nocardia* is far from rare in the group of immunocompromised patients. Close collaboration between clinicians and medical microbiologists is required for early diagnosis and therapy.

Acknowledgment

We thank Mr. Tomislav Beus for his valuable assistance in taking photographs.

References

1. McNEIL MM, BROWN JM. The medically important aerobic *Actinomycetes*: epidemiology and microbiology. Clin Microbiol Rev 1994;7:357-417.
2. BROWN JM, McNEIL MM, DESMOND EP. *Nocardia*, *Rhodococcus*, *Gordona*, *Actinmadura*, *Streptomyces*, and other *Actinomycetes* of medical importance. In: MURRAY PR, BARON EJ, PFALLER MA, TENOVER FC, YOLKEN RH, eds. Manual of clinical microbiology. 7th Ed. Washington, DC: American Society for Microbiology, 1999:370-92.
3. SCHOLAR EM, PRATT WB. Antimicrobial drugs. 2nd Ed. Oxford University Press, 2000:215.
4. DeANGELIS LM, JAHALOM J, THALER HT, *et al.* Combined modality therapy for primary CNS lymphoma. J Clin Oncol 1992;10:635-43.
5. LUTZ JM, COLEMAN MP. Trends in primary cerebral lymphoma. Br J Cancer 1994;70:716-8.
6. BEAMAN BL, BEAMAN L. *Nocardia* species: host – parasite relationships. Clin Microbiol Rev 1994;7:213-64.
7. PATEL R, PAYA CV. Infections in solid-organ transplant recipients. Clin Microbiol Rev 1997;10:86-124.
8. KOUPPARI G, ZAPHIROPOULOU A, SKANDAMI V, *et al.* Disseminated *Nocardia asteroides* complex infection in an immunocompromised child. Clin Microbiol Infect 2000;6:287-8.
9. ZWERSKI A, WITEBSKY FG, CONCILLE PS, *et al.* Fatal *Nocardia* pulmonary infection in a child with acquired immunodeficiency syndrome and lymphoid interstitial pneumonitis. Pediatr Infect Dis J 1997;16:1088-9.
10. MENENDEZ R, CORDERO PJ, SANTOS M, *et al.* Pulmonary infection with *Nocardia* species: a report of 10 cases and review. Eur Respir J 1997;10:1542-6.
11. FARINA C, BOIRON P, GOGLIO A, *et al.* Human nocardiosis in northern Italy from 1982 to 1992. Scand J Infect Dis 1995;27:23-7.
12. FEIN A, GROSSMAN R, OST D, FARBER B, CASSIERE H. Diagnosis and management of pneumonia and other respiratory infections. First Edition. Professional Communications, 1999:181-207.
13. KUZMAN I. Pneumonije. Zagreb: Medicinska naklada, 1999:377-82.

Sažetak

PLUĆNA INFEKCIJA IZAZVANA ORGANIZMOM *NOCARDIA ASTEROIDES*: PRIKAZ SLUČAJA

I. Jajić-Benčić, P. Gaćina, V. Katalimić-Janković i I. Benčić

Prikazana je 53-godišnja bolesnica s plućnom infekcijom uzrokovanom mikroorganizmom *Nocardia asteroides*. Uzet joj je trahealni aspirat i pretražen je mikrobiološki. U direktnom mikroskopskom preparatu iz aspirata traheje bojenom po Gramu vidljive su gram pozitivne razgranate filamentne hife uz puno leukocita. Na krvnom agaru nakon duže inkubacije porasla je čista kultura kolonija bijelog, kredastog izgleda. Preparat iz kulture bojen po Gramu pokazao je gram pozitivne razgranate filamente. Primjenom standardnih metoda mikroorganizam je identificiran kao *Nocardia asteroides*.

Ključne riječi: *Nocardia* infekcije – dijagnostika; *Pneumonija*, bakterijska – dijagnostika; *Pneumonija*, bakterijska – mikrobiologija